



## TFOS Lifestyle: Impact of nutrition on the ocular surface

Maria Markoulli<sup>a,\*</sup>, Sumayya Ahmad<sup>b</sup>, Jayashree Arcot<sup>c</sup>, Reiko Arita<sup>d</sup>,  
Jose Benitez-del-Castillo<sup>e</sup>, Barbara Caffery<sup>f</sup>, Laura E. Downie<sup>g</sup>, Katie Edwards<sup>h</sup>,  
Judith Flanagan<sup>a,i</sup>, Marc Labetoulle<sup>j,k</sup>, Stuti L. Misra<sup>l</sup>, Malgorzata Mrugacz<sup>m</sup>, Sumeer Singh<sup>g</sup>,  
John Sheppard<sup>n,o</sup>, Jelle Vehof<sup>p,q,r</sup>, Piera Versura<sup>s,t</sup>, Mark D.P. Willcox<sup>a</sup>, Jillian Ziemanski<sup>u</sup>,  
James S. Wolffsohn<sup>v</sup>

<sup>a</sup> School of Optometry and Vision Science, UNSW Sydney, NSW, Australia

<sup>b</sup> Icahn School of Medicine of Mt. Sinai, New York, NY, USA

<sup>c</sup> Food and Health, School of Chemical Engineering, UNSW Sydney, Australia

<sup>d</sup> Department of Ophthalmology, Itoh Clinic, Saitama, Japan

<sup>e</sup> Universidad Complutense, Hospital Clinico San Carlos, Clinica Rementeria, Madrid, Spain

<sup>f</sup> Toronto Eye Care, Toronto, Ontario, Canada

<sup>g</sup> Department of Optometry and Vision Sciences, The University of Melbourne, Parkville, Victoria, Australia

<sup>h</sup> School of Optometry and Vision Science, Queensland University of Technology, Brisbane, Australia

<sup>i</sup> Vision CRC, USA

<sup>j</sup> Ophthalmology Department, Hospital Bicêtre, APHP, Paris-Saclay University, Le Kremlin-Bicêtre, France

<sup>k</sup> IDMIT (CEA-Paris Saclay-Inserm U1184), Fontenay-aux-Roses, France

<sup>l</sup> Department of Ophthalmology, New Zealand National Eye Centre, The University of Auckland, Auckland, New Zealand

<sup>m</sup> Medical University of Białystok, Białystok, Poland

<sup>n</sup> Virginia Eye Consultants, Norfolk, VA, USA

<sup>o</sup> Eastern Virginia Medical School, Norfolk, VA, USA

<sup>p</sup> Departments of Ophthalmology and Epidemiology, University of Groningen, University Medical Center Groningen, Groningen, the Netherlands

<sup>q</sup> Section of Ophthalmology, School of Life Course Sciences, King's College London, London, UK

<sup>r</sup> Department of Ophthalmology, Vestfold Hospital Trust, Tønsberg, Norway

<sup>s</sup> Cornea and Ocular Surface Analysis – Translation Research Laboratory, Ophthalmology Unit, DIMEC Alma Mater Studiorum Università di Bologna, Italy

<sup>t</sup> IRCCS AOU di Bologna Policlinico di Sant'Orsola, Bologna, Italy

<sup>u</sup> School of Optometry, University of Alabama at Birmingham, Birmingham, AL, USA

<sup>v</sup> College of Health & Life Sciences, School of Optometry, Aston University, Birmingham, UK

## ARTICLE INFO

## Keywords:

Diabetes  
Diet  
Dry eye disease  
Food restriction  
Gut microbiome  
Keratitis  
Lifestyle  
Mediterranean diet  
Ocular surface  
Systematic review

## ABSTRACT

Nutrients, required by human bodies to perform life-sustaining functions, are obtained from the diet. They are broadly classified into macronutrients (carbohydrates, lipids, and proteins), micronutrients (vitamins and minerals) and water. All nutrients serve as a source of energy, provide structural support to the body and/or regulate the chemical processes of the body. Food and drinks also consist of non-nutrients that may be beneficial (e.g., antioxidants) or harmful (e.g., dyes or preservatives added to processed foods) to the body and the ocular surface. There is also a complex interplay between systemic disorders and an individual's nutritional status. Changes in the gut microbiome may lead to alterations at the ocular surface. Poor nutrition may exacerbate select systemic conditions. Similarly, certain systemic conditions may affect the uptake, processing and distribution of nutrients by the body. These disorders may lead to deficiencies in micro- and macro-nutrients that are important in maintaining ocular surface health. Medications used to treat these conditions may also cause ocular surface changes. The prevalence of nutrition-related chronic diseases is climbing worldwide. This report sought to review the evidence supporting the impact of nutrition on the ocular surface, either directly or as a consequence of the chronic diseases that result. To address a key question, a systematic review investigated the effects of intentional food restriction on ocular surface health; of the 25 included studies, most investigated Ramadan fasting (56%), followed by bariatric surgery (16%), anorexia nervosa (16%), but none were judged to be of high quality, with no randomized-controlled trials.

\* Corresponding author. School of Optometry & Vision Science, UNSW Sydney, Sydney UNSW, 2052, Australia.

E-mail address: [m.markoulli@unsw.edu.au](mailto:m.markoulli@unsw.edu.au) (M. Markoulli).

<https://doi.org/10.1016/j.jtos.2023.04.003>

Received 30 March 2023; Accepted 6 April 2023

Available online 25 April 2023

1542-0124/© 2023 Elsevier Inc. All rights reserved.

## 1. Introduction

Nutrition is a core part of our lifestyle. This report is part of the Tear Film & Ocular Surface Society (TFOS; [www.tearfilm.org](http://www.tearfilm.org)) Workshop, entitled ‘A Lifestyle Epidemic: Ocular Surface Disease,’ which was undertaken to establish the direct and indirect impacts that everyday lifestyle choices and challenges have on ocular surface health. Poor dietary habits are reported as the second-leading risk factor for deaths and disability-adjusted life-years globally, accounting for 10.3 million deaths and 229.1 million disability-adjusted life-years [1]. The number of people worldwide who are ‘over-nourished’ (those with imbalanced nutrition arising from excessive intake of nutrients) [2] or obese (about 2 billion) now exceeds those who are under-nourished (those not accessing a sufficient number of calories, around 460 million) [3]. However, the over-nourished (from purely an energy perspective) are often under-nourished (from a nutrient perspective) resulting in an epidemic of non-communicable disease characterized by chronic inflammation, impaired immunity, and gut microbiome dysbiosis [4]. Hence, malnutrition in Western countries promotes metabolic disorders and compromised immunity, whereas the under-nourishment in low-to middle-income countries leads to nutritional deficits and associated immunodeficiencies [4]. When a person either does not get enough, or gets too much, of a nutrient, and deficiency or excess is significant over time, the person exhibits signs of malnutrition [5]. With a deficiency of energy, the person may display the symptoms of undernutrition by becoming extremely thin, losing muscle tissue and becoming prone to infection and disease [5]. With an excess of nutritional consumption, the person may become obese and vulnerable to diseases associated with overnutrition, such as heart disease and diabetes [5].

As the prevalence of nutrition-related chronic diseases climbs, it is imperative that the effect of nutrition on the ocular surface, either directly or because of the chronic diseases that result, is understood. The ocular surface is defined as the cornea, limbus, conjunctiva, eyelids and eyelashes, lacrimal apparatus, and tear film, along with their associated glands and muscular, vascular, lymphatic and neural support. ‘Ocular Surface Disease’ includes established diseases affecting any of the listed structures, as well as etiologically related perturbations and responses associated with these diseases. While certain vitamin deficiencies, such as vitamin A and C, have an established link to ocular surface compromise [6,7], associations with other systemic nutritional deficiencies are less well established. As understanding increases about the inflammatory mechanisms involved in the etiology of ocular surface disease, questions arise about the impact of systemic inflammatory conditions, diet, and nutrition on the ocular surface. The debate around essential fatty acids and dry eye disease has demonstrated the intense interest of clinicians, researchers and patients in this topic [8,9].

The purpose of this report is to review the evidence supporting the impact of nutrition on the ocular surface. Relevant evidence is summarized in a narrative style review that, wherever possible, refers to outcomes from high-quality systematic review (Level I) evidence. In alignment with the other *TFOS Lifestyle Workshop* reports, the Evidence Quality Subcommittee provided a comprehensive database of appraised Level 1 evidence judged to be of potential relevance to the topic area, which was then factored into the writing of the narrative review [10]. In addition, the report includes a systematic review that evaluates the effect(s) of different forms of intentional food restriction on ocular surface health.

## 2. Key elements of nutrition

A food is defined as any substance, whether processed, semi-processed, or raw, that is intended for human consumption, and includes drinks, food additives, and dietary supplements [11]. Substances used only as drugs, tobacco products and cosmetics (such as lip-care products) that may be ingested are not included in the definition nor in this report. Nutrients, required by the human body to perform

life-sustaining functions, are obtained from food. They are broadly classified into three groups: macronutrients (carbohydrates, lipids, and proteins), micronutrients (vitamins and minerals), and water. Regardless of their class, all nutrients have at least one of three functions: to serve as a source of energy; to provide structural support to the body; to regulate the chemical processes of the body. Consumed food and drinks can also consist of non-nutrients that may be beneficial (e.g., antioxidants) or harmful (e.g., dyes or preservatives added to processed foods).

The sections that follow explore each nutrient class and discuss key variables that influence nutrition in the human body. The goal of these sections is not to provide a comprehensive review of general nutrition, but to define key terminology and provide a foundation to guide the reader through the subsequent sections that consider how nutrition can affect the ocular surface, a site seemingly far removed from the digestive tract.

### 2.1. Macronutrients

Macronutrients consist of carbohydrates, lipids (also called fats) and proteins and have two critical attributes in common. First, all macronutrient classes are required by the body in large quantities [12]. Second, all macronutrients are capable of serving as an energy source, which is typically measured in units of kilojoules per gram [12].

#### 2.1.1. Carbohydrates

Carbohydrates consist only of carbon, hydrogen and oxygen [13]. Their primary role is to provide energy, though they also support the functions of a variety of other organ systems [12]. Major dietary sources of carbohydrates are grains, dairy products, fruits and starchy vegetables.

Carbohydrates are further classified as being either simple or complex. Simple carbohydrates contain up to two monosaccharides and include sucrose and glucose (the primary sugar utilized by the human body) [12]. Complex carbohydrates, such as glycogen and starch, contain branched or unbranched chains of many simple carbohydrates [12]. During digestion, simple sugars (glucose primarily) are released to fuel cells in the body. The effect of consumed carbohydrates and sugars on the ocular surface is considered in Section 3.1.1.

Fiber is a unique, complex carbohydrate. It is non-digestible and therefore passes through the digestive tract unaltered by human cells of the gastrointestinal system, yet it is needed to help regulate blood sugar and the sensation of hunger [12]. The gut microbiome is capable of breaking down fiber into absorbable simple carbohydrates [12]. Section 3.9 further explores the impact of the gut microbiome on nutrition and its potential effects on the health of the ocular surface.

#### 2.1.2. Lipids

Lipids are composed of carbon, hydrogen and oxygen, and have a primary responsibility of providing (or storing) energy [12]. Lipids also have a role in cell membrane structure, organ protection and temperature regulation [12]. Unlike carbohydrates, lipids are insoluble in water, due mostly to the hydrocarbon tails of their component fatty acids, the basic subunit of a lipid molecule. Major dietary sources of lipids include meats, fish, dairy products, butter, oils and nuts.

Lipids can be classified into saturated or unsaturated varieties. Saturated lipids are those in which each carbon of the hydrocarbon tail is saturated with hydrogen (i.e., the hydrocarbon tails lack double bonds). Unsaturated lipids have one (monounsaturated) or more (polyunsaturated) double bonds in the hydrocarbon tails and are therefore not saturated with hydrogen. Two important lipid classes that have been the source of significant investigation with respect to their role in ocular surface health are omega-3 (*n*-3) and omega-6 (*n*-6) fatty acids. Both omega-3 and omega-6 fatty acids must be consumed in the diet, as the human body is incapable of synthesizing them *de novo*. Both share the same enzyme system, creating a competitive environment that is either primarily pro-inflammatory (in diets dominated by omega-6 fatty acids)

or anti-inflammatory (in diets dominated by omega-3 fatty acids). The effects of dietary omega-3 and omega-6 fatty acids on the ocular surface have been comprehensively reviewed elsewhere [9,14–20] and are further discussed in Sections 3.1.1.1 and 3.4.6.

### 2.1.3. Proteins

On an elemental level, proteins differ from the other two macromolecules because they contain nitrogen in addition to carbon, hydrogen and oxygen [12]. Proteins are composed of amino acid subunits. While proteins are capable of serving as an energy source, their primary function is to provide structural support to muscles, bones and skin, and to facilitate most of the chemical reactions that occur in the body by acting as enzymes [12]. Major dietary sources of proteins include meats, dairy products, seafood, and many types of plant-based foods (e.g., lentils, beans, peas and soy).

## 2.2. Micronutrients

In contrast to macronutrients, micronutrients are needed in much lower quantities and do not serve as energy sources. This group consists of vitamins and minerals, both of which often serve as co-factors or co-enzymes that are essential to execute many bodily functions. There are 13 essential vitamins that are subdivided into those that are soluble in water and those that are soluble in fat [5]. The water-soluble vitamins are thiamin (B<sub>1</sub>), riboflavin (B<sub>2</sub>), niacin (B<sub>3</sub>), pantothenic acid (B<sub>5</sub>), pyridoxine (B<sub>6</sub>), biotin (B<sub>7</sub>), folate (B<sub>9</sub>), cobalamin (B<sub>12</sub>) and ascorbic acid (C) [12]. The fat-soluble vitamins are A, D, E and K [12]. Minerals are solid inorganic substances that perform a wide variety of functions in the human body. There are 16 essential minerals that are subdivided into those needed in larger quantities (seven macrominerals) and smaller quantities (nine trace minerals). Macrominerals are sodium, chloride, potassium, calcium, phosphorus, magnesium and sulfur. Trace minerals are iron, zinc, iodine, selenium, copper, manganese, fluoride, chromium and molybdenum [12]. Other trace nutrients known to be essential in small amounts include nickel, silicon, vanadium and cobalt [21]. The effects of select vitamins and minerals, including their deficiencies and supplementation, on the ocular surface are further discussed in Sections 3.1.2, 3.4.5 and 3.4.9.

### 2.3. Hydration

Water is a critical component of the diet. There are four overarching functions attributed to water: to serve as a vehicle for transport, as a neutral medium for biochemical reactions, as a source of lubrication or shock absorption, and as a regulator of body temperature [12]. To support these functions, the Food and Nutrition Board of the Institute of Medicine recommends that adult males consume 3.0 L and adult females consume 2.2 L of water per day [22].

Water is continuously transported into and out of the organ systems of the body, creating specialized compartments with their own specific solute concentrations. Though water itself moves passively in the human body, the driving force for the water movement is actively regulated by creating chemical gradients across semi-permeable membranes. These gradients are provided by differences in concentrations of electrolytes, or charged ions dissolved in water. Most macrominerals are electrolytes; sodium and chloride, the components of table salt, are among the most important [12]. Salt intake, therefore, plays a major role in osmoregulation, defined as the tight control of fluid balance throughout the body. Considering that the tear film is mostly water, the hydration status of the body has been purported to influence tear and ocular surface physiology [23]. This topic is further discussed in Section 3.2.

### 2.4. Excipients, additives and non-nutritional components

Processed foods are those that have been subject to any amount of change from their natural state. Simply cooking a food, for example, is

one form of processing a food. Ultra-processed food, however, comprises a class of processed foods that includes the addition of artificial colors, flavors, sweeteners, emulsifiers, thickeners, preservatives or other chemicals [24].

A food excipient is any substance that has no bioactivity itself, but is added to promote the bioactivity of co-ingested active ingredients [25]. Non-nutritional chemicals present in food may include food additives or contaminants, the latter often originating from environmental pollution. Some of these chemicals may have toxicological properties. Food additives are added to improve freshness, flavor, texture or appearance. They may be synthetic or natural, deriving from plants, animals or minerals [26]. Contaminants in food can occur because of environmental pollution (e.g., via water, soil or air), or as a result of food production. Examples of contaminants are metals, dioxins and polychlorinated biphenyls [27]. Materials used in food packaging such as cans and bottles may contain chemical substances that can leach into food. Also, the use of pesticides and the production or manufacturing processes of food can lead to the presence of unwanted chemicals in food [27]. Some of these non-nutritional chemicals may have bioactivity in the human body and on the ocular surface, as discussed in Section 3.3.

### 2.5. Whole foods versus nutrient extracts

Food, in all its complexity, is a more fundamental unit than any individual nutrient [28]. Whole foods represent complexes of macronutrients, micronutrients, bioactive compounds and their concomitant interactions, and hence, identifying the effects of single dietary nutrients within or without the context of the overall diet is very challenging [29, 30]. Adding to this complexity, the human gut microbiome uses nutrients as metabolic precursors, altering nutritional content as different bacteria synthesize or access nutrients from the host diet [29].

The discovery that certain health conditions are caused by deficiency in a single nutrient and can be cured by providing the deficient nutrient in isolation were watershed for public health. Examples include scurvy and ascorbic acid, pellagra and niacin, beriberi and thiamine, rickets and vitamin D, and neural tube defects and folic acid [31]. Dietary supplements may be used with the intent of mitigating, treating or preventing disease [32], although the regulatory requirements for dietary supplements differ significantly from medicines, and many such applications may not be supported by high-quality clinical evidence, as discussed in Section 3.4 [30]. There can be further concerns in the provision of supplements including, but not limited to: identification of the authentic source of the raw materials, purity, presence of other active compounds, quality, lack of experimental evidence, false advertising, contamination and interactions between supplements and drugs [32]. Hence, in relation to chronic disease prevention, diets or diet remedies that focus on single nutrients can be seen as illustrations of the inadequacy of a primarily reductionist approach [33]. Extracted nutrients lacking the coordination inherent in whole foods, and clinical trials frequently failing to demonstrate efficacy of isolated nutrients [31], support the concept of food synergy as worthy of more research [34].

Supplements for which there is sufficient evidence to suggest positive contribution to micronutrition will be discussed in detail in Section 3.4.

### 2.6. Over-nutrition

Under-nutrition is ceding to over-nutrition and shifting disease burden from infection to non-communicable diseases in both developed and developing countries [35]. Dietary patterns are reflecting increased consumption of energy-dense “convenient”, ultra-processed, and “fast” (in the sense of quick rather than food restriction) foods [36].

Over-nutrition is a complex issue involving neuro-endocrine signaling, gut microbiome and dysregulation of lipid and glucose metabolism [37]. Chronic over-nutrition creates an environment of systemic inflammation that leads to “overstimulation-induced insensitivity,” a phenomenon commonly present in obesity and metabolic

disorders [38]. Obesity, which often results from over-nutrition, is defined by excessive body weight composed of an accumulation of energy reserves as fat deposits [39]. This chronic adiposity leads to impaired glucose, lipid and protein metabolism triggering chronic, systemic, low-grade inflammation that renders cells insensitive to hormonal regulation [36,38]. Metabolic syndrome is a cluster of interrelated metabolic abnormalities including insulin resistance, hyperglycemia and hyperlipidemia, discussed in Section 4.1.3 [40]. A hallmark of metabolic syndrome resulting from over-nutrition is the accumulation of adipose tissue, that is then infiltrated by immune cells, leading to low-grade chronic inflammation [40]. All of these are characterized as chronic diseases into which certain ocular surface diseases are increasingly being categorized.

## 2.7. Caloric restriction

Caloric restriction consists of the chronic reduction of total calorie intake without malnutrition [41], which can exert a potent anti-inflammatory effect that alters the cellular metabolism and gut microbiome to reduce oxidative damage and inflammation [42]. Additionally, caloric restriction causes increased presence of commensal bacteria that produce short chain fatty acids, leading to improved intestinal integrity [42]. Caloric restriction induces the decrease of anabolic hormones (such as insulin and growth hormone), inhibits the mitogen activated protein kinase pathway, suppresses inflammation by downregulation of interferon and pro-inflammatory cytokines, and reduces reactive oxygen species [42].

The lived experience of dietary restriction overlaps with cultural loci for centenarian eating patterns, such as in Okinawa in Japan [43]. Hence, regulation of chronic inflammation through a caloric-restricted diet offers an alternative to pharmacological and procedural interventions for chronic Western disorders. This is further discussed in Sections 3.8.2 and 6.

## 2.8. Factors influencing nutrition

### 2.8.1. Age

The aging adult body experiences dramatic changes in bone density, muscle tone, fat distribution, reproductive physiology and digestive physiology, among other changes. In young adulthood, defined as between the ages of 19 and 30 years, the body is usually relatively stable [12], except for women who experience pregnancy, childbirth, and lactation. Peak health and fitness are typically achieved at this age, particularly in the active adult with a well-balanced diet. Middle age, which extends from ages 31–50 years, is as dynamic as the former is stable [12]. Older adulthood extends from age 51 years until death and is marked by decreasing hormone levels, redistribution of fat, and thinner and less resilient skin in older adulthood [12]. Even in the absence of renal disease, kidney function declines, which can affect electrolyte composition and interfere with optimal hydration [12]. The gastrointestinal tract also becomes less efficient in absorbing essential vitamins and minerals, potentially predisposing to deficiencies [12].

### 2.8.2. Sex

Many government regulatory bodies, such as those of the UK [44], European Union [45], USA and Canada [46–49], have recommended dietary intake values for many macronutrients and micronutrients. Different values are typically recommended for males and females across their lifespan. Biological sex, however, is usually a confounding variable, as body weight is the primary differentiating factor between the varying recommendations for male and female adults [50].

### 2.8.3. Ethnicity

Diet and specific foods are often rooted in cultural norms [51]. Conversely, dietary acculturation, common to immigrants and indigenous populations, is the adoption of dietary practices of the dominant

culture within which varying degrees of maintenance of traditional practices yield diverse health outcomes [52–55]. For example, people with Hispanic ethnicity adopting the culture of the USA and reducing the influence of their traditional culture are reported to appropriate a diet of reduced quality relative to those who retain their traditional culture [56]. A systematic review of such practices [57] reported accumulating evidence suggesting people of Hispanic ethnicity born in the USA, speaking predominantly English, and/or assuming the dominant culture of the USA (as determined through acculturation scales), generally consumed fewer fruits and vegetables, but more salt, added sugar and calories from fat, and ate more away-from-home meals than those less assimilated [57].

The most commonly reported dietary change in immigrants to the USA is increased consumption of red meat and junk/fast foods (energy-dense foods high in fat and sugar and low in nutrients contributing to the daily energy at affordable cost [5]) and an associated increase in body mass index (BMI) [58].

### 2.8.4. Socioeconomic factors

It has been well documented that in affluent countries, poor health and diet quality are associated with low socioeconomic status, with similar findings increasingly reported in low- and middle-income countries. These findings suggest that socioeconomic factors have an independent deleterious effect on diet [59].

Adults in the USA with higher income are reported to have greater compliance to dietary guidelines [60]. The lower diet quality index measured in low-income communities could be ascribed to limited access to healthier food due to the cost and access to facilities to prepare, raising the specter of increased food insecurity in lower socioeconomic status groups [61].

Level of education can affect not only purchasing ability related to income, but also exposure to, and understanding of, dietary information. The National Health and Nutrition Examination Surveys conducted in the USA from 1971 to 2002 suggest that although total energy intake or amount of foods consumed appeared to differ little by education, intake of micronutrients, fruits and vegetables were reduced with lower level of education in all surveys [62]. Generally, increased consumption of fish, nuts and seeds along with reduced red and processed meat are seen in more highly-educated individuals and women, which has been suggested to be driven by both health and climate change concerns [63].

Poor dietary habits and an increased prevalence of non-communicable disease are also of concern for developing economies undergoing ‘nutrition transition,’ such as parts of Asia, Africa, the Middle East and Latin America [64]. This has also been shown in adolescent boys in China adopting the fast-food habits of those in lower socioeconomic groups in developed countries [65]. These findings suggest that there is a transitional adoption of lower socioeconomic nutrient patterns during periods of accelerated economic growth [64].

In 2018, more than 50% of adults in the USA reported consuming three or more meals out-of-home per week [64]. Australia also reported that more socioeconomically disadvantaged groups tended towards less healthy foods when away from home [64]. Fast food tends to be low in whole grains, fruit, vegetables, nuts and seeds, but high in sugar, sodium and processed meat, which, along with high intakes of alcohol, are leading factors in early death and disability [63]. Studies in Europe, the USA, Australia, New Zealand, and increasingly in Asia, find that lower socioeconomic status is associated with increased frequency of out-of-home meals, with those living in the poorest areas having a higher exposure to fast food outlets than those in less deprived areas [64]. Overall, the literature overwhelmingly suggests that those from lower socioeconomic groups are more susceptible to inequalities in diet with a concomitant increase in obesity and chronic disease [64].



### 3. Nutrition and the ocular surface

#### 3.1. Nutrition

In considering what constitutes a diet that is optimal for ocular surface health, this section of the report considers each element of nutrition and its known impact on the ocular surface.

It is important to be mindful that when discussing individual dietary elements, the whole (potential dietary interactions of the whole foods) is more influential than the sum of its individual parts. Investigating single nutritive substances in isolation can therefore be fraught with inconsistencies or misguided conclusions [66], as discussed in Section 2.5.

Where specific studies of macronutrients pertaining to ocular surface health have been reported, these are discussed within their context. However, for many of the food groups, their relationship to gut dysbiosis and chronic inflammation is the focus, with the attendant inflammation associated with ocular surface disease as discussed in Section 3.9.

##### 3.1.1. Macronutrients

**3.1.1.1. Polyunsaturated fatty acids.** As mentioned in Section 2.1, omega-3 polyunsaturated fatty acids include  $\alpha$ -linolenic acid, eicosapentaenoic acid and docosahexaenoic acid, while omega-6 polyunsaturated fatty acids include linoleic acid, dihomo- $\gamma$ -linolenic acid and arachidonic acid [67]. In relation to resolution of ocular surface inflammatory disorders, research using a mouse dry eye model demonstrated that resolvins and protectins (derivatives of omega-3 polyunsaturated fatty acids that help resolve acute inflammation [68]) inhibit leukocyte infiltration and enhance macrophage activity, leading to increased corneal epithelial integrity and increased tear production [69–71]. Docosahexaenoic acid-generated neuroprotectin D1 plays a role in controlling ocular surface inflammation, in addition to offering neuroprotection [72]. Corneal neurogenic health is essential for ocular surface health and neurotrophic keratitis can arise when corneal nerves are damaged. Spontaneous epithelial breakdown, impaired wound healing and corneal ulceration result when tear production and reflex blinking are impaired [72]. A study involving 26 individuals with diabetes and 21 healthy controls reported a positive relationship between the systemic Omega-3 Index and corneal nerve parameters [73], suggesting that omega-3 intake may impact corneal nerve health.

A cross-sectional study of 32,470 women health professionals aged 45–84 years, who participated in the Women's Health Study, [74] identified 1546 (4.7%) participants who reported a clinical diagnosis of dry eye disease. After adjusting for demographic factors, hormone therapy and total fat intake, the odds ratio (95% confidence interval [CI]) for the highest versus lowest fifth of omega-3 fatty acids was 0.83 (0.70–0.98),  $p = 0.05$  and a higher ratio of omega-6 to omega-3 fatty acid consumption was associated with significantly increased risk of dry eye disease, odds ratio (CI) = 2.51 (1.13–5.58) for >15 to 1 versus <4 to 1 ( $p = 0.01$ ). In addition, tuna consumption was inversely associated with dry eye disease (odds ratio = 0.81, CI = 0.66–0.99 for 2–4 113 g (4 oz) servings/week, and odds ratio = 0.32, CI = 0.13–0.79 for 5–6 servings/week versus  $\leq 1$  servings/week;  $p = 0.005$ ). Overall, a higher dietary intake of omega-3 fatty acids was associated with a decreased presence of dry eye disease in women.

Further indirect evidence that omega-3 intake may have ocular surface sequelae is provided by conflicting findings for the role of omega-3 fatty acids in the management of dry eye disease [75]. Omega-3 fatty acid supplementation is further discussed in Section 3.4.6.

##### 3.1.1.2. Vegetable oils and seeds

**3.1.1.2.1. Olive oil.** Direct evidence for extra virgin olive oil contributing to ocular surface health is lacking. Extra virgin olive oil has been chosen as the placebo for a number of studies investigating the

effects of oral omega-3 fatty acids on ocular surface health [76–82] and whether this could have been a confounding factor in these analyses is likely to be dose dependent and is discussed in Section 3.4.6.1.4.

**3.1.1.2.2. Flaxseed oil.** Flaxseed oil is composed of approximately 50%  $\alpha$ -linolenic acid (a short-chain omega-3 fatty acid). Studies of flaxseed ingestion for treating ocular surface disease are discussed further in Section 3.4.6.

**3.1.1.2.3. Primrose oil.** Primrose oil is a rich source of omega-6 fatty acids. A review of clinical trials of oral primrose oil suggested that overall there were possible improvements in ocular comfort and inflammation, but cited limitations in the study design that might have confounded the results [83].

**3.1.1.2.4. Palm oil, soybean oil, hydrogenated vegetable oils.** In contrast to olive oil and flaxseed oils, vegetable oils such as palm, corn, soybean, cottonseed, safflower, sunflower and hydrogenated vegetable oils are low in omega-3 and high in omega-6 fatty acids. Ingestion of these oils may contribute to a suboptimal omega-6 to omega-3 ratio in the overall diet, which can predispose the body to chronic inflammation [84]. In addition, consumption of *trans* fatty acids, produced by the partial hydrogenation of vegetable oils, is associated with greater levels of systemic inflammation in women [85]. Independent of other risk factors, higher intake of *trans* fat and lower intakes of polyunsaturated fat increase the risk of type 2 diabetes [86], and as type 2 diabetes can affect the ocular surface (Section 4.1.4) there may be a link between *trans* fats and ocular surface health.

**3.1.1.3. Sugars and artificial sweeteners.** The less refined a naturally occurring sugar source, the greater is its nutritive value [87]. For example, Turbinado sugar is the least refined sugar, which, along with blackstrap molasses (both from sugar cane), contains significant amounts of calcium, magnesium, potassium and iron. Agave nectar contains trace amounts of iron, calcium, potassium and magnesium, but also contains a significant concentration of fructose; levels of fructose in agave nectar are higher than high fructose corn syrup, which has been associated with inducing abdominal fat, high triglycerides, heart disease and insulin resistance [88]. There is no direct evidence of its impact on the ocular surface.

Artificial sweeteners are categorized into two groups: nutritive sweeteners (or low calorie), which add some energy value (calories) to food, or highly concentrated non-nutritive sweeteners that add no caloric value, since they are used in small quantities [87]. For the most part, artificial sweeteners are not utilized by the human body and hence were long considered a useful weight loss tool with minimal metabolic effects. Some epidemiological studies have shown that artificial sweeteners can aid in weight loss for those who experience glucose intolerance and type 2 diabetes [89]. However, an increasing number of studies now suggest that artificial sweeteners induce metabolic syndrome (see Section 2.6) and development of glucose intolerance and weight gains, which may be partly due to perturbation of the gut microbiome [90]. Such deleterious interventions can subsequently lead to an inflammatory response, dysbiosis and metabolic disorders [91], although there is no evidence of direct impact on the ocular surface.

**3.1.1.4. Gluten.** Gluten, a complex mixture of glutamine- and proline-rich proteins, is found in some cereals. Gluten-free diets are supported in the treatment of celiac disease, possibly also in allergies against wheat, in some chronic diseases including rheumatoid arthritis, and in inflammatory bowel disease [92]. The danger of gluten-free diets in healthy populations is that it excludes many complex carbohydrates, and may result in nutrient deficiencies of fiber and certain vitamins and minerals, with a potential trade-off in increased fats and sugars contained in processed gluten-free products. This has an associated increased inflammatory potential [92] with evidence of nutritional deficiencies of such diets leading to impaired bone health, and reproductive anomalies and increased risk of metabolic syndrome [93]. Although

ocular surface inflammation can develop in individuals with celiac disease, this appears to be due predominantly to mechanisms reported for other chronic or autoimmune disorders, and eliminating gluten from the diet might reduce ocular surface inflammation due to an overall reduction in exacerbation of the disease [94]. There is no direct evidence of the impact of gluten, or its absence, on the ocular surface.

### 3.1.2. Micronutrients

Deficiencies in iron, vitamin A and iodine are the most common deficiencies around the world, particularly in children and pregnant women [95]. At least half of the children worldwide, younger than 5 years of age, suffer from vitamin and mineral deficiencies [95]. Low- and middle-income countries bear a disproportionate burden of micronutrient deficiencies [95]. In the homeostasis of the ocular surface, micronutrients play an important role [95]. Their impact on the ocular surface is discussed in the next section, and the impact of their supplementation is discussed in section 3.4.

**3.1.2.1. Vitamins.** The major vitamins associated with ocular surface diseases are vitamin A, B<sub>12</sub>, C and D [96].

**3.1.2.1.1. Vitamin A.** Vitamin A is a group of nutritional organic compounds that includes retinol, retinal (from animal sources) and several provitamin A carotenoids (especially beta-carotene) that can be found in fruit and vegetables. It is essential for the maintenance of the immune system, growth and development, including metabolism and differentiation of the ocular surface epithelium [97]. Vitamin A has a complex mechanism of action, such as upregulating the cytochrome P450 synthesis of eicosanoids in *in vitro* human models of the conjunctiva and cornea [98]. Vitamin A also stimulates the synthesis of mucin 4 (MUC4) that is present on conjunctival epithelial cells [99]. Additionally, vitamin A has been shown to be involved in the down-regulation of androgen receptor expression on the ocular surface [100]. In a rat dry eye model, overexpression of keratinocyte transglutaminase was found to be associated with the abnormal keratinization of the cornea due to vitamin A-deficiency [101]. This is further reviewed in the *TFOS Lifestyle: Impact of elective medications and procedures on the ocular surface* report [102] and elsewhere [103].

Deficiency of vitamin A is the most frequent form of malnutrition that contributes to ocular disease in the developing world; it is also the major cause of childhood blindness in the world [104,105]. Vitamin A deficiency causes ocular surface changes such as decreased or absent goblet cells, xerophthalmia and corneal punctate keratopathy [106, 107]. Long-term vitamin A deficiency causes epithelial metaplasia and keratinization, leading to xerophthalmia, Bitot's dots, keratomalacia and corneal perforation [108].

**3.1.2.1.2. Vitamin B<sub>12</sub>.** Vitamin B<sub>12</sub>, also known as cobalamin, is a cofactor in DNA synthesis, in fatty acid metabolism and amino acid metabolism. Vitamin B<sub>12</sub> can be found in foods such as meat, fish and dairy products. It is the only vitamin that contains a metal ion, cobalt. Vitamin B<sub>12</sub> is indispensable for erythrocyte and leukocyte production. Together with folic acid, this vitamin contributes to the synthesis of DNA, amino acids and bone marrow proteins. It is also necessary for the normal functioning of the alimentary tract and nervous system. Vitamin B<sub>12</sub> plays an essential role in the synthesis of myelin, and its deficiency is connected with myelopathy, peripheral neuropathy and optic atrophy [109]. In the USA, it has been demonstrated that the prevalence of vitamin B<sub>12</sub> deficiency varies by age range, affecting at least 3% of those aged 20–39 years old, 4% of those aged 40–59 years and 6% of those 60 years or over [110]. In a population-based cohort study, vitamin B<sub>12</sub> deficiency was found to be associated with a 1.6 times increased risk of having dry eye disease ( $p = 0.002$ ) [111].

**3.1.2.1.3. Vitamin C.** Vitamin C, also known as L-ascorbic acid, is necessary for the biosynthesis of collagen, L-carnitine and protein metabolism [112]. It is an important physiological antioxidant and regenerates other antioxidants, including vitamin E [112]. Vitamin C also

plays a crucial role in immunological processes and improves the absorption of iron [113]. This vitamin cannot be synthesized endogenously by humans and its best sources are fruits and vegetables [114].

Vitamin C can be found in tears, and possibly is involved in antioxidant defense [115]. Moreover, vitamin C has a role in corneal healing after injury [116].

**3.1.2.1.4. Vitamin D.** Vitamin D plays a crucial role in several biological functions, including calcium homeostasis, immune regulation, cellular proliferation, differentiation and apoptosis, and angiogenesis. Vitamin D is obtained from dietary consumption and is produced in the skin after direct sunlight exposure [117]. Its level in human tears is higher than in serum [118]. In the human cornea, this vitamin undergoes active metabolism due to the presence of 1-alpha-hydroxylase, the key enzyme that activates vitamin D<sub>3</sub> to calcitriol, its active metabolite [119].

Vitamin D deficiency has been related to the pathogenesis of dry eye disease [120], in particular conjunctival squamous metaplasia and a loss of conjunctival goblet cells [121]. Additionally, vitamin D has been implicated in the modulation of systemic calcium absorption that promotes fluid secretion in the salivary and lacrimal glands [122]. A significant correlation has been found between serum vitamin D levels and tear production, stability and ocular dryness symptoms [123]. Systematic review and meta-analysis studies have reported that vitamin D deficiency is associated with the exacerbation and onset of ocular dryness symptoms [124–126].

**3.1.2.2. Minerals.** Selenium is an essential micronutrient that shows a synergistic action with vitamin E as an antioxidant [5]. It protects cells, cellular membranes, mitochondrial membranes and DNA against the harmful effects of free oxygen radicals. The main dietary sources of selenium are Brazil nuts, meat, fish, seafood and cereals. The biological effects of selenium are largely mediated by selenium-containing proteins (selenoproteins) [127]. Within the group of selenoproteins, selenoprotein P is generated by the lacrimal gland and secreted in tears, providing selenium to the corneal epithelium [128]. In dry eye disease, the level of selenoprotein P in tears has been found to be decreased, with selenium deficiency thought to result in oxidative damage to the ocular surface [128].

Lactoferrin occurs naturally as an iron-binding glycoprotein. It is produced and secreted by mucosal epithelial cells and neutrophils in mammalian species, including humans. It is typically present in fluids such as milk, saliva and tears. As lactoferrin shows anti-inflammatory, antioxidant and antimicrobial effects, its topical application may help maintain a healthy ocular surface system. One study reported a relationship between low levels of tear lactoferrin, and the development of dry eye disease and chronic meibomitis [129].

Lower serum levels of zinc, copper, and selenium were found in 50 patients with advanced keratoconus compared to 50 healthy controls, suggesting a possible role of antioxidant activity of these trace elements in the etiology of advanced keratoconus and a possible role as a treatment option [130]. Previous studies have suggested enzymatic roles of these elements in connective tissue metabolism leading to oxidative stress in tissues, abnormal collagen synthesis and impaired breakdown of collagen [130]. No trials have yet been performed to consider an effect of mineral supplementation in reducing the progression of keratoconus.

## 3.2. Hydration

Sufficient hydration is essential for the optimal functioning of the human body including physical and cognitive performance [131–133]. Increasing water intake has been associated with health benefits, such as increased skin hydration [134] and reduced exercise-related asthma and urolithiasis [135]. However, to-date there have been few studies that have assessed the role of hydration status or water intake on ocular

surface health, including in individuals with dry eye disease.

Two studies reported a link between plasma osmolality, a marker of general hydration, and tear osmolarity [136,137]. The first, a hospital-based cross-sectional study ( $n = 111$ ), found that patients with dry eye (defined by tear osmolarity, tear breakup time and dry eye symptoms) had a higher plasma osmolality than a non-dry eye control group [136]. The second, a smaller study ( $n = 14$ ), found plasma osmolality and tear osmolarity to be strongly correlated ( $r = 0.93$ ) in healthy volunteers who exercised in heat with fluid restriction [137]. The authors speculated that dehydration may increase tear osmolarity through decreased lacrimal gland function [137]. No clinical trials have specifically investigated the effect of water intake on ocular surface parameters. A randomized clinical trial that considered the effect of oral caffeine consumption on tear production found no change in Schirmer score results relative to the control group who drank 200 mL of water only (tested between 45 and 180 min after consumption) [138]. A population-based study including 51,551 participants in the Netherlands investigated the association between both water intake (from all dietary sources assessed by food frequency questionnaires) and 24 h urine volume as markers of systemic hydration and dry eye as an outcome variable [139]. Neither water intake nor urine volume was associated with a protective risk of dry eye (either a clinical diagnosis or dry eye symptoms). Results did not change after accounting for more than 70 comorbidities and medications [139].

Drinking more water for dry eye has been used as an adjunct management strategy for patients and may also be recommended by some clinicians [137,140]. However, based on the current limited studies, increased water intake has not been directly tied to improved dry eye or ocular surface outcomes. Future longitudinal studies should investigate whether increasing water intake is beneficial in patients with dry eye disease.

### 3.3. Excipients, additives and non-nutritional components

#### 3.3.1. Endocrine-disrupting chemicals

As discussed in the *TFOS Lifestyle: Impact of environmental conditions on the ocular surface* report [141], endocrine-disrupting chemicals, also referred to as endocrine disruptors, are compounds that can bind to the hormone receptors of cells to activate or block the action or interfere with the synthesis, secretion or transport of hormones [142,143]. Endocrine-disrupting chemicals can affect various hormones, including sex hormones, which are particularly important in ocular surface health [144]. The main source of endocrine-disrupting chemical exposure for humans is by ingestion, e.g., via pesticides that end up in the food chain, and leaching from food containers or contamination during the manufacturing or processing of foods. Examples of endocrine-disrupting chemicals that are commonly found in products are bisphenols A, S and F, alkylphenols, dichlorodiphenyltrichloroethane, phthalates and parabens [145].

A systematic review on the effects of endocrine-disrupting chemicals on the human microbiome concluded that there is growing evidence that these chemicals change the diversity of resident microbiota, including the gut microbiome [146]. A study looking at exposure to the organophosphate azinphos-methyl, an insecticide, in farmworkers found significant alterations of the oral buccal microbiota with less bacterial diversity after exposure [147]. Studies on the effect of the many endocrine-disrupting chemicals in ocular surface disease are lacking. The following section reviews the known ocular surface impacts of bisphenol-A and phthalates.

**3.3.1.1. Bisphenol-A.** Bisphenol A is a chemical compound used in the production of plastics, including food and drink containers. It is one of the most studied endocrine-disrupting chemicals in the context of health. It has the ability to bind to estrogen receptors, but has been estimated to have only a 1/1000th to 1/10,000<sup>th</sup> of the binding affinity

of natural estradiol [148]. In an *in vitro* study looking at monocyte-derived dendritic cells of patients with primary Sjögren syndrome, exposure to bisphenol A increased expression of estrogen receptor- $\alpha$  and altered the function of these cells, including inducing a higher expression of interferon  $\gamma$  and interleukin-17 mRNA in T-cells. The authors suggested that bisphenol A exposure could accelerate the development and deterioration in function of primary Sjögren syndrome [149].

In a small case-control study ( $n = 33$  dry eye,  $n = 21$  controls), significant positive correlations were found between dry eye disease signs and several endocrine-disrupting chemicals in the urine, including methylparaben, ethylparaben, methyl-protocatechuic acid and triclocarban [150]. However, no association with bisphenol A or S was found. Also, no clear difference arising from the consumption of liquids from plastic bottles or canned food was found between dry eye patients and controls, which may indicate that either these compounds are widely distributed or that the limited sample size hampered any strong conclusions being drawn [150].

**3.3.1.2. Phthalates.** Phthalates are esters of phthalic acid. They are often used to increase the flexibility and durability of polymer plastic matrices and are found in cosmetics (see the *TFOS Lifestyle: Impact of cosmetics on the ocular surface* report [151]), children's items, plastics and food storage materials. Humans are exposed via foods that have contacted products containing phthalates or via air-borne contamination. No studies on dietary phthalate intake and ocular surface disease have been conducted to date, but exposure to air-borne phthalates has been associated with mucous membrane irritation, including ocular symptoms [26].

#### 3.3.2. Mercury

Mercury is a heavy metal that, even in small amounts, can be extremely toxic to humans. Teratogenicity and neurotoxicity, including to the retina and optic nerve, are important adverse effects, but also immunotoxic effects have been shown [27]. The most common route of mercury poisoning is consumption of mercury-contaminated seafood [145].

In a cross-sectional study of 22 male metal manufacturing plant workers who had systemic mercury intoxication, ocular surface symptoms were frequent [152]. Specifically, increased tear osmolarity, altered tear cytokine tear levels, altered corneal sensitivity and disrupted subbasal corneal nerve morphology were found [152]. In two independent Korean population-based studies, blood concentrations of mercury were linked to dry eye symptoms [153,154]. In a sample of 4761 adults, those with dry eye symptoms more often had blood mercury levels exceeding the median levels than those without dry eye symptoms (51.7% versus 45.7%,  $p = 0.02$ ) [153]. In 23,376 participants, mercury blood concentrations were significantly associated with the presence of persistent dry eye symptoms (odds ratio: 1.39 (CI: 1.02–1.89) for persons in the third versus the first tertile of blood mercury concentration [154]. Although the source of intoxication was not defined, the authors stated that the main source of mercury was likely to be fish or shellfish consumption [154]. In data analyzed from 6587 adults, environmental exposure to lead and mercury was found to be related to the development of pterygium (odds ratio 2.22 (CI: 1.30, 3.78) and 1.64 (CI: 1.04, 2.59), respectively [155]). Several pathophysiological hypotheses have been proposed by the authors of these studies: first, neurotoxicity of the autonomic nervous system, leading to decreased lacrimal gland function; second, accumulation of mercury in the conjunctiva and acceleration of free radical reactions leading to inflammation of the ocular surface epithelium; and third, increased plasma osmolarity leading to increased tear hyperosmolarity [153,154].

#### 3.3.3. Alcohol

Two small interventional studies have investigated the effect of a

single event of alcohol intake on several ocular surface parameters, and found increased tear osmolarity, shortened tear breakup time and more ocular pain in the hours after alcohol consumption (0.75 g/kg ethanol or 200 mL 25% vodka) [156,157]. Alcohol was detectable in the tear film 2 h after intake, but not after 8 h [156]. A meta-analysis that included 10 studies (9 case-control and 1 cross-sectional) found that alcohol consumption was weakly associated with dry eye disease. No clear increased risk of dry eye was seen in heavy drinkers and the authors attributed this to a possible protective effect of neuropathy on symptoms associated with heavy drinking [158]. There was large heterogeneity between studies including the assessment of alcohol intake and dry eye, and none of them was primarily designed to assess the effect of alcohol use.

A large population-based study in the Netherlands ( $n = 77,145$ ) found alcohol use in females to be associated with an increased risk of eye dryness symptoms compared to no alcohol use, but increasing alcohol use was protective in males. The authors emphasized the possible sex-specific effects of alcohol on the ocular surface, with a complex underlying interplay between hormonal changes, corneal neuropathy and sensitivity, central nervous system changes, inflammation on the ocular surface and dry eye parameters [159].

Alcohol use has not been linked to allergic eye disease in studies to date, but there is evidence that its consumption can trigger allergy and promote hypersensitivity to different allergens [160]. Alcohol use has also been shown to impact the efficacy and safety of oral H1-antihistamine use [161]. Further longitudinal studies are needed to elucidate the short- and long-term effects of alcohol use at the ocular surface. The effects of alcohol on the ocular surface are discussed in greater detail in the *TFOS Lifestyle: Impact of lifestyle challenges on the ocular surface* report [162].

### 3.3.4. Food additives and non-nutritional chemicals

There has not yet been any published research related to the possible effects of food additives and non-nutritional chemicals, such as nanoparticles, emulsifiers and flavor enhancers including glutaminase and monosodium glutamate, on the ocular surface. These compounds have been increasingly associated with various negative health effects in the human body [163–165]. Future studies should examine whether they have a role in ocular surface disease.

## 3.4. Dietary supplements

The previous section highlighted the evidence regarding the impact of individual nutritional elements within the diet on the ocular surface. This is notoriously difficult to study, except in cases of clear dietary deficiency or excess. The following section therefore focuses on dietary supplementation.

Dietary supplements are products taken orally that contain an ingredient that intends to supplement the diet. They may contain vitamins, minerals, fiber, amino acids, essential fatty acids, herbs, botanicals, enzymes or other substances. Common forms are tablets, capsules, powders, liquids and bars [152]. Being a portmanteau (combination of the words) from “nutrition” and “pharmaceuticals,” “nutraceuticals” are a sector of dietary supplements with products derived from food sources that intend to provide health benefits in addition to their normal nutritional values. The definitions and regulatory control of dietary supplements and nutraceuticals differ between countries.

### 3.4.1. Caffeine

In an examiner-masked placebo-controlled study with 41 healthy volunteers, ingestion of caffeine (5 mg/kg body weight dissolved in 200 mL water), increased Schirmer scores significantly from baseline and compared to placebo (200 mL water only). This effect was seen in the first 90 min after ingestion and disappeared thereafter [138]. In another double-masked placebo-controlled study involving 78 healthy volunteers who abstained from caffeine use for at least 6 days, pure caffeine

capsules (5–7 mg/kg body weight) increased tear meniscus height by an average of 0.08 mm after 60 min compared to placebo [166]. There were also associations between certain genetic polymorphisms in the adenosine A2a receptor and cytochrome P450 1A2 genes and the increase in tear meniscus height. No trials have been performed in patients with dry eye disease, nor have there been long-term studies, which are needed to determine if caffeine intake is a possible dry eye management option.

In a large population-based study involving 85,302 participants, caffeine use (calculated from the consumption of coffee, tea, cola and energy drinks) was associated with a protective effect on dry eye (odds ratio: 0.971 (CI 0.96–0.99) per 100 mg/day), but this protective effect was not seen after correction for dry eye-associated comorbidities [167]. Similarly, in a Korean population-based study of 9752 adults, prevalence of dry eye decreased with increasing coffee consumption, but the apparent protective effect did not remain after correction for age and sex [168]. In a smaller study in New Zealand community residents ( $n = 322$ ) increased caffeine consumption was a borderline significant protective factor for dry eye [as defined by the Tear Film and Ocular Surface Dry Eye Workshop II (TFOS DEWS II) criteria, odds ratio 0.82 (CI: 0.68–0.99) per serving per day] in a multivariate model investigating multiple modifiable lifestyle factors [169]. Other smaller population-based studies in the past have shown no clear association with prevalence and incidence of dry eye [169–174], with the exception of one prevalence study where a significant protective effect was found for caffeine users [175]. Therefore, based on the current evidence, caffeine (which does not cause fluid loss in excess of the volume ingested despite its mild diuretic effect) does not appear to be a risk factor of dry eye disease and may have beneficial effects on tear production and symptoms, but further research is needed to verify the findings.

A small trial in low caffeine consumers showed that caffeine intake (capsule of 4 mg/kg body weight) reduced corneal deformability and increased intraocular pressure values, implying that exogenous factors are also important to consider in the diagnosis and management of disorders characterized by changes in the biomechanical properties of the cornea [176]. The effects of caffeine on the ocular surface, including mechanisms of action, are further discussed in the *TFOS Lifestyle: Impact of lifestyle challenges on the ocular surface* report [162].

### 3.4.2. Collagen

Collagen is the most abundant structural protein in various connective tissues, including the skin, bone, sclera, and cornea. It is the target in riboflavin-mediated cross-linking to retard the progression of keratoconus. Collagen-based dietary supplements, which are extracted from animal sources, are used mainly in the field of dermatology with some evidence for improved wound healing and increased skin health such as wrinkle reduction and skin hydration [177–179]. In addition, they may help recovery after joint injury and reduce symptoms in osteoarthritis [180,181]. So far, no studies have been performed to investigate the effect of dietary collagen supplementation or its amino acids glycine and proline and precursor ornithine on ocular surface health or wound healing.

### 3.4.3. Herbs

The term ‘herb’ usually refers to leaves and stems of soft-stemmed plants that grow in temperate climates [182]. *Tripterygium* glycosides extracted from *Tripterygium wilfordii* Hook F have been reported to have a therapeutic effect on Graves’ ophthalmopathy [183]. There is no systematic review or meta-analysis of herbs for eye symptoms caused by thyroid dysfunction, but there is one ongoing randomized controlled trial in which pingmu decoction, a Chinese balm containing multiple herbs, is being examined for Graves’ ophthalmopathy [184]. Oral ingestion of multiple Chinese herbs have been reported to be effective against dry eye disease development in clinical studies including randomized controlled trials [185–187]. In a randomized, double-masked, controlled trial, 80 individuals with dry eye disease were randomised to either topical eye drops as well as the Chinese herb,



Chi-Ju-Di-Huang-Wan, or the topical eye drop with a placebo. Rose bengal staining improved in the group randomized to the topical eye drop and the Chinese herb within two weeks, and TBUT improved within four weeks. and tear breakup time improved by four weeks [185]. In a randomized, unmasked, controlled trial of 60 individuals with both diabetes and dry eye disease, between the control (Western medicine treatment: artificial tears without preservatives used six times a day) or experimental treatment (combined treatment of traditional Chinese medicine of Qiwei Baizhu powder, Zhibai Dihuang, and Liuwei Dihuang, and Western medicine) the experimental group showed an improved tear breakup time, a reduction in corneal staining and reduced inflammatory mediators in the tear film, including interleukin-1, -8 and tumor necrosis factor- $\alpha$  [186]. In a double-masked, randomized controlled trial 50 individuals with diabetes, were randomized to either traditional Chinese herbal medicine goshajinkigan orally, 7.5 g/day for 3 months, or a placebo of 6.0 g/day for 3 months; a third group of 25 individuals without diabetes received the goshajinkigan orally, 7.5 g/day for 3 months [187]. The group with diabetes that was treated with goshajinkigan showed an improvement in corneal sensitivity, Schirmer score and corneal staining, while the other two groups did not change [187]. In conclusion, whilst there is some evidence for effects of certain herbal combinations on the ocular surface, further research using appropriate clinical study designs and other herbal combinations are needed to draw clearer conclusions about the potential benefits of individual herbs or herbal mixtures.

#### 3.4.4. Honey

There is evidence that honey can have antibacterial, antifungal, antiviral, anti-inflammatory and anti-oxidative properties, and may aid in the healing of wounds [188]. Several randomized clinical trials have investigated the effect of topically applied Manuka honey (*Leptospermum* spp.) in and around the eye, providing evidence of improvements in tear film evaporation, meibomian gland dysfunction (MGD), blepharitis, eyelid wound healing, corneal ulcers and vernal conjunctivitis [189–197].

The effect of honey as a dietary supplement on ocular surface disease has been less well studied. One double-masked randomized controlled trial investigated the effect of oral royal jelly, a gelatinous substance produced by bees, (6 × 1200 mg tablet daily) for 8 weeks versus placebo in 41 patients with dry eye disease. Tear breakup time and Schirmer scores improved significantly in the royal jelly group, with Schirmer scores significantly better compared to placebo only in patients with a baseline score below 10 mm. No clear improvements were found for dry eye symptoms [198]. A randomized controlled trial investigating the effect of three types of dietary honey on allergic rhinoconjunctivitis, in addition to standard care, found that none of the honey groups had improved symptoms compared to placebo [199]. A randomized controlled pilot study found that addition of dietary birch-pollen honey to the diet significantly reduced allergic symptoms compared to controls (conventional medications only), including conjunctival symptoms [200]. Further studies should clarify if there is a role for oral honey in the management of ocular surface disease.

#### 3.4.5. Minerals

With regard to dry eye disease, several clinical trials have investigated supplementation with a combination of minerals, vitamins, antioxidants and/or omega-3 fatty acids [201–204], but none has examined the role of minerals alone. Oral lactoferrin supplementation for one month in 10 patients with dry eye disease secondary to Sjögren syndrome was reported to improve dry eye symptoms [205]. Selenium-binding lactoferrin has been found to be incorporated into the epithelial cells of the cornea, thereby decreasing oxidative injury in an animal model of dry eye disease [206].

There is evidence of an increased prevalence of autoimmune thyroid disease and Graves' ophthalmopathy in persons with low dietary selenium intake (below 70  $\mu\text{g/L}$ ) [207,208]. A meta-analysis of two trials (n = 197) evaluating the efficacy of selenium supplementation (200

$\mu\text{g/day}$ ) for 6–9 months in patients with non-severe Graves' ophthalmopathy having standard therapy found no statistically significant difference in thyroid stimulating hormone receptor antibodies or thyroid peroxidase antibody titers compared to placebo [209]. Similarly, another review concluded that, although commonly prescribed [210], the evidence does not yet support a role for selenium supplementation in standard care of auto-immune thyroiditis, with a possible exception for persons with a known selenium deficiency [208].

#### 3.4.6. Omega-3 and -6

The omega-3 and omega-6 polyunsaturated fatty acids are the most extensively studied dietary supplements in ocular surface disease, with numerous randomized controlled trials, systematic reviews and meta-analyses, mostly in patients with dry eye disease or MGD.

##### 3.4.6.1. Dry eye and MGD

**3.4.6.1.1. Overview of randomized controlled trials.** Table 1 (omega-3 only) and Table 2 (omega-3 and -6 combined) summarize the randomized controlled trials that have investigated the role of omega-3 fatty acid supplementation on dry eye disease or MGD. Differing daily doses, subtypes (omega-3: eicosapentaenoic acid, docosahexaenoic acid, docosapentaenoic acid; omega-6:  $\gamma$ -linolenic acid, linoleic acid; and a form of omega-3: triglyceride, phospholipid, ethyl-ester, or re-esterified) and sources (flaxseed oil, krill oil, fish oil, sea buckthorn oil, borage oil, black currant seed oil) of omega fatty acids have been investigated across studies. Also, study duration (30 days to one year), sub-type of dry eye, comparators (olive oil, corn oil, sunflower oil, wheatgerm oil, safflower oil, middle chain triglycerides, none) and exclusion of other eye treatments have differed between studies. Only one study compared three interventions (fish oil vs krill oil vs placebo) [77].

**3.4.6.1.2. Conclusions of published systematic reviews and meta-analyses.** Meta-analyses in dry eye disease have been published on this topic since 2014 [9,15–18]. One of the three most recent meta-analyses was a Cochrane systematic review on the role of omega-3 and omega-6 fatty acids for dry eye disease [9]. It included a total of 34 randomized controlled trials with 4314 adult participants from 13 countries with several subtypes and severities of dry eye, and with follow-up ranging from 1 to 12 months [9]. Several comparisons were made, and the main conclusions were as follows:

- (1) Low certainty evidence was found for a reduction in ocular dryness symptoms for oral long-chain omega-3 fatty acids versus placebo. Moderate certainty evidence was found for a probable benefit in increasing aqueous tear production relative to placebo, but this increase was judged to be not clinically meaningful.
- (2) Moderate certainty evidence was found for no effect of oral combined omega-3 and omega-6 fatty acids versus placebo for Schirmer score, and moderate certainty was found for a probable improvement in tear breakup time. Effects on dry eye symptoms, ocular surface staining and tear osmolarity were unclear because of insufficient data or extensive heterogeneity precluding meta-analysis.
- (3) Low certainty evidence was found for reduction of symptoms with oral omega-3 fatty acids plus conventional therapy versus conventional therapy alone. Data for other dry eye outcomes could not be combined.
- (4) Moderate certainty evidence was found for a probable improvement in dryness symptoms for oral long-chain omega-3 versus omega-6 fatty acids. Low certainty evidence was found for a potential improvement in tear osmolarity. Effects on other dry eye outcomes could not be meta-analyzed.

In addition, for oral flaxseed oil (short chain omega-3) versus placebo (two randomized controlled trials), and omega-6 versus placebo

**Table 1**  
Overview of randomized clinical trials of oral omega-3 fatty acid supplementation for dry eye.

Study (author, year)	Type of dry eye	Intervention (daily dose)	Comparator (daily dose when applicable)	Duration	Parameters with significant improvement to comparator (including effect size if available)	Parameters without significant improvement to comparator (including effect size if available)
DREAM study group, 2018 [8]	DED (both symptoms and signs)	2000 mg EPA + 1000 mg DHA (n = 349)	5000 mg refined olive oil (n = 186)	12 months	None	- OSDI score (−13.9 vs −12.5) - Conjunctival staining score (−0.4 vs −0.4) - Corneal staining score (−0.6 vs −0.7) - TBUT (+0.7 vs + 0.6) - Schirmer score (+0.4 vs + 0.3)
Park et al., 2021 [211]	Dry eye symptoms one month after cataract surgery	1680 mg EPA + 506 mg DHA (re-esterified) + artificial tears 4x/day (n = 32)	Artificial tears 4x/day only (n = 34)	8 weeks	- Oxford staining score (−0.63 vs −0.14) - OSDI score (−6.22 vs + 1.58) - DEQ score (−3.78 vs −0.36) - MMP-9 level decrease (9/32 vs 4/34)	- TBUT (+0.41 vs −0.09) - Schirmer score (+2.54 vs + 0.57)
Jo et al., 2021 [212]	Mild to moderate DED and MGD (signs and symptoms)	600 mg EPA + 1640 mg DHA (n = 24)	3000 mg olive oil (n = 26)	8 weeks	- TBUT (+1.87 vs + 1.33) - MGD score (−1.5 vs −0.5)	- Corneal staining score (−2.6 vs −1.6) - OSDI score (−2.5 vs −2.0) - SM tube test (−0.3 vs + 0.3)
Macasai, 2008 [213]	Moderate to severe chronic blepharitis and obstructive MGD	Flaxseed oil capsules 6000 mg (n = 17)	Olive oil capsules (n = 20)	1 year	- Telangiectasia (−1.1 vs −0.3)	- OSDI score (−11.6 vs −7.1) - TBUT (+4.7 vs + 3.9) - Schirmer score (+1.8 vs + 2.2) - Fluorescein staining (+0.8 vs −0.9) - Rose bengal staining (−1.1 vs −1.4) - Collarettes (−0.7 vs −0.6) - Scurf (0.0 vs −0.1) - Dystichiasis - Madarosis
Bhargava et al., 2013 [214]	Both DED and MGD (symptoms and signs)	650 mg EPA + 350 mg DHA (n = 264)	Corn oil (n = 254)	3 months	- Symptom score value (−2.02 vs −0.48) - Schirmer score (+0.62 vs + 0.14) - TBUT (+2.54 vs + 0.13)	- Rose bengal scores (not directly compared) - Conjunctival impression cytology (not directly compared)
Bhargava et al., 2015 [80]	Computer users (>3 h/day) with dry eye symptoms	360 mg EPA + 240 mg DHA (n = 220)	Olive oil (n = 236)	3 months	- Symptom score (−4.1 vs −0.7) - Schirmer score (+1.2 vs + 0.6) - TBUT (+3.3 vs + 1.4) - Nelson grade (−0.7 vs −0.1)	None
Bhargava et al., 2016 [215]	Visual display terminal users with dry eye symptoms	720 mg EPA + 480 mg DHA (n = 256)	Olive oil (n = 266)	45 days	- Symptom score	- TBUT - Nelson grade - Schirmer score
Bhargava et al., 2015 [76]	Female contact lens users with dry eye symptoms and lens wear discomfort	720 mg EPA + 480 mg DHA (n = 240)	Corn oil (n = 256)	6 months	- Symptom score (−4.7 vs −0.5)	- TBUT (+3.3 vs + 0.3) - Nelson grade (−0.7 vs −0.1) - Schirmer score (+2.1 vs + 0.2)
Bhargava et al., 2016 [216]	Rosacea patients with dry eye symptoms	360 mg EPA + 240 mg DHA (n = 65)	Olive oil (n = 65)	6 months		- Symptom score (−5.3 vs −0.2) - Meibomian gland score (−1.3 vs 0.0) - TBUT (+3.1 vs −0.2) - Schirmer score (+1.4 vs −0.3)
Malhotra et al., 2015 [217]	Moderate MGD (symptoms and signs)	720 mg EPA + 480 mg DHA + warm compresses, lid massage, artificial tears (n = 30)	Warm compresses, lid massage, artificial tears only (n = 30)	12 weeks	- OSDI score (−25.4 vs −9.0) - TBUT (+5.2 vs + 2.5) - Ocular protection index (+1.0 vs + 0.5) - Fluorescein staining score (−3.1 vs −2.1) - Meibum expressibility (−0.8 vs −0.3)	- Rose bengal staining score (−1.6 vs −1.4) - Schirmer score (−0.8 vs 0.0)

(continued on next page)

Table 1 (continued)

Study (author, year)	Type of dry eye	Intervention (daily dose)	Comparator (daily dose when applicable)	Duration	Parameters with significant improvement to comparator (including effect size if available)	Parameters without significant improvement to comparator (including effect size if available)
Kawakita et al., 2013 [218]	Dry eye (symptoms and signs)	Fish oil (1245 mg EPA, 540 mg DHA) (n = 15)	Mainly middle-chain triglycerides (n = 12)	12 weeks	- Meibum quality (−7.1 vs −1.7) - Contrast sensitivity (several photopic and mesopic variables) - Symptom score - TBUT - Rose bengal staining	- Schirmer score - Fluorescein staining
Kangari et al., 2013 [219]	DED (symptoms)	360 mg EPA + 240 mg DHA (n = 33)	Middle-chain triglycerides (n = 31)	30 days	- OSDI score (−26% vs −4%) - TBUT (71% vs 3.3% improvement) - Schirmer score (22.3% vs 5.1% improvement)	None
Deinema et al., 2017 [77]	Mild to moderate DED (signs and symptoms)	Fish oil (1000 mg EPA + 500 mg DHA) (n = 19) or Krill oil (945 mg EPA + 510 DHA) (n = 18)	Olive oil (1500 mg) (n = 17)	3 months	- Tear osmolarity for both fish oil and krill oil (−19.8 vs −18.6 vs −1.5) - OSDI for krill oil only (−18.6 vs −10.5) - TBUT - Ocular redness for both fish oil and krill oil (−0.3 vs −0.5 vs + 0.2) - Tear IL-17 A level for krill oil only (−27.1 vs + 46.5)	- NIBUT - Ocular surface staining - Tear volume (TMH) - Schirmer score - Anterior blepharitis degree - MG capping degree - Tear IL-2, IL-4, IL-6, IL-10, IFN- $\gamma$ , TNF $\alpha$ levels
Epitropoulos et al., 2016 [220]	DED diagnosis with MGD stage 1 or 2 (mild to moderate)	1680 mg EPA + 560 mg DHA (n = 54)	3136 mg linoleic acid (n = 51)	12 weeks	- OSDI score (−17.0 vs −5.0) - Tear osmolarity (−19.4 vs −8.3) - TBUT (+3.5 vs + 1.2) - MMP-9 positivity (−67.9% vs −35.0%)	- Oxford corneal staining (−0.6 vs −0.6) - MGD stage (−0.3 vs −0.4) - Schirmer score (+1.6 vs + 1.3)

DED = dry eye disease; DHA = docosahexaenoic acid; DPA = docosapentaenoic acid; EPA = eicosapentaenoic acid; IL = interleukin; IFN = interferon; MG = meibomian gland; MGD = meibomian gland dysfunction; MMP = matrix metalloproteinase; NIBUT = non-invasive breakup time; OSDI = Ocular Surface Disease Index; SANDE = Symptom Assessment in Dry Eye questionnaire; TBUT = tear breakup time; TFOU DEWS = Tear Film and Ocular Surface Society Dry Eye Workshop; TNF = tumor necrosis factor.

(six randomized controlled trials) results could not be meta-analyzed. Of the six trials [224–229] that investigated the effect of oral omega-6 fatty acids (with either  $\gamma$ -linolenic acid (GLA) or a combination of linoleic acid (LA) and GLA), only one study [224] reported a greater improvement of dry eye symptoms compared to placebo.

Overall, the authors concluded that there is a possible role for long-chain omega-3 supplementation in dry eye disease, with effects more likely for clinical signs than for symptoms, but evidence was judged to be uncertain and inconsistent. The authors also noted that the effect of omega-3 fatty acids on symptoms was not significant when a placebo supplement was used as comparator, but was significant when omega-6 supplementation (e.g. corn and safflower oil) was used as the comparator, suggesting a possible important role for the relative ratio of omega-3 to omega-6 consumption [9]. This may also suggest that omega-6 does not serve well as a control. The authors also judged none of the 34 included studies to have a low risk of bias in all seven possible domains.

Another meta-analysis investigated possible benefits of omega-3 versus placebo and included 17 randomized controlled trials with a total 3363 patients. The authors reported that omega-3 supplementation decreased dry eye symptoms, and improved corneal fluorescein staining, tear breakup time and Schirmer scores compared to placebo [16]. A reason for the different findings with respect to symptom improvement compared to the previous Cochrane review, was that the Cochrane review meta-analyzed only studies that included the Ocular Surface Disease Index (OSDI) symptom score, while the other meta-analysis also included studies that utilized other symptom questionnaires. Also, the meta-analysis included studies investigating short-chain omega-3-polyunsaturated fatty acids (from flaxseed oil) in addition to long-chain omega-3 polyunsaturated fatty acids, and the authors did not undertake separate investigations for placebos/comparators with or without omega-6. In a meta-regression analysis, the authors found a greater

improvement of symptoms and tear breakup time with omega-3 in studies performed in India. The authors speculate that omega-3 fatty acid dietary intake in India may be lower due to a predominantly vegetarian diet, indicating a role of baseline omega-3 values in the amount of treatment effect [16]. No relationship between efficacy and the dose or duration of omega-3 treatment was found [16].

Another meta-analysis of 13 randomized controlled trials found that patients who received fatty acids (both omega-3 and combined omega-3 and omega-6) treatment without other eye medications showed greater improvement than placebo in tear breakup time, Schirmer scores, tear osmolarity and OSDI scores [15]. This improvement was not observed or was observed to a lesser degree in those who used supplemental fatty acids concurrent with other eye treatments. The authors also found that this positive effect weakened with treatment duration for tear breakup time and OSDI [15].

**3.4.6.1.3. Results of individual primary research studies.** The Dry Eye Assessment and Management trial, the largest randomized clinical trial to-date on the effect of omega-3 fatty acids [8], involved a total of 349 dry eye patients who were assigned to receive fish-derived omega-3 (2000 mg eicosapentaenoic acid plus 1000 mg docosahexaenoic acid/day) for 12 months, and 186 patients to receive placebo (olive oil). Mean change in the primary outcome variable, OSDI symptom score, was not significantly different between groups (−13.9 vs −12.5,  $p = 0.21$ ). Also, no significant differences were seen between groups in the secondary outcomes of corneal and conjunctival staining scores, tear breakup time and Schirmer scores. In addition, an extension study showed that those who had received omega-3 supplements for 12 months and stopped these did not have significantly worse outcomes than those who continued omega-3 supplements for an additional 12 months [78]. A study looking at additional outcome variables did find a significant improvement compared to placebo for tear osmolarity ( $p = 0.02$ ),

**Table 2**

Overview of randomized clinical trials of combined oral omega-3 and -6 fatty acid supplementation for dry eye.

Study (author, year)	Type of dry eye	Oral omega-3/-6 fatty acid daily dose (sample size studied)	Comparator	Duration	Parameters with significant improvement to comparator (including effect size)	Parameters without significant improvement to comparator (including effect size)
Larmo et al., 2010 [221]	DED (symptoms)	2 g sea buckthorn oil (n = 45)	2 g placebo oil (n = 41)	3 months	- Tear osmolarity (+8 vs +12)	- TBUT (0 vs +1) - Schirmer score (0 vs 0) - OSDI score (-5 vs -4) - 'Significant improvement' of tear osmolarity compared to placebo, but still an increase in dry eye (tear osmolarity increased in both groups).
Brignole – Baudouin et al., 2011 [202]	Mild to moderate DED (signs and symptoms)	Fish oil (427.5 mg EPA + 285 mg DHA) + 15 mg borage oil (omega-6 source) + several other vitamins/antioxidants (n = 61)	575 mg medium-chain triglycerides (n = 66)	3 months	- HLA-DR positive cells % (-8.10 vs -0.06)	- Symptom score (-2.6 vs -1.8) - Schirmer score (+0.5 vs +0.4) - BUT (+0.5 vs +0.4) - Fluorescein staining (-0.7 vs -0.5) - Lissamine staining (-1.4 vs -0.9)
Sheppard et al., 2013 [222]	Moderate and severe DED, postmenopausal women	196 mg ALA + 126 mg EPA + 99 mg DHA + 39 mg DPA + 710 mg LA + 240 mg GLA + <3 mg ARA + several vitamins and magnesium (n = 19)	Sunflower oil (n = 19)	24 weeks	- OSDI scores - HLA-DR expression - CD11c-positive dendritic cells - Corneal surface asymmetry index	- Corneal surface regularity index - Schirmer score - TBUT - Fluorescein and lissamine green staining - Lid margin erythema - Chemosis - Adjunctive artificial tear use
Ng et al., 2021 [223]	Moderate to severe DED (TFOS DEWS II criteria: both symptoms and signs)	1200 mg EPA + 300 mg DHA + 150 mg GLA (n = 24)	Coconut and olive pomace oil (n = 26)	3 months	None	- OSDI score - SANDE score - Schirmer score - NIBUT (and many other 2nd outcome variables)

ALA = alpha-linolenic acid; ARA = arachidonic acid; CD11c = cluster of differentiation 11c; DED = dry eye disease; DHA = docosahexaenoic acid; DPA = docosapentaenoic acid; EPA = eicosapentaenoic acid; GLA = gamma-linolenic acid; HLA-DR = human leukocyte antigen D-related; LA = linolenic acid; MMP = matrix metalloproteinase; OSDI = Ocular Surface Disease Index; TBUT = tear breakup time; TFOS DEWSII = Tear Film and Ocular Surface Society Dry Eye Workshop II.

however the authors questioned the clinical significance of the lower tear osmolarity finding. No differences between groups for tear matrix metalloproteinase-9 levels, tear meniscus height, bulbar conjunctival redness or meibomian gland dropout were found [230]. Another add-on study demonstrated no clear or consistent changes in ocular inflammatory status as measured by the frequency of HLA-DR-expressing conjunctival cells and tear cytokines (interleukins-1 $\beta$ , -6, -8, -10, -17 A, interferon- $\gamma$ , tumor necrosis factor- $\alpha$ ) between groups [231]. It should be noted that the previously described Cochrane review [9] did include the results of the Dry Eye Assessment and Management study in their analyses [231]. A significant shortcoming of the Dry Eye Assessment and Management trial is that the authors evaluated only one eye, making it difficult to account for the known heteroskedasticity of dry eye disease.

Since the meta-analyses, several new randomized controlled trials have been published on the effects of omega-3 and omega-6 fatty acids on dry eye-related phenotypes. An investigation of the effect of omega-3 fatty acids, in addition to a soft silicone plug placed in the inferior punctum, in non-dry eye patients who had used systemic isotretinoin therapy for at least four months found no significant improvements in OSDI, tear breakup time, tear osmolarity, Schirmer scores, ocular surface staining score for the group that received additional omega-3 fatty acids compared to the punctal plug only group. Meibum quality, however, was significantly better in the group that had received omega-3 fatty acids [232].

A randomized controlled trial using a re-esterified triglyceride form of omega-3 fatty acids (1680 mg eicosapentaenoic acid and 506 mg docosahexaenoic acid/day for eight weeks), which may have higher bioavailability than the ethyl ester form, found a reduction in ocular surface inflammation (matrix metalloproteinase-9), Oxford staining and symptoms scores compared to placebo. These changes occurred in a

setting of new-onset dry eye, one month after uncomplicated cataract surgery, indicating a possible role for omega-3 fatty acids in managing surgically-induced dry eye [211].

A study of a daily oral supplement containing both omega-3 and omega-6 fatty acids (1200 mg eicosapentaenoic acid, 300 mg docosahexaenoic acid, and 150 mg  $\gamma$ -linoleic acid) for three months versus placebo (coconut and olive oil) in 50 patients with moderate-to-severe dry eye disease found no differences between groups in any of the ocular outcome variables (OSDI score, Symptom Assessment Questionnaire iN Dry Eye (SANDE) score, tear breakup time, tear meniscus height, tear osmolarity, ocular surface staining, Schirmer score or meibography). A post hoc subgroup analysis did find a significant improvement in dryness symptoms compared to placebo, however, in highly symptomatic patients (OSDI-score > 52, n = 25) [223].

A randomized controlled trial in 24 patients with mild-to-moderate dry eye disease with MGD evaluated a formulation with 600 mg eicosapentaenoic acid and 1640 mg docosahexaenoic acid and compared this with placebo containing 3000 mg of olive oil. Borderline significant improvements in tear breakup time and MGD scores were observed compared to placebo, while an improvement was not apparent for corneal staining, OSDI score, and strip meniscometry [212].

A recent study investigated whether supplementation of marine omega-3 fatty acids (1 g daily) and vitamin D<sub>3</sub> (2000 IU daily) prevented onset of dry eye disease in healthy adults, as an ancillary study within the vitamin D and omega-3 trial (VITAL) that investigated the prevention of cancer and cardiovascular disease [233]. In 23,523 adults aged 50 years and over, who were free of a diagnosis of dry eye disease at study entry, supplementation over 5.3 years (range 3.8–61 years) did not reduce the incidence of dry eye disease (with or without incidence of severe dry eye symptoms) [233].

**3.4.6.1.4. Other oils as comparators.** Oils including olive, corn, and



safflower oil have been used as oral comparators in several of the omega fatty acid trials on dry eye. Corn oil and safflower oil contain omega-6 fatty acids, which may be pro-inflammatory [234] and may have an adverse effect on dry eye. This, in turn, may enhance the chance of finding a difference with omega-3 fatty acid intervention in trials [9]. Olive oil contains oleic acid and polyphenols (particularly extra virgin olive oil) which have been shown to have anti-inflammatory and anti-oxidative properties [235,236], although any effect on the ocular surface is currently unknown. It may be that oils, excluding polyunsaturated fatty acids, may have a beneficial effect on the ocular surface and may not act as a true placebo in these studies. Also, the Mediterranean diet, which is rich in olive oil but also includes other potential healthy elements, may be protective of dry eye (see Section 3.8.1.2).

**3.4.6.2. Corneal neuroprotection.** A pilot randomized controlled trial involving 12 participants with dry eye found that daily omega-3 fatty acids (1000 mg eicosapentaenoic acid + 500 mg docosahexaenoic acid) for 90 days significantly increased corneal nerve branch density and corneal nerve fiber length compared to placebo, indicating neuroprotective effects in the corneal sub-basal plexus [81]. A larger double-masked randomized controlled trial investigated the effects of oral omega-3 supplementation versus placebo on corneal nerve fibers in 43 patients with type 1 diabetes. Central corneal nerve fiber length increased significantly more with oral omega-3 than with placebo at day 180, again indicating a role of omega-3 in modulating peripheral nerve health [237]. A meta-analysis of omega-3 supplements for improving peripheral nerve health found low certainty evidence of a reduced incidence of peripheral neuropathy and a preservation of sensory nerve action potential amplitude compared to placebo in individuals receiving chemotherapy, but concluded evidence is too limited to extrapolate the findings to predict benefits in other conditions characterized by peripheral nerve damage [238]. Future studies with adequate statistical power are needed to elucidate any neuroprotective effects of omega-3 fatty acids at the ocular surface [20].

**3.4.6.3. Allergic eye disease.** Although a meta-analysis found evidence for benefits of increased omega-3 fatty acids in the maternal diet in the prevention of childhood allergic disease, including atopic eczema, food sensitization and positive skin prick tests [19], no trials on allergic eye disease have been reported in humans. A protective effect of a diet rich in omega-3 fatty acids on ragweed pollen-induced allergic conjunctivitis in mice was found in one study [239]. T helper 2 immune responses and total serum immunoglobulin E levels were not affected, but levels of omega-6-derived proinflammatory lipid mediators in the conjunctiva were markedly reduced in these mice [239], indicating a role of lipid mediators and omega-3 fatty acids in allergic conjunctivitis [240]. Further studies, and particularly human studies, are needed to confirm any role for omega-3 fatty acids in the treatment of allergic conjunctivitis.

**3.4.6.4. Safety.** All meta-analyses discussed concluded that polyunsaturated fatty acids have relatively few adverse events, but only about half of randomized controlled trials contained a report on the presence or absence of adverse effects [9]. Similarly, a meta-analysis on the effects of omega-3 fatty acids on eye health (but not including any ocular surface disease) concluded that intake was associated with few minor, mostly gastrointestinal, side-effects, but also noted that studies often do not report minor issues, and that more studies were needed to assess their safety [14]. Caution should be exercised when polyunsaturated fatty acid supplementation is prescribed to patients with blood clotting disorders as omega-3 fatty acids have the potential to reduce platelet activity, although convincing evidence of increased risk of bleeding after supplementation is lacking [241,242]. Indeed, patients with cardiovascular disease taking high dose fish oil combined with both

aspirin and clopidogrel showed no increased risk of bleeding compared to patients on aspirin and clopidogrel alone [243]. Similarly, fish oil supplementation did not increase perioperative bleeding and actually reduced the number of blood transfusions in 1516 patients post-cardiac surgery [244]. A meta-analysis of 52 publications (32 of these being on healthy participants and 20 on patients undergoing surgery) confirmed these findings and found no increased risk of bleeding during or after surgery, despite the finding of reduced platelet aggregation in healthy participants [245]. Other diseases where precaution has been advised are liver disease and atrial fibrillation [75]. Omega-3 serum levels in men have also been linked with an increased risk of prostate cancer [246]. None of these safety precautions or side-effects have high-level evidence. Indeed, the European Food Safety Authorization concluded that long-term supplemental intakes of eicosapentaenoic acid and docosahexaenoic acid up to 5 g/day was not associated with bleeding complications or other safety concerns for adults [247]. The Food and Drug Administration of the USA recommends a daily intake of omega-3 of 500 mg/day, with no more than 3000 mg, with a maximum of 2000 mg from supplements [242].

**3.4.6.5. Recommendations for treatment and future studies.** Given the current possible efficacy and their relatively favorable safety profile, omega-3 fatty acids may be a relevant treatment option for patients with dry eye disease and MGD, acknowledging that their exact role in treatment remains incompletely understood. Indeed, a survey of optometrists in Australia and New Zealand found that eye care clinicians frequently prescribe oral omega-3 fatty acid supplements to their patients to manage both aqueous-deficient and evaporative dry eye disease [248]. The TFOS DEWS II report included the use of omega-3 fatty acids as one of several first step options in their staged dry eye disease management and treatment recommendations [75]. Another recommendation is that baseline measurements of omega-3 status are reported, potentially using surveys as a surrogate measure of blood levels of omega-3 fatty acids [249]. Future studies should determine if, and possibly which, dry eye patient subgroup(s) (subtype and/or severity of dry eye, or those who are omega-3 deficient) might benefit most from supplementation, whether a certain form or composition is preferable, what dosage and duration is best to recommend, and what dietary ratio of omega-3 to -6 is optimal for dry eye.

Assessment of dietary omega-3 intake needs to be qualified by the degree of successful endogenous conversion of  $\alpha$ -linolenic acid (the parent of the omega-3 family) to long chain fatty acids, for example [250]. A number of factors such as genetics, sex, age and dietary composition affect the process of conversion which is slow and inefficient. Consequently, a red blood cell measure of the degree of any omega-3/omega-6 imbalance (e.g., the Omega-3 Index [220]) could better guide therapeutic nutrition interventions and anticipated responses to them. The degree and rate at which omega-3 fatty acids are absorbed or made available at the site of physiological activity (bioavailability) may be independent of dietary intake [251].

Appropriate sample size calculation, prospective trial registration, provision of details regarding the polyunsaturated fatty acids intervention including form, and best practice dry eye diagnostic criteria to include participants are key recommendations from these studies [9].

### 3.4.7. Spices

Where herbs are derived from the leaves of a plant, spices are derived from the dried non-leafy parts such as seeds, roots, bark, buds, flowers and fruits [182]. It has been claimed that spices promote health, reduce mortality, and protect against the development of acute and chronic disease courtesy of their antioxidative, anti-inflammatory, anticarcinogenic, antimicrobial, and glucose- and cholesterol lowering activity. They may also favorably alter gut microbiota [252]. Research on the potential beneficial role of spices in ocular surface disease has been mostly focused on curcumin.

Curcumin is the principal curcuminoid of turmeric, a plant of the ginger family. It is an orange-yellow-colored polyphenol. Curcumin has been found to inhibit oxidative stress, angiogenesis and inflammatory processes in the human body and to help with restoring homeostasis [253–255]. Several *in vitro* and animal studies have found positive effects of topical curcumin agents in preventing corneal neovascularization [156,256–258], promoting corneal wound healing [259], and inhibiting pathophysiological pathways of allergic conjunctivitis [260], pterygium [261,262] and corneal endothelial dysfunction [263,264].

Curcumin as a dietary source or food supplement has been less studied. A double-masked, randomized controlled trial with a supplement containing curcumin, lutein, zeaxanthin and vitamin D3 taken for 8 weeks showed significant improvements in ocular symptoms, Schirmer scores, tear breakup time and corneal staining scores compared to placebo in participants with mild-to-moderate dry eye [265]. Improvements in tear volume, tear breakup time, and tear inflammatory markers were also seen in an earlier study with the same supplement in rats, with benzalkonium chloride-induced dry eye [266]. Oral administration of both ultrasoluble curcumin and ultrasoluble turmeric showed reduced lymphadenopathy and salivary gland infiltrates and increased survival in mouse models of Sjögren syndrome and systemic lupus erythematosus [267]. In addition, in an *in vitro* study, curcumin has been shown to reduce mRNA expression as well as secretion of interleukin-6 by the salivary gland tissue from Sjögren patients [268]. Clearly, more research is needed to assess the potential beneficial role of dietary curcumin in both Sjögren syndrome and non-Sjögren syndrome dry eye.

#### 3.4.8. Seeds

There is little evidence in humans about the therapeutic or prophylactic effects of plant seeds on ocular surface disease, with no systematic review or meta-analysis. Some seeds have been reported to be effective against ocular surface disease in clinical studies. For example, topical instillation of the polysaccharide from tamarind seed has been reported to improve dry eye symptoms, perhaps because the polysaccharide has a mucin-like structure [269,270].

Further research is needed to determine the various effects of seed extracts on the ocular surface.

#### 3.4.9. Vitamin supplementation

Deficiency in vitamins A or D and the impact on the ocular surface is discussed in Section 3.1.2.1. Local ocular administration, oral administration, or systemic administration of vitamin A improves xerophthalmia symptoms [271–278]. Systemic vitamin A supplementation (oral or intramuscular) may reduce ocular surface abnormalities by goblet cell re-population of the conjunctiva and increasing their density, corneal re-epithelization and improved tear film quality [273,279–281]. Short-term (3 days) oral (1500 mg) vitamin A supplementation study on 30 male patients with dry eye compared to healthy age-matched men suggested that short-term oral vitamin A supplementation improves the quality of tears and not quantity in patients with dry eye [279].

The International Workshop on Meibomian Gland Dysfunction presented evidence that 13-*cis* retinoic acid, a metabolite of vitamin A, and retinoids in general, can cause significant damage to meibomian glands such as keratinization, glandular atrophy and abnormal secretions if applied topically to or near the eye [103]. Whether conversion of dietary vitamin A to 13-*cis* retinoic acid can also have these adverse effects has yet to be studied.

Clinical trials have reported that topical administration of vitamin B<sub>12</sub> to the eye improves dryness symptoms [282,283]. In a hypothesis-free study looking at medication use and associated risk of dry eye symptoms, those taking vitamin B<sub>12</sub> and folic acid were significantly more likely to have symptomatic dry eye disease [284].

In an uncontrolled study, 50 individuals with diabetes were administered a combination of vitamins C (1000 mg/day) and E (400 IU/day)

for a period of 10 days. An improvement in tear production, stability, density of goblet cell density and squamous metaplasia grade was reported relative to baseline [285]. These effects were attributed to a significant reduction in the levels of nitric oxide measured in lacrimal lavage fluid, which may indicate that these vitamins contribute to a decrease in ocular surface oxidative stress [285]. A randomized controlled trial assessing the efficacy of 8 weeks supplementation of the antioxidants astaxanthin, vitamins A, C, E and herbal extracts in the treatment of patients with dry eye disease, with follow-up every 4 weeks for 16 weeks [122], found improved Schirmer score (at week 8) and tear breakup time (at weeks 4 and 16), relative to the control group [122].

Studies have observed an improvement in dry eye discomfort symptoms and signs such as Schirmer score, tear breakup time and corneal staining after vitamin D supplementation in patients with dry eye disease and low serum vitamin D, especially with those who had disease refractory to conventional treatment [286,287]. Oral vitamin D supplementation appears to improve the efficacy of topical treatment with vitamin D in patients with dry eye disease resistant to topical lubricant therapy [288].

The previous sections reviewed the impact of specific nutritional components and supplements on the ocular surface. Severe malnutrition, rather than deficiency in a single nutrient, may lead to a significant decrease in tear immunoglobulin A and secretory concentrations, a diminished number of immunoglobulin A-containing cells in lacrimal tissue and a blunted secretory immunoglobulin A antibody response to infectious challenge [289–292]. Sections 3.5 to 3.9 inclusive, therefore, take a more holistic approach to nutrition, reviewing the impact of eating disorders, food intolerance and allergy, as well as various diets on nutrition, and their subsequent impact on the ocular surface. The relationship between the gut microbiome and the ocular surface is also explored.

### 3.5. Eating disorders

Psychological eating disorders, anorexia nervosa and bulimia nervosa, can result in such severe disease states that patients become deficient in many vitamins and minerals [293]. Anorexia nervosa is defined as a restriction of energy intake and low body weight that is associated with an intense fear of gaining weight and an undue influence of body weight or shape on self-evaluation [294]. Bulimia nervosa is also associated with fear of weight gain and over-emphasis of body weight on self-evaluation. Instead of the restriction of energy intake, however, bulimia nervosa is associated with recurrent episodes, at least weekly, of binge eating followed by compensatory behaviors to prevent weight gain (e.g., self-induced vomiting, misuse of laxatives and excessive exercise) [294]. The literature is lacking in regard to ocular surface manifestations of bulimia nervosa; therefore, the emphasis in this section is on what is known in the context of anorexia nervosa.

To date, there have been only a few reports that have described ocular manifestations of malnutrition associated with anorexia nervosa; none is a rigorous, comparative, cohort study with adequate sample size. In 1980, a cross-sectional study of 13 patients with anorexia nervosa and 13 controls found no intergroup differences in visual acuity, refractive status and the anterior segment [295]. The authors concluded that lenticular and conjunctival changes were uncommon in patients with anorexia nervosa; however, the small sample size used in this study would render the detection of any mild differences unlikely. A report described ptosis, enophthalmos and lagophthalmos in a case series of five patients hospitalized for multi-organ dysfunction due to severe anorexia nervosa [296]. The authors proposed that severe anorexia nervosa may lead to orbital fat wasting, predisposing to enophthalmos and an inability to attain complete lid closure [296]. Eyelid petechiae have also been reported in one patient with a purging subtype of anorexia nervosa [297]. In a recent large population-based cohort study of almost 80,000 persons in the Netherlands, eating disorders (present in 1.4% of the population) were significantly associated with a 1.64 times

higher risk of dry eye disease [111]. Future work should aim to identify, comprehensively, how anorexia nervosa-induced malnutrition manifests in the eye, at what severity of disease each sign is likely to present, the visual and ocular prognosis associated with each sign, and how best to manage ocular complications of anorexia nervosa in the presence of a challenging condition.

### 3.6. Food intolerance

Food intolerance is a non-allergic, non-immune-mediated reaction and includes metabolic, pharmacologic, toxic and undefined mechanisms [11]. This can include intolerances to lactose, fructose, fructans, fermentable oligosaccharides, disaccharides, monosaccharides, polyols [298], gluten, food colorings, preservatives and sulfites. Food intolerance has been associated with asthma, chronic fatigue syndrome and irritable bowel syndrome [298]. Unlike food allergy which may manifest within 2 h, symptoms relating to food intolerance may take 12–24 h to manifest [299]. The symptoms can include unexplained bloating, belching, distension, gas, abdominal pain and diarrhea [298]. Intolerance to food additives has been found to result in non-allergic rhinitis in 5% of cases [300]. To date, there are no data on the effect of food additives on the ocular surface, although in a population-based cohort study, lactose intolerance was associated with a trend towards increased dry eye disease (1.8 times greater risk,  $p = 0.07$ ) [111].

### 3.7. Food allergy

Food allergies involve responses to food proteins such as eggs, milk, peanuts, tree nuts, soy, wheat, crustacean shellfish, and fish [11]. Immunoglobulin E-mediated reactions are reported to affect 5% of children under the age of five years, and 4% of teens and adults [301]; they can range from mild to severe, with severe cases on rare occasion resulting in anaphylaxis and even death. Non-immunoglobulin E-mediated gastrointestinal food allergic disorders are characterized by subacute and/or chronic symptoms, including food protein-induced allergic proctocolitis, enterocolitis syndrome, enteropathy, celiac disease and cow milk-induced iron deficiency anemia [302].

Food allergy might manifest at the ocular surface in the form of allergic conjunctivitis in approximately 14% of people who have food allergies (data from abstract only) [303]. A population-based cohort study reported that food allergy was associated with a 1.4 times increased risk of dry eye disease [111]. The ocular mucosa provides an accessible site for antigen deposition by virtue of its large and exposed surface area [304]. Within seconds to minutes following exposure in sensitized individuals, pro-inflammatory cytokines are released to stimulate immunoglobulin E. Immunoglobulin E then becomes membrane bound to mast cells, triggering mast cell degranulation and release of histamine, tryptase, leukotrienes and prostaglandins [305]. Clinically, in the early phase, this typically manifests as itching of the ocular surface and eyelids, as well as photophobia, watery discharge, conjunctival redness, chemosis and a tarsal papillary reaction [306]. The late phase involves epithelial infiltrates due to the increased presence of neutrophils, lymphocytes, basophils and eosinophils, and drainage of tears carrying allergens into the nasal passage [306].

Fast foods are typically calorically dense, high in refined carbohydrates, sodium, sugar, cholesterol, and additives, with high concentrations of saturated fat. In a meta-analysis involving pooled data from four studies, consumption of fast food, particularly hamburgers, was found to be associated with rhino-conjunctivitis [307]. While a dose-response could be established for asthma, it could not be established for rhino-conjunctivitis with the limited data available [307]. The association between poor diet and BMI, as well as poorer nutrition are likely to contribute to the manifestation of allergic disease [307], for example, by contributing to chronic inflammatory disease.

## 3.8. Different diets and the ocular surface

### 3.8.1. Global influences

Diet can vary markedly depending on the region and the culture. In a quest to identify the secrets to longevity, five places around the world have been labelled as “blue zones”, where life expectancy often exceeds the age of 100 years [308]: Loma Linda, CA, USA; Nicoya, Costa Rica; Sardinia, Italy; Ikaria, Greece; Okinawa, Japan. Nine evidence-based common denominators have been identified between these regions, including nutrition [308]. Whether these regions and their associated diets also impact on ocular surface health is unclear. The subsequent sections review current knowledge regarding global influences on diet and the impact on ocular surface health.

**3.8.1.1. Western diet.** The Western diet is a modern dietary pattern that is generally characterized by high intakes of red meat, processed meat, pre-packaged foods, butter, salt, candy/lollies, sweets, fried foods, high-fat dairy products, conventionally- or pasture-raised animal products, eggs, saturated fats, refined grains, potatoes, corn, high-sugar drinks, alcohol, but low intakes of fibers, fruits, vegetables, whole grains, fish and seeds [309]. It is also characterized by high-calorie daily intake, sedentary lifestyle, and increased consumption of fast-food. In summary, the Western diet is a relatively high-fat and a high-sugar diet [310]. Based on epidemiological studies, the Western diet is positively correlated with an elevated incidence of obesity, death from heart disease and cancer [311–313] and systemic low-grade inflammation attributed to endotoxemia [314].

In a mouse model, a high-fat diet causes a reduction in peroxisome proliferator-activated receptor  $\gamma$  expression and mitogen-activated protein kinase and nuclear factor kappa-light-chain-enhancer of activated B cells signaling pathway activation. This was associated with an increase in incidence in MGD [315]. In addition, a high-fat diet was linked to pathophysiological changes and functional decompensation of the lacrimal gland in mice [316].

The effect of a high-fat diet on mouse corneal nerve density and resident immune cells has been studied [317]. The summed length of the nerves within the basal nerve plexus was lower in the central and peripheral cornea, the epithelial immune cell density was two-fold higher in the central cornea and the percentage of nerve-associated major histocompatibility complex-II(+) cells in the epithelium was also higher in high-fat diet mice compared to controls. The study concluded that systemic metabolic disturbance induced by a high-fat diet disrupts the neuroimmune status of the cornea [317].

Also in the mouse model, a high-fat diet induced decreased tear production, ocular surface staining and goblet cell loss [318]. It further resulted in corneal epithelial barrier dysfunction and significant squamous metaplasia of the corneal and conjunctival epithelia [318]. The high-fat diet also upregulated key factors that regulate oxidative stress in the ocular surface, and upregulated cell apoptosis in ocular surface epithelial cells [318].

Gut microbial dysbiosis has also been related with a high-fat diet [319]. This diet, perhaps influenced by the gut dysbiosis, has been reported to alter corneal immune cell distribution, corneal response to injury, and genes related to epithelial function and corneal immunity in mice [319].

Further studies are needed to examine the impact of the Western diet on the ocular surface.

**3.8.1.2. Mediterranean diet.** The Mediterranean diet is inspired by the eating habits of individuals originating from the lands surrounding the Mediterranean Sea. When initially defined in the 1960s, it drew on the eating habits of the populations in Greece, Italy, and Spain. It has also incorporated elements of other Mediterranean diets such as those of North Africa and the Middle East [320]. The principal aspects of the Mediterranean diet include proportionally high consumption of olive



oil, legumes, unrefined cereals, fruit and vegetables, moderate to high consumption of fish, moderate consumption of dairy products (mostly as cheese and yogurt), moderate wine consumption, and low consumption of red and processed meat and sugar [321]. The Mediterranean diet has been associated with a reduction in all-cause mortality [322,323]. It is low in saturated fat with high amounts of monounsaturated fat and fiber. One possible factor for the health benefits of the Mediterranean diet, is olive oil. Olive oil contains monounsaturated fats, most notably oleic acid, which may have a role in protecting blood lipids from oxidation [324]. The Mediterranean diet may help obese people lower the quantity and improve the nutritional quality of food intake, with an overall effect of possibly losing body weight [325]. Intermittent fasting or food restriction also accompanies the three main religions of the Mediterranean Sea [from which arise Catholic Friday, Black Fast and Lent; Muslim Ramadan; Judaism BaHaB (a Hebrew acronym for Monday, Thursday, Monday)].

The Mediterranean diet has been reported to be useful in chronic inflammatory diseases due to its antioxidant and anti-inflammatory properties [326]. It thus might be expected to have benefits in treating inflammatory diseases of the ocular surface, such as dry eye disease.

Stricter adherence to a Mediterranean diet has been associated with a lower likelihood of developing primary Sjögren syndrome [327]. In a separate study, 34 participants with ocular surface discomfort were randomized into one of two interventional arms: (1) a standard intervention group on a Mediterranean diet supplemented with extra virgin olive oil and nuts; (2) an intensive intervention group, based on a hypocaloric Mediterranean diet and an intensive lifestyle program with physical activity and weight-loss. In both groups, OSDI (the Dry Eye Scoring System), tear breakup time, Schirmer score (after application of topical anesthesia), and the Oxford staining grade improved after six months. However, the intensive intervention group showed greater improvements after six months in tear breakup time, Schirmer and Oxford staining scores [328]. In contrast, a cross-sectional study of 247 men found that adherence to a Mediterranean diet was associated with more severe dry eye disease [329]. There are several potential explanations for these findings including: the Mediterranean diet differed between the studies; the diet may not be an ideal dietary pattern for control of dry eye, with the effect of alcohol possibly counteracting any possible effect from other nutrients; patients with dry eye disease in the control group may have improved their diet to help alleviate their condition; or these results were confounded by unmeasured variables or small sample size.

**3.8.1.3. African diets.** The Central African diet includes plantains, cassava, rice, and yam. The main ingredients of the East African diet are corn, lentils, wheat and vegetables. Meat products are generally absent. The North African diet includes wheat, olives, vegetables, spices, and sheep meat. Grain, meat, milk, beer, and vegetables are typical products within the South African diet. The West African diet consists of rice, millet, sorghum, brown beans, fruits, and root vegetables such as yams and cassava and is reported to be within the healthiest diets in the world [330]. No studies have to-date reported on the African diet in relation to potential associations with the ocular surface, other than to note that vitamin A deficiency is common in certain African rural areas [331–333].

**3.8.1.4. Asian diet.** Asia encompasses an expansive continent, with the cuisine and nutrition patterns varying vastly from region to region. In general, Asian Diets, especially traditional Asian Diets, are known to reduce the risk of chronic diseases such as diabetes [334]. There is no clinical evidence in humans about the therapeutic or prophylactic effects of Asian Diet on ocular surface disease, specifically.

### 3.8.2. Food restriction diets

**3.8.2.1. Intermittent fasting.** Intermittent fasting involves switching between fasting and eating on a regular schedule and may be undertaken for religious or other reasons. In a study of 25 individuals one month before and one month during Ramadan fasting, tear lysozyme, lactoferrin and alpha amylase were found to decrease significantly with fasting [335]. In another study of 29 males before and after Ramadan fasting, tear osmolarity, OSDI and corneal staining scores increased significantly, while Schirmer scores assessed without topical anaesthesia decreased during the fasting period, compared to non-fasting [336]. A study of 94 healthy adults found no difference in ocular surface parameters, including tear breakup time [337] with or without fasting, a finding supported by a study of 32 healthy males who were examined at the beginning and end of their fasting period [338]. Conversely, a study of 40 healthy individuals tested before and toward the end of Ramadan showed a significant decrease in tear breakup time, as well as an increase in the number of individuals with a positive matrix metalloproteinase-9 test [339].

**3.8.2.2. Vegetarianism and veganism.** Vegetarianism is the practice of eating no meat and/or fish, and veganism is the practice of not eating or using any animal products or products produced as a result of using animals (such as honey). There is no high level evidence of therapeutic effects on ocular surface health as a result of vegetarianism or veganism, although there are examples of individual case reports describing reversible corneal epitheliopathy in a 27-year-old woman on a vegan diet [340], a 56-year old female vegetarian with herpetic kerato-uveitis and a superimposed pseudomonas infection [341], and of a 6-year-old boy who was a vegan and presented with keratomalacia secondary to vitamin A deficiency [342]. However, these case reports are considered low level evidence, and further studies are required.

**3.8.2.3. Kosher and halal diets.** Kosher diets adhere to Jewish dietary regulations which require that meat must come from ruminant animals with cloven — or split — hooves, such as cows/ox, sheep, goats, oxen, and deer. The Kosher diet also forbids the eating of certain winged animals, permits only those fish which have both fins and scales to be eaten, and forbids consumption of seafood such as shellfish. Halal food is required to be free from any component that Muslims are prohibited from consuming according to Islamic law; as well as food that is processed, made, produced, manufactured or stored using utensils that have been cleansed according to Islamic Law. There are no published reports that examine the impact of these diets on the ocular surface, specifically.

**3.8.2.4. Human milk.** Breast milk has been used to treat various eye conditions including neonatal conjunctivitis, epiphora, dry eye disease and corneal ulcers [343–349], however, this usually refers to topical application. Breast milk is thought to kill bacterial pathogens found on the ocular surface, including those that are most often responsible for neonatal conjunctivitis, such as *N. gonorrhoea* [345]. In a randomized controlled trial, colostrum was found to reduce the incidence of neonatal conjunctivitis compared to controls without any intervention, but not to the same extent as those given the antibiotic erythromycin [346]. Another investigator masked randomized clinical trial examined the efficacy of topically administered breast milk compared to sodium azulene sulphonate hydrate 0.02% and equivalent clinical efficacy for infants with eye discharge [350]. However, the study has been criticized for including infants with multiple causes of eye discharge including nasolacrimal duct occlusion, viral infections and other transient bacterial infections [351]. Breast milk may also contain cytotoxic proteinases that combat *Acanthamoeba* [352], a vision-threatening keratitis that affects contact lens wearers.

Colostrum has been shown to be effective in the treatment of dry eye disease in animal studies, comparable to the use of cyclosporine [353,



354]. Another study compared breast milk to autologous serum tears and artificial tears on induced epithelial defects on mice and found that breast milk-treated mice displayed the fastest healing [355]. A small case series from Nigeria also reported significant adverse events from the application of breast milk on traumatic eye injuries, but many were treated with other home remedies [356]. Better designed randomized trials would be helpful in delineating the true efficacy of topically administered breast milk in combating ocular surface diseases.

There is also some evidence that breastfed infants have lower incidence of rhinoconjunctivitis and other atopic diseases (eczema, asthma, urticaria) compared to formula-fed infants, but it was unclear how many individuals had eye-specific disease [357].

**3.8.2.5. Other diets.** The Paleolithic (Paleo) diet tries to mimic the food intake of hunter-gatherers [358]. It focuses on a high-fiber, high-protein diet and limits processed foods. To date, there have been no published reports on the impact of the Paleo diet on the ocular surface. Ketogenic diets also apply a food restriction approach, with a focus on high-fat and low-carbohydrate intake. No published literature exists on the effects of these diets, specifically on the ocular surface. Anti-inflammatory diets are rich in fruits and vegetables and may include foods containing omega-3 fatty acids and other vitamins that may impact ocular surface diseases. Although no published reports exist on anti-inflammatory diets in particular, the effects of omega-3 fatty acids are covered in Sections 3.1.1.1 and 3.4.6.

A systematic review and meta-analysis on intentional food restriction and its impact on the ocular surface is reported in Section 6.

### 3.9. The gut microbiome and the ocular surface

Section 3.9 introduces the gut microbiome, with the goal being to understand how it can affect the ocular surface.

#### 3.9.1. The gut microbiome: eubiosis versus dysbiosis

The human microbiota describes the set of organisms that inhabit humans, forming a unique ‘holobiont’ for every individual [359]. The microbiota is influenced by environment, diet, genes, disease and other factors. In turn, signaling molecules from the gut microbiota influence gut motility, energy extraction, epithelial integrity and mucosal immunity [360]. In addition to local effects, the gut microbiota exert distal effects on various organs including the brain and skin [361], and the ocular surface [362].

The gut microbiome is composed of two main phyla, Firmicutes and Bacteroidetes, which account for 90% of the gut microbiome. The Firmicutes-to-Bacteroidetes ratio is often used as a rough marker of gut dysbiosis. The remaining phyla are Proteobacteria, Actinobacteria, Fusobacteria and Verrucomicrobia [363,364].

When in an ecologically healthy balance, this complex holobiont ecosystem is termed ‘eubiotic’ (*eu* – Ancient Greek “true” or “good” and *bios* – Ancient Greek “life”) [365]. Ecological shifts within the microbiota can induce imbalance or ‘dysbiosis’ in the gut microbiota which is associated with disease, including chronic disease (Table 3) [366]. Dysbiosis can be induced by many external stimuli including antibiotics, artificial sweeteners, vitamin deficiency, cigarette smoke, saturated (versus polyunsaturated) fats and other anthropogens [366–368].

#### 3.9.2. The impact of diet on the gut microbiome

The typical Western diet of low fiber, high energy and which is considered to be at least partly nutritionally deficient, has been associated with a variety of interconnected, chronic non-communicable diseases. Conversely, there is evidence that plant-based diets, including the Mediterranean diet, can improve gut health and modulate non-communicable diseases [378,379].

Traditional versus Western diets and associated health outcomes were explored in a study comparing the traditional diet of children in

Burkina Faso to that of European children [380]. Children from Burkina Faso are typically breastfed for two years compared to one year for European children; upon weaning, their diet reflects a more typical Neolithic diet, being low in fat and animal protein, and rich in starch, fiber and plant polysaccharides, and predominantly vegetarian; in contrast European children consumed the typical Western diet. Burkina Faso children showed greater overall gut microbiome diversity with significant enrichment in Bacteroidetes and depletion in Firmicutes. This diversity of the microbiome ‘fingerprint’ suggests it is protective against inflammation and non-communicable diseases [380].

**3.9.2.1. Alcohol.** Alcohol consumption adversely alters diversity of the gut microbiome, with enrichment of *Proteobacteria*, *Lachnospiraceae* and *Blautia* and depletion of *Bacteroidetes*, and *Ruminococcaceae*; these changes were maintained following one month of abstinence from alcohol [381]. Additionally, there are increases to intestinal permeability leading to immune system dysfunction with an associated increased production of inflammatory cytokines [382,383]. However, there is one report that showed rapid changes to the gut microbiome following abstinence from alcohol, suggesting resilience of the gut microbiome [384].

Few studies report on the effect of drinking alcohol on the gut microbiome and within these are suggestions of positive effects for specific forms of alcohol, namely fermented (wine and beer) as opposed to distilled (gin, vodka, etc. with increased levels of alcohol). Beer contains prebiotics and polyphenols including catechins and phenolic acids, while wine is enriched in polyphenols including flavonoids, lignans and stilbenes [383,385]. One report indicates increased gut microbiome diversity with moderate red wine consumption [386]. However, contrary to this, another study reported lower levels of the beneficial bacteria *Bifidobacterium*, *Blautia coccoides*, *C. leptum*, and *Lactobacillus* in moderate drinkers compared to teetotalers [387]. These differences may be due to the types of alcohols ingested, and other confounding dietary and lifestyle factors.

**3.9.2.2. Food preparation.** Beyond food itself, ‘diet’ incorporates the processes of food production, preparation, preservation and storage, since the state in which food reaches the table determines much about its overall nutritional value.

Just as the human microbiota form a relationship within the body that is essential for human health, plant roots develop relationships with a hugely diverse soil microbiome that offer important nutrients, protect them from disease and pathogens, and help them to adapt to environmental changes. The rhizosphere microbiome is considered the second genome of the plant [388], analogous to the human gut microbiome [389]. Both microbial communities assist in nutrient uptake, modulate immunity, protect from opportunistic pathogens among other functions [388]. Moreover, plant and human microbiomes are intimately linked since microbes from legumes, fruits and vegetables intercalate with the human gut microbiome such that the plant microbiome influences the human gut microbiome and thereby human health [390].

Alterations to the soil through soil transfer or fertilizer use is equivalent to fecal transplantation in humans or antibiotic use. The use of herbicides, fungicides and pesticides in food production can have catastrophic effects on the soil and plant microbiomes, leading ultimately to shifts in the gut microbiome with consequent ramifications for human health [391].

In the chain of mass production, food must be stabilized for transportation and storage. Additives that retain shape, flavor and freshness can be disruptive to gut integrity, contributing to chronic inflammation [392], and immunogenic reactions for some due to gut dysbiosis [393, 394]. Edible nanoparticles used to coat food for shelf-life preservation and inhibition of organic spoilage have been shown to disrupt the gut microbiome homeostasis [395]. An intriguing ‘Cold Chain Hypothesis’ has drawn parallels between increased cold storage of food and the rise

**Table 3**  
The relationship between the gut microbiome and systemic inflammatory diseases.

Conditions	Relationship with the gut microbiome (GM)
<b>Primary Sjögren syndrome (SS)</b>	<p><b>Clinical evidence</b> (reviewed in [364,369])</p> <ul style="list-style-type: none"> <li>- GM changes is modified in SS patients, compared to controls and inverse correlation with ocular and systemic disease severity</li> <li>- There appears as a continuum in GM changes from healthy patients to SS-patients with non-SS DED patients as intermediates</li> </ul> <p><b>Experimental evidence</b> (reviewed in [364,369,370])</p> <ul style="list-style-type: none"> <li>- Dysbiosis in mice worsens DED secondary to desiccating stress, compared to non-treated mice</li> <li>- In a mouse model of spontaneous SS, sicca syndrome is worse when the diversity of the GM is low, and maximum in germ-free conditions. In the latter case, passive transfer of immune cells to mice with no native T or B cells is sufficient to transfer SS-like signs</li> <li>- Probiotics can reduce DED in an animal model</li> <li>- Several peptides from commensal bacteria activate T cells that are sensitive to Ro60/SSA</li> <li>- Experimental injections of the <i>Escherichia coli</i> outer membrane induce SS-like autoantibodies</li> </ul>
<b>Systemic lupus erythematosus (SLE)</b>	<p><b>Clinical evidence</b> (reviewed in [364,369])</p> <ul style="list-style-type: none"> <li>- GM changes in SLE patients compared to matched controls</li> </ul> <p><b>Experimental evidence</b></p>
<b>Rheumatoid arthritis (RA)</b>	<p><b>Clinical evidence</b> (reviewed in [364,370])</p> <ul style="list-style-type: none"> <li>- GM is less diverse in RA patients than in matched controls (including modified abundance of Prevotella)</li> <li>- Higher frequency of RA patients (32%) with IgG or IgA antibodies reactive with Prevotella</li> </ul> <p><b>Experimental evidence</b> (reviewed in [364,370,371])</p> <ul style="list-style-type: none"> <li>- Modified abundance of Prevotella, Bacteroides, Lactobacillus, and Faecalibacterium reported in RA animal models</li> <li>- Some gut bacteria may modulate autoimmune arthritis by the mean of TH17 cells [372](reviewed in [371])</li> </ul>
<b>B27-related disorders, including spondylarthropathy (SpA)</b>	<p><b>Clinical evidence</b> (reviewed in [373])</p> <ul style="list-style-type: none"> <li>- Bowel inflammation in up to 50% of SpA patients, which furthermore increases when arthritis flares up - Dysbiosis in SpA patients compared to matched controls</li> </ul> <p><b>Experimental evidence</b> (reviewed in [370,374])</p> <ul style="list-style-type: none"> <li>- GM changes in HLA-B27 transgenic rats compared to wild-type rats, with higher gut permeability</li> <li>- Klebsellia, Enterobacter, Shigella or Yersinia may interact with HLA-B27 lymphocytes, and overgrowth is associated with worsened signs</li> <li>- Similarities between some amino-acids sequences encoded by these bacteria and the HLA B27 molecule</li> <li>- HLA B27 may interact with the metabolism of gut bacteria</li> </ul>
<b>Inflammatory Bowel Diseases (IBD)</b>	<p><b>Clinical evidence</b> (reviewed in [375])</p> <ul style="list-style-type: none"> <li>- Dysbiosis in IBD patients compared to matched controls</li> </ul> <p><b>Experimental evidence</b> (reviewed in [376,377])</p> <ul style="list-style-type: none"> <li>- Culture of human DCs with stool extract from IBD patients induces Th2 response, correlated with the severity of IBD in the donor</li> <li>- Microbial translocation (and passage LPS and bacterial DNA in the serum) is central if pathogenesis of IBD in mouse models</li> </ul>
<b>Graft-versus-host disease (GVHD)</b>	<p><b>Clinical evidence</b> (reviewed in [377])</p> <ul style="list-style-type: none"> <li>- GVHD is less frequent in patients with mutations in TLR4 loci (sensor of LPS)</li> <li>- Gut decontamination of gram-negative bacteria just before graft reduces the risk of GVHD in humans</li> <li>- Infusion of a polyclonal antiserum against <i>Escherichia coli</i> before graft reduces the risk of GVHD in humans</li> </ul> <p><b>Experimental evidence</b></p> <ul style="list-style-type: none"> <li>- Gut decontamination of gram-negative bacteria just before graft reduces the risk of GVHD in experimental models</li> </ul>
<b>Atopic diseases</b>	<p><b>Clinical evidence</b> (reviewed in [376])</p> <ul style="list-style-type: none"> <li>- Episodes of gut dysbiosis during the first months of life are associated with increased risk of asthma later in life</li> </ul> <p><b>Experimental evidence</b> (reviewed in [376])</p> <ul style="list-style-type: none"> <li>- Dysbiosis in neonatal mice induces susceptibility to allergic signs in lung</li> <li>- Short chain fatty acid supplementation in dysbiotic mice exhibit reduces the allergic response (in blood and in the lungs)</li> <li>- Probiotics reduce virus-induced and asthma lung inflammations in various animal models</li> <li>- Culture of immune cells with fecal soluble products from 1-month infants at risk for dysbiotic GM favors Th2 cell expansion and reduce Tregs populations</li> </ul>

DED = dry eye disease, LPS = lipopolysaccharide, DCs = dendritic cells, TLR4 = toll-like receptor-4, HLA-B27 = human leukocyte antigen B27, IgA = immunoglobulin A, IgG = immunoglobulin G, TH17 = T helper 17 cells, Th2 = T helper 2 cells.

of chronic disease [396,397]. Early exposure of infants to food that has been cold-stored has been associated with greater risk of developing Crohn's disease in later life [396]. The hygiene hypothesis links increased hygiene to gut dysbiosis and chronic disease [398]. Automated dishwashing compared to handwashing of dishes is suggested to remove an opportunity for robust education of the gut microbiome in children [399].

**3.9.2.3. Other factors that can impair the gut microbiome.** Beyond diet, other lifestyle factors can impair the gut microbiome and lead to leaky gut and systemic inflammation with potential impact on ocular surface health. A sedentary life, smoking and alcohol are all reported to unfavorably alter the gut microbiome resulting in a leaky mucosa, intestinal and systemic inflammation and reduced production of short chain fatty acids [400].

### 3.9.3. The gut microbiome and ocular surface disease

Imbalance of the gut microbiome has been associated with eye

diseases such as uveitis, age-related macular degeneration, glaucoma, chalazion and dry eye disease [362,370,401,402]. The effect of the gut microbiome on the ocular surface, however, needs to be better explored [403]. Clinical and experimental clues about the impact of gut microbiome on the different types of ocular surface disorders are still scarce in the literature, for all except dry eye disease (Table 4).

Animal studies have investigated the effect of diet on dry eye disease. As noted earlier (Section 3.8.1.1), mice fed a high-fat diet had ocular surface damage resembling dry eye, driven by cell apoptosis and CD4<sup>+</sup> T cell mediated ocular surface inflammation [318]. Prior studies have shown that high-fat diets alter gut microbiota composition in mice, suggesting that these changes may be related to gut dysbiosis [417], although other factors may also be involved. The development of MGD has been associated with dyslipidemia in a diet-induced obesity mouse model [418]. In addition to diet, aging-dependent changes in intestinal microbiome composition may be connected to severity of dry eye signs in C57BL/6 male mice [419]. There is as yet no consensus for which specific gut bacteria in animal studies fully correlate with clinical

**Table 4**

The relationship between the gut microbiome and ocular surface diseases.

Condition	Relationship with the gut microbiome (GM)
<b>Blepharitis</b>	<ul style="list-style-type: none"> <li>- Ocular microbiota are strongly related with the onset and evolution of blepharitis [103,404,405]</li> <li>- Higher rate of <i>H. pylori</i> carriage in the stomach of patients with blepharitis vs controls [406]</li> </ul>
<b>Auto-immune scleritis, episcleritis and keratitis</b>	<ul style="list-style-type: none"> <li>- Scleritis or episcleritis are well known complications of inflammatory bowel diseases [407]</li> <li>- These 3 auto-immune conditions are also complications of RA, SLE and other rheumatologic auto-immune, all of them being impacted by GM dysbiosis (see above)</li> </ul>
<b>Infectious conjunctivitis and keratitis</b>	<ul style="list-style-type: none"> <li>- GM modifications (more Proteobacteria and less Firmicutes) in patients suffering of fungal keratitis (FK) versus healthy matched controls [408]</li> <li>- naturally resistant mice to <i>Pseudomonas aeruginosa</i> keratitis can develop corneal infection when grown in germ free mice [409]</li> <li>- Topical application of LPS (from gram-negative bacteria wall) in mice eyes induces increase inflammatory biomarkers in both cornea and conjunctiva, and this can be worsened by antibiotic-induced gut dysbiosis [410]</li> <li>- No specific literature about GM &amp; trachoma</li> <li>- No specific literature about GM &amp; viral keratitis and conjunctivitis</li> <li>- No specific literature about GM &amp; acanthamoeba keratitis</li> <li>- No specific literature about GM &amp; allergic conjunctivitis</li> </ul>
<b>Allergic conjunctivitis and keratitis</b>	
<b>Dry eye disease</b>	<p><b>Clinical evidence</b></p> <ul style="list-style-type: none"> <li>- GM diversity is reproducibly different between SS-related DED and control participants, but also with non-SS DED patients (reviewed in Refs. [364,411])</li> <li>- Correlation between Clostridium levels in the GM and positivity to auto-antibodies against La/SSB in the serum of SS patients [412]</li> <li>- Correlation between Prevotella levels in GM and tear secretion in SS-related DED patients [364]</li> <li>- Compared to primary SS, GM has been found very similar in patients with SLE, a common cause of secondary SS [412]</li> <li>- Improvements of tear breakup time and/or Schirmer score after oral probiotics and/or components described as having anti-oxidant and anti-inflammatory properties (fish oil, lactoferrin, zinc, vitamin C, lutein, vitamin E, <math>\gamma</math>-aminobutanoic acid) (reviewed in Ref. [369])</li> </ul> <p><b>Experimental evidence</b></p> <ul style="list-style-type: none"> <li>- Antibiotic-induced dysbiosis in mice increases susceptibility to desiccating stress [413]</li> <li>- Absence of GM (germ-free conditions) increases ocular surface inflammation in experimental dry conditions, while restoration of GM (fecal transplantation) improves experimental DED [414,415]</li> <li>- Systemic injection of the outer membrane protein A of <i>E. coli</i> in the Harderian and salivary glands induces inflammation in these secretory glands and autoantibodies SSA/Ro and SSB/La, typical of SS [416]</li> <li>- Topical application of probiotics or short chain fatty acids on the eye can improve experimental DED</li> </ul>

RA = rheumatoid arthritis, SLE = systemic lupus erythematosus, GM = gut microbiome, LPS = lipopolysaccharide, SS = Sjogren syndrome, DED = dry eye disease.

disease.

Human clinical studies have shown results comparable to animals regarding the influence of gut microbiota on dry eye disease [364,412, 413,420]. Although some discrepancies exist among these studies, they have generally found parallel correlations between clinical severity of dry eye parameters and gut microbiota, especially in individuals with Sjögren syndrome [364,411,413,420,421]. People with dry eye disease without any autoimmune etiology showed gut microbiome compositional changes that lay somewhere in between those seen in Sjögren syndrome and controls [364].

Serotonin serves as an ocular surface neuromediator [422], and is dependent on the homeostasis of the gut microbiome. Almost all serotonin produced in the human body is synthesized in the gut, more precisely by enteroendocrine cells, upon modulation by the short chain fatty acids and secondary bile acids produced by spore-forming Clostridiales, some other bacteria and some fungi (*Candida* sp.) [411]. Given the acknowledged role of corneal nerves in the definition [423] and pathogenesis of dry eye disease [422,424], neurotrophic keratopathy [425], and corneal aging [426,427], improving ocular surface innervation by restoring gut microbiome homeostasis could be a therapeutic option to improve signs and symptoms of ocular surface disease; research is required to investigate this potential application.

Fecal microbial transplantation in germ-free CD25 knockout mice (a spontaneous dry eye disease model) normalizes epithelial staining and goblet cell density [415]. A similar observation has been made in germ-free C57BL/6J mice, in which goblet cell density is reduced, but restored after fecal microbial transplant [414].

Changes to gut commensals have been linked to increased susceptibility to bacterial and fungal keratitis [408,409,428,429]. Whether gut dysbiosis plays a role in other types of keratitis is still unclear.

Further studies are needed to characterize the mechanisms responsible for other ocular surface disease associations.

### 3.9.4. Modulation of the gut microbiome to improve ocular surface disease

Researchers have investigated modulating the gut microbiome as a therapeutic strategy to improve ocular inflammatory diseases, including

those affecting the ocular surface. In general, there are five main approaches [430]: targeting causative bacteria by using certain antibiotics, increasing consumption of dietary components that support beneficial bacteria by using prebiotics, administering live bacterial strains that can restore immune homeostasis by. Using probiotics, designing and delivering analogs of beneficial bacteria to emulate their effects (by using postbiotics, or replacing the entire gut microbiome population with that from a healthy donor by using fecal microbial transplant). Prebiotics and postbiotics have been studied in one or more subtypes of ocular surface disease. Postbiotics have recently been tested as oral supplement in an animal model of dry eye disease [431] and a clinical trial on fecal microbial transplantation in patients with Sjögren syndrome adds clues to the rationale of this strategy [432].

**3.9.4.1. Prebiotics.** Administration of prebiotics in isolation to support the health-promoting bacteria in the gut has been investigated in a single randomized controlled, double-masked trial of hydrogen gas-producing milk compared to a beverage with similar flavor, texture and taste in individuals who frequently used visual display terminals [433]. After three weeks, those consuming the test milk had a greater increase in tear breakup time compared to those in the placebo group, although the difference was primarily driven by a reduction in tear breakup time in the placebo group rather than an increase in the test group [433].

**3.9.4.2. Probiotics.** A more commonly studied approach is to administer probiotics with or without prebiotic additives to support the health of the gut microbiome. A systematic review and meta-analysis concluded that probiotic treatment leads to significant improvements in ocular symptoms associated with allergies, though the authors acknowledged a high degree of heterogeneity [434]. Two clinical trials, one open-label and the other a randomised, double-masked, controlled-trial in patients with allergic conjunctivitis [435] included a conjunctival allergen challenge and treatment with daily oral consumption of mandarin orange yogurt for two to three weeks demonstrated improved ocular

redness, chemosis and itching symptoms. Another double-masked, placebo-controlled, parallel, randomized clinical trial found improvements in quality of life, but no gut microbiome changes or inflammatory marker benefits, in rhinoconjunctivitis patients treated with probiotics for eight weeks [436]. Hydrolyzed casein formula, which consists of probiotic *Lactobacillus rhamnosus* GG, has been reported to reduce the occurrence of allergic manifestations (including rhinoconjunctivitis) in children with cow's milk allergy [357,437]. Interestingly, there was a significantly lower incidence of conjunctivitis in infants of mothers who received the probiotic administration of *Lactobacillus fermentum* CECT5716 (Lc40) [438], but a systematic review found no significant difference in terms of prevention of rhinoconjunctivitis in childhood supplementation with probiotics [439]. Additionally, antibiotic-induced gut dysbiosis has significant long-term effects on corneal development [440]. These impairments in corneal development were reversed with the use of probiotics and fecal microbial transplantation, which strengthened the perceived association between gut microbiota and corneal development [440].

Probiotic use has also been investigated in small preclinical and clinical studies of dry eye disease. *Enterococcus faecium*, a probiotic [441], combined with other prebiotics and vitamins, maintained tear secretion in a rat model of dry eye disease and improved corneal staining, tear breakup time and subjective symptoms relative to baseline in dry eye patients [201]. These findings are supported by other pilot studies that reported that a combination of prebiotics and probiotics for 28–30 days (dominated mostly by *Lactobacillus* and/or *Bifidobacterium*) yielded greater tear production and tear stability of dry eye patients relative to a control group treated only with artificial tears [442,443]. The literature lacks reports of clinical trials involving patients with Sjögren syndrome; however, positive results following probiotic supplementation have been found in a few studies using mouse models of autoimmune dry eye disease [444–446]. All studies used IRT5 probiotics, which combine five known probiotic species: *Lactobacillus casei*, *Lactobacillus acidophilus*, *Lactobacillus reuteri*, *Bifidobacterium bifidum*, and *Streptococcus thermophilus*. Murine tear production and often corneal staining were improved following IRT5 supplementation [444–446]. One study also reported improvement in the murine lacrimal gland histopathology score [444], but no changes were found in goblet cell density [446]. Recently, a study assessing a combination of pre- and postbiotics administered orally showed a significant improvement in signs, compared to placebo, over a four-month treatment period and one extra-month of follow-up [447].

Literature documenting probiotic use in other ocular surface diseases is scarce, but the studies that have been performed do not show significant effects. A study of Lab4 probiotics (two strains each of *Lactobacillus* and *Bifidobacterium* species) in a mouse model of Graves' disease [448] found that Lab4 led to greater amounts of orbital fat in the test group compared to the control group. Another study of IRT5 probiotics following corneal transplantation in BALB/c mice concluded that IRT5 did not prolong graft survival, suggesting that probiotic use has little effect on alloimmunity [444]. Additional work is needed in randomized, controlled clinical trials with adequate sample sizes before more definitive conclusions surrounding safety and efficacy can be reached.

**3.9.4.3. Vitamins and minerals.** Dietary supplementation with vitamins and highly nutritional foods has also been reported to positively impact the gut microbiome and ophthalmic diseases [72,449]. Whilst vitamin D supplementation increases the overall diversity of gut microbiota [450] and a study has shown that oral vitamin D can improve dry eye disease symptoms after two months of supplementation compared to baseline [287], no studies have examined whether changes to the gut microbiome are correlated with this improvement. To date, supplementation of the diet with vitamin C, selenium, lactoferrin, curcumin and flavonoids have all been shown to improve gut health by altering the gut microbiota [451–455]. It is known that these nutritional supplements

can be beneficial in reducing symptoms of dry eye disease [72]. However, a systematic review and meta-analysis on the effects of flavonoid supplementation on ocular disorders found a minimal non-significant treatment effect on dry eye disease [456].

In summary, there is limited understanding of the relevant pathophysiological mechanisms associated with the gut microbiome and the ocular surface. The field of modulating the gut microbiome through nutritional changes as an intervention to treat ocular surface disease is also in its infancy. Though encouraging results have been documented in preclinical animal models, translating these findings into human patients may prove challenging due to the natural inter-individual heterogeneity in diet, environment, genetics, disease severity and other lifestyle factors.

#### 4. Systemic disease influenced by nutrition and its impact on the ocular surface

Many systemic disorders are affected by diet and nutrition. Moreover, systemic disorders may themselves further affect the body's uptake, processing and distribution of nutrients [457,458]. Metabolic disorders are a broad group of disorders in which the body's processing and distribution of macronutrients is negatively altered. They can be inherited or acquired during life. For some, such as type 2 diabetes and hyperlipidemia, diet is an important etiological factor [458]. Cardiovascular disease and chronic kidney disease can result both directly as a complication of metabolic disease, as well as independently as a factor of diet, with downstream effects on the ocular surface [459]. Gastrointestinal disorders can lead to problems with the uptake of nutrients and similarly, these disorders may be exacerbated by poor diet [457].

Many metabolic and gastrointestinal disorders have been associated with an increased risk of ocular surface disease [111,460,461]. Although the exact pathophysiological pathways leading to comorbid ocular surface disease are often unknown for these disorders, several general mechanisms may underlie the association. First, the disorders may lead to deficiencies of micro- and macro-nutrients that are important in maintaining ocular surface health. Second, changes in the gut microbiome associated with these disorders may also lead to alterations at the ocular surface (see Section 3.9). Third, medications used to treat these disorders have been negatively associated with ocular surface health, such as decreased lacrimal gland function which has been associated with the use of anticholinergic medications, and increased dryness symptoms, with use of proton pump inhibitors [284,462]. The role of medications on ocular surface health is further discussed in the *TFOS Lifestyle: Impact of elective medications and procedures on the ocular surface* report [102]. Finally, gastrointestinal and metabolic disorders are associated with an increased risk of depression and anxiety [463–465], which may increase pain sensitivity, particularly to exteroceptive stimuli, leading to an increased experience of symptoms, including those from the ocular surface [466,467]. The subsequent sections discuss each of these disorders and their known associations with ocular surface disease.

##### 4.1. Metabolic disorders

###### 4.1.1. Obesity

The World Health Organisation estimated that in 2016 there were 650 million obese adults in the world, about 13% of the population at the time [468]. The National Institute of Health defines obesity as a BMI of  $\geq 30$  kg/m<sup>2</sup>. Several chronic illnesses including type 2 diabetes and cardiovascular diseases are well known complications of obesity [469]. The International Diabetes Federation estimated that 552 million people will suffer from diabetes by the year 2030 [470]. A highly effective long-term treatment option for reversing obesity-associated type 2 diabetes is bariatric surgery [471]. Reportedly, bariatric surgery results in remission of type 2 diabetes in  $\geq 70\%$  of patients and prevents the development of diabetes in obese patients [472–474].



Obesity has been associated with various eye conditions including cataract, age-related maculopathy, diabetic retinopathy, glaucoma and ocular surface diseases, such as floppy eyelid syndrome, blepharoptosis and dry eye disease [475–477]. Some of these effects of obesity and BMI on the ocular surface are discussed in this section. The effect of bariatric surgery on the ocular surface is considered by the *TFOS Lifestyle: Impact of elective medications and procedures on the ocular surface* report [102], in the systematic review component of this paper in Section 6, and discussed briefly in Section 4.1.1.1.

The characteristic feature of floppy eyelid syndrome is hyperelasticity of the upper eyelids [478]. Many patients with floppy eyelid syndrome are obese and nearly all have obstructive sleep apnea [479]. In floppy eyelid syndrome, the upper eyelid tends to evert, especially when the patient sleeps on one side and, as a consequence, the palpebral conjunctiva is exposed to the pillow. In patients suffering from floppy eyelid syndrome and obstructive sleep apnea, ocular signs and symptoms may improve following long-term adherence to positive airway pressure. In refractory cases, a significant improvement can be observed after corrective surgery for eyelid laxity [480–483].

Ptosis, also known as blepharoptosis, is defined as an abnormally low-lying upper eyelid margin with the eye in primary gaze. Blepharoptosis can affect one or both eyes and can be present at birth (congenital) or appear later in life (acquired) [484,485]. As shown in several case reports, general obesity is accompanied by blepharoptosis in congenital or genetic syndromes [478,486,487]. Patients with acquired aponeurogenic blepharoptosis more often have decreased aqueous tear production [488]. In a representative Korean population, obesity parameters such as BMI, waist circumference and percentage body fat were found to be potential risk factors for age-related blepharoptosis [154].

There is a lack of studies specifically investigating the effect of obesity on the tear film, independent of type 2 diabetes [489]. A large population-based cohort study found a higher BMI to be highly significantly associated with less dry eye disease, also after correction for multiple comorbidities and demographic factors [111]. MGD-related tear film instability has been reported in those with polycystic ovarian syndrome and high BMI [490].

**4.1.1.1. Bariatric surgery.** Bariatric surgery is routinely performed in obese patients to achieve sustained weight loss [491]. There has been a growing popularity in such procedures, which has stimulated increased interest in their effects on the eye.

Bariatric surgeries can be categorized as restrictive, malabsorptive, or mixed [492]. Restrictive procedures reduce the functional and/or anatomical size of the stomach with the use of a constricting gastric band or by removing a longitudinal segment of the stomach itself [493]. These procedures, known as the adjustable gastric band (commonly termed ‘lap band’ when performed laparoscopically) or gastric sleeve, reduce the capacity of the stomach, which predisposes to a non-balanced diet, and diminishes absorption of certain vitamins and minerals [493]. Malabsorptive procedures bypass a portion of the stomach and/or intestines to iatrogenically limit absorption, again predisposing to deficiencies in many vitamins and minerals [493]. Two common procedures that employ both malabsorptive and restrictive mechanisms are Roux-en-Y gastric bypass and biliopancreatic diversion with duodenal switch. These procedures that induce malabsorption are more often associated with ocular complications than those of the restrictive variety [493,494].

Ocular complications following bariatric surgery primarily relate to deficiencies in specific nutrients: vitamin A, vitamin E, vitamin B<sub>1</sub>, and copper [495]. Deficiency in vitamin A is the predominant source of ocular surface complications, including conjunctival xerosis with Bitot’s spots, corneal xerosis, corneal ulceration, and keratomalacia [493,496]. It can also induce nyctalopia, which may be the first clinical presentation of vitamin A deficiency [493].

The epidemiology of vitamin A deficiency in patients after bariatric

surgery is not well established. The results of several small studies are inconsistent, and the deficiency depends on the type of bariatric surgery [497]. For mixed restrictive and malabsorptive procedures, vitamin A deficiency has been reported in 35% of patients 6 weeks after Roux en Y gastric bypass, and in 18% of patients after one year [498]. In another study of patients who had undergone Roux-en-Y gastric bypass [499], patients reported ocular dryness and night vision changes at rates higher than were detected for clinically significant vitamin A deficiency. These findings suggest that symptoms typically associated with vitamin A deficiency may onset prior to clinically measurable vitamin A deficiency, which warrants further investigation into their origin and the threshold values used for diagnosis of vitamin A deficiency.

For biliopancreatic diversion, another mixed restrictive and malabsorptive bariatric surgery, the prevalence of vitamin A deficiency seems to be higher. The prevalence of vitamin A deficiency has been reported at 52% for patients 1 year after surgery and 69% for patients 4 years after surgery [500]. There is a progressive increase in the incidence and severity of hypovitaminemia A, D, and K with time after biliopancreatic diversion and duodenal switch [500]. Many of these patients reported compliance with vitamin supplements, emphasizing a possible need for parenteral supplementation of vitamin A in certain cases. In healthy persons who consume an adequate diet, vitamin A reserves are sufficient to meet the body’s demands for at least 6 months [493], which may explain why ocular surface complications can appear months to years after surgery if little or no supplementation occurs.

Regarding restrictive bariatric surgeries, one study found no statistically significant difference in the prevalence of vitamin A deficiency between the adjustable gastric banding group and the control group, which might indicate that there is no increase in the risk of vitamin A deficiency and ocular surface disease secondary to restrictive bariatric surgeries [497].

Two cases of sterile corneal perforation secondary to vitamin A deficiency have been reported after biliopancreatic diversion with duodenal switch, suggesting a need to examine the ocular surface of patients who have undergone bariatric surgery in order to promptly recognize the signs of vitamin A deficiency and avoid serious sight-threatening complications [108]. Corneal melt after refractive surgery in a patient who underwent prior bariatric surgery has been reported [501]. A study of 29 participants with obesity observed for one year following Roux-en-Y gastric bypass surgery found no difference in tear meniscus height, non-invasive tear breakup time, or meibomian gland morphology [502].

An evaluation of 20 patients with obesity prior to and 12 months after bariatric surgery, and 22 age-matched healthy controls at baseline only [503], found that obesity was associated with decreased corneal nerve branch density and corneal nerve fiber length. However, these parameters improved by 12 months after surgery. Further work is needed to understand the mechanisms that underlie changes in corneal nerves in obesity and how bariatric surgery might result in improved corneal nerve regeneration. Two additional studies have reported no correlation between bariatric surgery and clinical signs of ocular surface disease [504,505]. As popularity of these surgeries continues to grow, there is an increasing demand for scientists and clinicians to better understand the ocular risks and benefits of bariatric surgery.

#### 4.1.2. Dyslipidemia and hypertension

The association between nutrition and systemic diseases such as hypertension, hyperglycemia and hypercholesterolemia are well known. A population-based cohort study of 79,866 individuals in the Netherlands found that measured hypertension and increasing blood pressure, but not cholesterol levels or hypercholesterolemia, were associated with less dry eye disease (corrected for age, sex, BMI and 48 co-morbidities) [111]. An earlier systematic review included four case-control studies that collectively analyzed 342 individuals with MGD, and reported a positive correlation between dyslipidemia and MGD [506]. However, another prior systematic review included five

studies that evaluated outcomes in 809 people [418] and concluded that the relationship between plasma lipid status and MGD was unclear [418]. One cross-sectional prevalence survey on 25,444 men from the USA showed a significant correlation between dry eye disease and self-reported hypertension (odds ratio: 1.28; CI, 1.12–1.45) [507], while the Dry Eye Assessment and Management study that included 535 patients with dry eye from 27 centers found that hypertension and hyperglycemia were not associated with increasing dry eye signs [508]. In a systematic review and meta-analysis of xanthelasma palpebrarum that included 15 case control studies that collectively evaluated 854 people, there was a significant correlation with higher serum levels of total cholesterol and the presence of xanthelasma [509].

Dyslipidemia and MGD, xanthelasma palpebrarum and cholesterol are therefore likely correlated. There are still no studies on the effect of managing cholesterol to prevent or treat MGD. Whether or not hypertension or hyperglycemia is associated with dry eye is still controversial and needs further investigation. It is important for future studies that hypertension is measured and not assessed by questionnaires, as self-reported hypertension appears to be an unreliable phenotype [111,510].

#### 4.1.3. Metabolic syndrome

For a person to be defined as having metabolic syndrome, they need to have central obesity (defined as waist circumference  $\geq 94$  cm for men and  $\geq 80$  cm for women [511]) as well as two of four additional factors including [512]: raised triglyceride levels:  $\geq 1.7$  mmol/L (150 mg/dL); reduced high density lipoprotein-cholesterol:  $< 1.03$  mmol/L (40 mg/dL) in males and  $< 1.29$  mmol/L (50 mg/dL) in females (or specific treatment for these lipid abnormalities); raised blood pressure (systolic blood pressure  $\geq 130$  or diastolic blood pressure  $\geq 85$  mmHg) (or treatment of previously diagnosed hypertension); raised fasting plasma glucose [ $\geq 5.6$  mmol/L (100 mg/dL)] (or previously diagnosed type 2 diabetes).

Two features have been identified as potential causative factors for metabolic syndrome: insulin resistance and abnormal fat distribution, or central obesity [512]. Importantly, metabolic syndrome can have important health implications, including cardiovascular disease and type 2 diabetes [512].

When ocular surface disease was evaluated in a group with metabolic syndrome ( $n = 64$ ), tear osmolarity was higher, dryness symptoms by OSDI were higher, and Schirmer scores and tear breakup time were lower compared to the control group ( $n = 55$ ) [513]. Metabolic syndrome has also been shown to be associated with peripheral neuropathy and reduced corneal nerve parameters in those with both diabetes and metabolic syndrome compared to those with diabetes only [514]. In the same study, the more severe changes in the metabolic syndrome group indicated that the observed neuropathic changes may be due to reduced sodium channel permeability and sodium-potassium pump function [514].

#### 4.1.4. Pre-diabetes and type 2 diabetes

Type 2 diabetes, previously referred to as non-insulin dependent diabetes mellitus or adult-onset diabetes, accounts for about 90–95% of diabetes cases. Although several genetic factors are involved, these are amplified by lifestyle (obesity, lack of exercise) and environmental factors [515]. The onset of type 2 diabetes is believed to occur, on average, seven years before confirmation of a clinical diagnosis [516]. By this time, the presence of micro and macrovascular complications is not uncommon [517]. Impaired fasting glucose or impaired glucose tolerance is known as pre-diabetes. The risk of developing diabetes in the pre-diabetes population increases from 30% over 4 years to 70% over 30 years [518]. Lifestyle adjustments or daily metformin intervention can delay the onset of diabetes in these individuals [518,519].

The whole eye is affected in diabetes with sub-clinical as well as the potential for severe clinical complications. The most common sight-threatening ocular complication of diabetes is diabetic retinopathy. In a population-based cohort study of 79,866 individuals, the presence of a

diagnosis of diabetes was found to have a moderate but significantly increased risk of dry eye disease (odds ratio: 1.3 (CI: 1.1–1.5)) [111]. However, no clear link between dry eye and HbA1c or glucose levels was found within both diabetic patients and non-diabetics. Also, duration of diabetes was not associated with increased risk of dry eye.

Blinking and correct eyelid positioning play an essential role in maintaining corneal hydration. Blink rates in individuals with type 2 diabetes have been reported to be either decreased (attributed to a decrease in corneal sensitivity in the same cohort) [520] or increased (attributed to a reduced tear thinning time in the same cohort) [521]. Differences in study designs and cohorts may account for the conflicting literature, and moreover, blink rates are notoriously difficult to measure in studies. Both findings and their explanations are plausible and further investigation is needed to determine if confounders such as age, sex and study location may explain this discrepancy and better characterize this association.

While xanthelasma and floppy eyelid syndrome are directly attributed to other systemic conditions, both have a strong association with type 2 diabetes [522,523]. More serious complications of the eyelids have been reported in diabetes including rare but severe, life-threatening infections of the lids and surrounding tissues, including mucormycosis [524] and necrotizing fasciitis [525].

MGD is more common in individuals with type 2 diabetes [526,527]. A large population-based study in Spain involving 937 individuals found that diabetes increased the risk of MGD, particularly asymptomatic MGD [528]. Individuals with type 2 diabetes have been reported to have significantly higher meibography scores indicative of gland dropout [529], more partial glands [526,529] and a resultant higher lid margin abnormality score [529]. Assessment of rete ridges with confocal microscopy has also shown changes in the gland structure with decreased density and enlargement of individual rete ridges [530,531]. Meibum lipid composition is also different in those with type 2 diabetes with lower expression of triacylglycerols, wax esters and (O-acyl)-omega-hydroxy fatty acids (OAHFA), and higher expression of cholesteryl esters and phospholipids [532].

*Demodex folliculorum* is more prevalent on the eyelashes of individuals with type 2 diabetes compared to age-matched controls [533, 534], which has been attributed to general peripheral vascular insufficiency and immunocompromise in type 2 diabetes. Given the association with *Demodex*, it would be expected that individuals with type 2 diabetes are more prone to blepharitis, and this is often stated [535]; however, a population-based cohort study that included 3284 participants aged over 60-years-old found no association between diabetes and blepharitis [536] while another large scale case control study of 10,093 patients with blepharitis and 40,372 matched controls found that while blepharitis was associated with the development of metabolic syndrome, it was not associated with diabetes [537]. A systematic review that considered the evidence from three studies evaluating the epidemiology of ocular *Demodex* found an increase in ocular demodicosis in the presence of diabetes in all three studies [538].

Given that one of the most common complications in type 2 diabetes is microvascular damage, it is unsurprising that there is much evidence of microvascular abnormalities in the conjunctiva of patients with type 2 diabetes. Blood vessel dilation [539,540], reduced and uneven distribution [539–541], increased tortuosity of micro-vessels [542], and altered conjunctival micro-vessel flow velocities [539,543] have all been described in individuals with type 2 diabetes compared to controls. Increased limbal and bulbar hyperemia have also been reported [544].

There are other changes to the conjunctival surface in type 2 diabetes. Goblet cell loss and increased conjunctival squamous cell metaplasia has been described in type 2 diabetes compared to controls, as well as associations between goblet cell loss and the level of glycemic control and peripheral neuropathy status [545]. Pinguecula has been found to be more common and more severe in type 2 diabetes [546], which was attributed to other factors related to type 2 diabetes, such as accumulation of advanced glycation end products, microvascular

damage and dry eye disease.

Numerous studies have demonstrated alterations to the microbiome of the conjunctiva in type 2 diabetes, with a more complex microbiome than observed in controls, and that may respond differently to antibiotics [547]. Higher rates of *Staphylococcus aureus* have been isolated [548] and an abundance of *Acinetobacter* were seen compared to healthy individuals [549], which is thought to be related to the effect diabetes has on immune function [550].

Further to the many sub-clinical and clinical changes in individuals with type 2 diabetes, combined with immunocompromise, it is believed that conjunctivitis is also more common in individuals with type 2 diabetes [551,552].

Severity of diabetes is associated with prevalence of dry eye disease [553], although the heterogeneity in diagnostic criteria in various published studies of over two million participants have made it difficult to prove a strong association between diabetes and prevalence of dry eye disease [553]. Patients with type 2 diabetes often experience dryness symptoms [111]. In extreme cases though, apparent tolerance to dryness from poor corneal sensitivity, has led to diabetic neurotrophic keratopathy [554]. Tear stability measured as invasive or non-invasive tear breakup time has been shown to be significantly reduced with poor glycemic control [545]. A systematic review concluded that poor tear function and stability was associated with diabetes [555]. One study reported a decreased presence of the neuropeptides, substance P and calcitonin gene-related peptide, from corneal nerve terminals into tears in response to neurogenic inflammation for type 1, but not type 2, diabetes [556]. Whether these physiological differences translate into clinical signs and symptoms of dry eye disease in diabetes is yet to be determined. Diabetic peripheral neuropathy is believed to be the primary cause of lacrimal gland disruption leading to reduced basal tear production in diabetes [557].

Herpetic eye disease and fungal keratitis have been reported to have a higher prevalence in patients with diabetes [558,559]. Whether or not directly related, corneal basement membrane changes, including accumulation of advanced glycation products, in diabetes, minimize its ability to act as a barrier against infection, and can lead to recurrent epithelial defects [560]. The weakened corneal barrier function has been reported to be associated with higher HbA1c levels [561]. Patients with type 2 diabetes have been shown to be at risk of superficial punctate keratitis, recurrent corneal erosions, persistent epithelial defects and possible endothelial damage [545,562–565].

A meta-analysis of 15 studies involving more than 1500 eyes reported an increase in corneal hysteresis and corneal resistance factor in patients with diabetes [566], although it should be noted that it pooled data of both type 1 and type 2 diabetes patients [566]. Further analysis with a different instrument reported similar findings [567,568] hypothesized to be due to increased corneal viscosity due to glycosylation of corneal proteoglycans and glycosaminoglycans, in those with diabetes [569].

Corneal sensitivity threshold has been shown to be reduced in patients with type 1 and 2 diabetes when measured by both contact and non-contact esthesiometry [555,570–572]. A strong association has been reported between corneal sensitivity, increasing age and poor glycemic control [573]. Unsurprisingly, corneal sensitivity has a well-established correlation with corneal sub-basal nerve plexus in type 2 diabetes [570]. Two large systematic reviews of more than 3000 patients with diabetes (type 1 and 2 combined) identified corneal nerve fiber changes compared to controls, including reduction in nerve fiber density, nerve fiber length, nerve beading density and inferior whorl length [574,575]. The subclinical changes in the corneal nerve plexus are associated with the presence of diabetic peripheral neuropathy [576], suggesting a potential role for corneal confocal microscopy in early detection for timely treatment of neuropathy in at-risk patients. The corneal endothelial changes in type 2 diabetes are still a matter of discussion as some studies have reported increased polymegathism and pleomorphism, while others did not observe differences compared to

control participants [563,577,578].

#### 4.2. Cardiovascular disease

Cardiovascular disease is the cause of death for 17.7 million people worldwide per year [579] and is highly correlated with various aspects of nutrition [580]. Acute myocardial infarction is a late consequence of the disease, while dysfunction of the microcirculation of the body manifests early in the disease [581]. In a population-based cohort study of 79,866 participants, cardiovascular disorders were found to be associated with dry eye disease [111]: specifically, atherosclerosis (odds ratio: 1.79 (CI: 1.37–2.35),  $p < 0.001$ ), thrombosis (odds ratio: 1.37 (CI: 1.12–1.68),  $p = 0.002$ ), heart arrhythmia (odds ratio: 1.53 (CI: 1.42–1.65),  $p < 0.001$ ), and aorta aneurysm (odds ratio: 1.71 (CI: 1.17–2.49) [111].

Given its accessibility, the conjunctival microcirculation has been studied for parameters such as diameter, axial velocity, blood volume flow and wall shear rate [582,583]. Alterations of these variables were noted in cardiovascular disease, in diabetic microvasculopathy [584] and unilateral ischemic stroke [585]. In acute myocardial infarction, lower axial velocity and wall shear rates were found compared to controls [586]. These findings are suggestive of endothelial dysfunction, as well as atherosclerotic changes, contributing to reduced axial velocity in the conjunctival vessels [586]. A reduction in wall shear rate can lead to abnormal vascular wall remodeling and is related to plasma viscosity [587].

#### 4.3. Chronic kidney disease

Chronic kidney disease is characterized by a gradual loss of kidney function over a period greater than three months, accompanied by a decrease in kidney estimated glomerular filtration rate and proteinuria [588]. Chronic kidney disease has been linked to multiple etiologies that are linked to nutrition, including diabetes, hypertension and glomerulonephritis. The severity of the disease can be staged according to the estimated glomerular filtration rate. Stages 3–5 describe the terminal stage of the disease known as chronic renal failure [589], that is treated with hemodialysis. Patients with stages 3–5 will present with anemia, reduced appetite, abnormal calcium and phosphorous metabolism, electrolyte disturbance and acid-based imbalance [589].

Chronic kidney disease affects between 30 and 50% of people with diabetes [590] and can contribute to neurological complications of both the central and peripheral nervous systems [591]. The presence of both diabetes and chronic kidney disease can exacerbate the subsequent peripheral neuropathy [592]. In the cornea, nerve loss has been found to be significantly greater in those with type 2 diabetes and chronic kidney disease compared to those with diabetes alone, with the reduction in corneal nerve parameters associated with the decline in kidney function as well as peripheral neuropathy status [593].

In a study exploring dry eye disease parameters and the tear proteome in 20 patients with non-diabetic stage 3–5 chronic kidney disease undergoing hemodialysis and 10 healthy controls, patients with chronic kidney disease were found to have a higher OSDI score [594]. They were also found to have a lower tear volume with the Schirmer score, a lower tear breakup time and tear meniscus height, and greater meibomian gland dropout [594]. These findings are supported by other studies [595–597]. The tear analysis indicated that the differentially-expressed proteins were involved in lipid metabolism, inflammation and immune responses [594], suggesting that changes in these pathways due to chronic kidney disease may be reflected in the tear film, contributing to the signs and symptoms of dry eye disease. One study also reported a decrease in tear osmolarity following hemodialysis [598].

Patients with chronic kidney disease undergoing hemodialysis have been reported to have increased central corneal thickness and reduced endothelial density, more so in those with elevated urea levels, compared to those not undergoing hemodialysis and healthy controls



[599]. The authors hypothesized that these changes were due to elevated toxins in the blood and therefore the aqueous humor, having a downstream effect on the corneal endothelium [599].

Corneal and conjunctival changes in chronic renal failure may be a result of metastatic calcification and chronic inflammation, and may be a result of the disease that triggered the chronic renal failure, as well as the chronic renal failure itself [600]. Calcium salts are deposited beneath the corneal epithelium as a result of limbal blood flow [600], giving the characteristic band-like keratopathy appearance. An elevated level of calcium phosphate products in the serum has been found in patients with band keratopathy [601]. Treatment involves managing the underlying disease, as well as removing any deposits in symptomatic patients using superficial keratectomy, with or without ethylenediaminetetraacetic acid (EDTA) as a chelating agent [600]. Calcium-phosphate deposits can also be found in the conjunctiva within the interpalpebral region [601], as well as squamous metaplasia as evaluated with impression cytology [602,603].

#### 4.4. Gastrointestinal disease

Nutrition and gastrointestinal function are closely related [604]. The chief purpose of the gut is to digest and absorb nutrients. Chronic gastrointestinal disease therefore can commonly result in malnutrition [604]. This chronic malnutrition can further impair digestive and absorptive function [604]. In a population-based cohort study of 79,866 participants, many gastrointestinal diseases were associated with dry eye [111]: stomach ulcers (odds ratio: 1.68 (CI: 1.52–1.86)  $p < 0.001$ ), Crohn's disease (odds ratio: (CI: 1.51–2.70)  $p < 0.001$ ), ulcerative colitis (odds ratio: 1.61 (CI: 1.29–2.01)  $p < 0.001$ ), celiac disease (odds ratio: 1.66 (CI: 1.27–2.19)  $p < 0.001$ ), lactose intolerance (odds ratio: 1.84 (CI: 0.96–3.54)  $p = 0.07$ ) and diverticulosis (odds ratio: 1.71 (CI: 1.20–2.44)  $p = 0.003$ ) [111].

##### 4.4.1. Inflammatory bowel disease

Inflammatory bowel disease is a chronic immune-mediated systemic disorder which comprises Crohn's disease and ulcerative colitis [605]. Crohn's disease can affect any part of the gastrointestinal tract, while ulcerative colitis affects the large intestines [605]. Inflammatory bowel disease can also manifest outside of the gastrointestinal tract in 5–50% of patients [606], including the musculoskeletal, cutaneous and ocular systems [605]. Approximately 2–5% of patients with inflammatory bowel disease will present with ocular surface manifestations [605], including episcleritis, scleritis and uveitis [605] due to the formation of antigen-antibody complexes that target the ocular tissues [607]. Ocular manifestations are often associated with musculoskeletal manifestations [608]. Episcleritis is associated with ongoing intestinal flare, although it may arise before or after the intestinal manifestations of the disease [605]. Patients with inflammatory bowel disease have also been reported to have thinner corneas [609] and signs and symptoms of dry eye disease [610].

##### 4.4.2. Celiac disease

Celiac disease is an immunologic non-immunoglobulin E-mediated reaction to certain foods, and as such is both a food intolerance and autoimmune disorder [611]. Its prevalence ranges from 0.15% to 2.67%, which varies depending on the study location and whether serologic testing or biopsy was used for diagnosis [611]. It has been defined as a permanent intolerance to gluten which is a storage protein from wheat, barley, spelt and rye [611]. Ingestion of gluten in susceptible individuals causes a chronic inflammatory state of the proximal small intestinal mucosa [611], which is where gluten first encounters the mucosal immune system.

The ocular manifestations of celiac disease may be due to the primary disease, or secondarily due to resultant deficiency in vitamins and minerals such as vitamin A, D and calcium [612]. In a cross-sectional descriptive study of a German hospital database analysis, a total of

272,873 patients with eye conditions were evaluated [607]. The prevalence of ocular complications in 72 individuals with celiac disease was explored in one study [607]. The most common diagnosis was dry eye disease (32%), and the profile of ophthalmological manifestations was considered similar to that seen in inflammatory bowel disease [607]. None of the patients with dry eye disease had vitamin A deficiency [607], suggesting that the dry eye may be autoimmune in origin, rather than secondary to dietary restrictions. In a cross-sectional study of 36 adults with celiac disease and 35 age- and sex-matched healthy controls, patients with celiac disease had reduced corneal endothelial cell density [613] as well as changes to other ocular parameters, such as anterior chamber depth. In a study of young children with celiac disease, a decreased Schirmer score and tear breakup time was reported, relative to controls [614], suggesting a predisposition to dry eye disease from a young age. Similar dry eye results were found in adult cohorts [615], as well as significant squamous metaplasia of the conjunctival epithelial cells and reduced goblet cell density [94], supporting the existence of ocular surface disease in celiac disease.

While there are case reports on the impact of a gluten free diet on ocular surface complications [616], there are no higher levels of evidence available. As discussed in Section 3.1.1.4, reduction of gluten from the diet in affected individuals might reduce ocular surface inflammation due to overall reduced disease severity [94].

##### 4.4.3. Irritable bowel syndrome

Irritable bowel syndrome is a functional bowel disorder, and therefore part of a spectrum of chronic gastrointestinal disorders characterized by abdominal pain, bloating, distention and/or bowel habit abnormalities such as constipation and diarrhea [617]. Diagnosis requires symptoms to have commenced at least six months prior, and to be present for at least the previous three months [617]. A meta-analysis found a prevalence of 11.2% (CI: 9.8%–12.8%) [618], depending on the country and diagnostic criteria used. The prevalence was higher in women (odds ratio: 1.67; CI: 1.53–1.82) and lower for people over the age of 50 years (odds ratio: 0.75; CI: 0.62–0.92) [618]. The pathophysiology of irritable bowel syndrome is poorly understood, although it is thought to be due to inflammation, with increased numbers of inflammatory cells found in the colonic mucosa of patients with the condition [619]. Treatment is based on symptom type and severity and includes lifestyle modifications such as exercise, stress reduction and attention to impaired sleep [617]. In terms of dietary management, dietary fiber is key, and in some cases, dietary restriction of gluten [617]. Dietary restriction might have a role in improving symptoms of irritable bowel syndrome [620].

In a population-based cross-sectional association study of 3824 women from the Twins UK cohort, aged 20–87 years, irritable bowel syndrome had one of the highest effect sizes for dry eye disease ( $p < 0.005$ ), with a prevalence of 20% and an odds ratio of 2.24 (CI: 1.76–2.85) [461]. This strong association was similarly reported in a population-based cohort study of 79,866 participants [111]. In two cross-sectional studies in the Netherlands of 648 patients with dry eye disease, irritable bowel syndrome was associated with relatively few signs but with severe symptomatology in dry eye disease [621,622].

Ocular manifestations have been linked to the underlying inflammatory pathogenesis. In a case-control study of 95 patients with irritable bowel syndrome and 276 healthy controls, the former were more symptomatic for dry eye disease, and more likely to have a reduced tear breakup time and Schirmer score [623]. These findings have been corroborated by other cohort [624–626] and epidemiological studies [111], although other studies have not found an association [508].

A large twin study found greater within-twin correlation for monozygotic twin pairs than dizygotic twin pairs, as well as greater cross-twin cross-trait correlations, suggesting shared genetic factors between irritable bowel syndrome, dry eye disease and other chronic pain syndromes [627].



#### 4.5. Cancer

Many cancers, such as oesophageal, stomach, colorectal (or bowel) and liver cancer have a close association to nutrition and the gastrointestinal system [628,629]. Cancer has multiple effects on the body beyond the local tumor site, such as weight loss, decreased resistance to infection, physical compression on neighboring blood vessels and nerves, and metastasis. The ocular surface, having a rich nerve supply, vasculature in the choroid and comprising numerous different cell types, is therefore theoretically vulnerable to all these effects. There is evidence of both metastasis and infection related to the cancers listed above influencing the ocular surface.

While metastasis of cancer to the eye is uncommon, and even more so for gastrointestinal cancers [630], there are numerous reports of metastases impacting the ocular surface. Eyelid tumor metastasis has been reported secondary to esophageal [631] and rectal cancer [632], presenting as large mass on the upper lid, in one case first being misdiagnosed as a chalazion [631]. Iris metastases have been reported secondary to esophageal cancer [633,634], presenting as a visible iris mass, and in some cases, also hyphema, discomfort, conjunctival hyperemia, and cells in the anterior chamber. Scleral metastasis has been reported secondary to esophageal cancer [635], presenting as ocular swelling, conjunctival hyperemia and excessive tearing. While not part of the ocular surface, orbital metastases reported from colon [636–640], rectal [641,642], esophageal [643] and liver [644] cancers have presented with ocular surface symptoms including proptosis, ptosis, eyelid edema, conjunctival hyperemia, eye pain, and a fixed pupil, as well as yellow, jaundiced conjunctiva in the case of liver cancer metastasis. A jaundiced conjunctiva has long been recognized as a sign of a variety of liver diseases including cancer [645].

In addition to metastasis, infection is also a risk for individuals with cancer. Rare ocular infections, panophthalmitis (due to *Clostridium Septicum*) and endophthalmitis (due to *Candida albicans*) have been reported in individuals with colon [646] and esophageal [647] cancer respectively, untreated by chemotherapy.

More subtle, sub-clinical effects of gastrointestinal cancers on the ocular surface have also been revealed in studies investigating the eye as a biomarker for systemic conditions. Corneal nerve fiber length, density and branch density were all found to be reduced in individuals with upper gastrointestinal cancer prior to commencement of chemotherapy compared to age-matched controls [648]. This was thought to be a reflection of systemic peripheral neuropathy associated with cancer but there was no corresponding reduction in corneal sensitivity [648]. Individuals with colon cancer have also been reported to have higher rates of the tear protein lacryglobin, a small protein of unknown function [649].

These sub-clinical signs, while of interest to researchers, are not of immediate clinical relevance. Both the metastases and infections described here are of clinical importance, but are rare, reflected by the scant evidence available, all in the form of case reports. Most potential impacts of cancer on the ocular surface are likely to be overshadowed by the side-effects of chemotherapy. However, in some of the cases described here, the ocular surface and adnexa signs were the presenting complaint, leading to the investigation and discovery of the primary gastrointestinal cancer. Therefore, eyecare practitioners should be cognizant of this as a possibility.

#### 5. Epigenetics

Epigenetic modifications are reversible yet stable, modifications to DNA that can be inherited through generations and mutually influence, and be influenced by environment, behavior, aging, inflammation, drugs, oxidative stress, seasonal changes, circadian rhythm and nutrition, among other stressors [650].

Nutrition influences epigenetic modifications in a hierarchy of levels: from acting as a source of metabolites and co-enzymes, vitamins and

cations, and methyl donors necessary for DNA and histone methylation; to providing bioactive food components leading directly to DNA methylation and histone modification; to affecting systemic metabolism that modifies local cellular environments and hence epigenetic patterning [651]. Homocysteine is critical for regulating key epigenetic mechanisms, and hence impaired homocysteine metabolism can lead to increased free radicals, oxidative stress and systemic inflammation [652]. Methionine and choline in the diet influence homocysteine plasma levels, while vitamin status (folate, vitamins B<sub>2</sub>, B<sub>6</sub>, B<sub>9</sub>, B<sub>12</sub>) influences the relation between methionine and homocysteinemia [652].

Accumulating evidence indicates that the etiology of ocular surface inflammatory disorders lies, in part, in deleterious epigenetic modification [650]. Drawing together inflammation, immunity, epigenetics, and nutrition can provide a deeper understanding of the development and treatment of ocular surface disorders.

Emerging evidence suggests epigenetic mechanisms are important in the pathophysiology of ocular surface disease [653]. There is evidence suggesting that epigenetic modification plays a key role in the development of pterygium [653–655], but since environmental factors (ultraviolet irradiation) rather than nutrition appear to play the dominant role, this is beyond the scope of this section.

The role of epigenetics in keratitis is not well explored. However, it is known that the innate immune response plays a pivotal role in ocular surface inflammation with toll-like receptors influencing the innate response through decreased histone deacetylation leading to increased production of inflammatory interleukins and tumor necrosis factor that are implicated in development of microbial keratitis [653]. The contribution of nutrition and epigenetic modification to keratitis can be inferred from studies that suggest type 2 diabetes-associated microbial keratitis is driven, in part, by epigenetic modifications (directly or indirectly as a result of nutritionally driven disease) [656].

Other than oral vitamin B<sub>1</sub> and cobalamin (endogenous B<sub>12</sub>) relieving dry eye symptoms [657] and the fact that cobalamin serves as a cofactor in the conversion of homocysteine to methionine (and hence is implicated epigenetically [657] in regulating DNA methylation [652]), there remains very little evidence at this time of epigenetic involvement in dry eye disease.

### 6. Systematic review and meta-analysis: the effect(s) of different forms of intentional food restriction on the ocular surface

#### 6.1. Introduction

Intentional food restriction may occur during religious fasting, in different forms of diets, following surgical procedures and in certain medical conditions [504,613,658,659]. Despite increasing general interest in food-restricted diets [660], their effects on ocular surface health remain unclear. The aim of this systematic review was to investigate the safety and impact of different forms of intentional food restrictions on the ocular surface.

#### 6.2. Methods

This review was prospectively registered on PROSPERO (CRD42022297045) and reported according to the Preferred Reporting Items for Systematic Reviews and Meta Analyses (PRISMA) statement [661].

##### 6.2.1. Search method

PubMed and Ovid Embase electronic databases were searched from inception to December 9, 2021. Complete search strategies are provided in Supplement I. In addition, the reference lists of included studies were screened to identify any potential studies that were not captured in the initial searches.

### 6.2.2. Eligibility criteria

Study designs eligible for inclusion were randomized controlled trials, pseudo-randomized controlled trials, non-randomized intervention studies, cohort studies, cross-sectional studies, case-control studies and pre-post intervention studies. The studies that were included assessed the efficacy and/or safety of any form of intentional food restriction on a parameter (symptom or sign) relevant to ocular surface health, relative to no intentional food restriction, including a standard (e.g., normal diet) or control (e.g., sham surgery or placebo diet) condition. Only full-text studies published in English were included; conference abstracts and animal studies were ineligible. The types of 'intentional food restriction' eligible for inclusion were total caloric restriction, fat-restricted diet, sodium-restricted diet, gluten-free diet, lactose-free diet, protein-restricted diet, vitamin-restricted diet, carbohydrate-restricted diet, Palaeolithic diet, anti-inflammatory diet, religious meat restriction diet (e.g., kosher and halal), intermittent fasting, fad diets, ketogenic diet, vegetarian and vegan diets, food elimination diets, religious fasting, intermittent food restriction, surgical interventions (e.g., bariatric surgery) and medical conditions (e.g., bulimia and anorexia). Diets defined by geographical location-based general eating patterns (e.g., Mediterranean diet, Asian diet) were excluded.

### 6.2.3. Study selection

Citations retrieved from the electronic databases were collated into an EndNote library. After removal of duplicates, the library was imported into Covidence [662]. Two reviewers (two of SS, BC, MW, LD, and MM) independently performed title/abstract screening; studies judged as 'eligible' or 'potentially eligible' progressed to full-text screening. Two review authors (two of SS, BC, MW, and LD) independently screened the full texts and decided whether to 'include' or 'exclude' the studies, based on the pre-defined eligibility criteria. Discrepancies were resolved by discussion (SS and LD).

### 6.2.4. Data extraction and management

Two reviewers (SS and one of BC, MW or LD) independently extracted the predefined key study data (Supplement 1) from eligible studies; discrepancies were resolved by discussion (SS and LD). Extracted data were exported to Cochrane Review Manager (RevMan Version 5.4) software [663].

### 6.2.5. Risk of bias assessment

To account for the inclusion of different study designs, a variety of risk of bias tools were used for the quality assessments. Two review authors (SS and one of BC, MW or LD) independently performed the assessments; discrepancies were resolved by discussion. The risk of bias tools used were: ROBINS-I tool for non-randomized intervention studies [664], Newcastle Ottawa scale for cohort and case-control studies [665], National Heart, Lung, and Blood Institute (NHLBI) tool for cross-sectional studies and pre-post studies with no control group [666].

### 6.2.6. Primary and secondary outcomes

The primary outcome was change from baseline in dry eye symptom score, measured using a questionnaire or visual analogue scale. Secondary outcomes were the change from baseline in tear breakup time (secs), tear osmolarity (mOsm/L), degree of meibomian gland atrophy (%), degree of anterior blepharitis, corneal staining scores, Schirmer score (mm), degree of conjunctival hyperemia, quality of life, and incidence of ocular adverse events.

All outcomes were considered for the following follow-up periods: (i) short-term: measured the study outcome(s) at 7–28 days inclusive of the intentional food restrictions; and (ii) longer-term: measured the study outcome(s) at more than 28 days after intentional food restrictions.

### 6.2.7. Data synthesis and analysis

Primary and secondary outcome data were extracted as the mean change from baseline and standard deviation (SD) of the change across

the intervention and control groups. When change from baseline data were not available, study endpoint data were extracted.

Meta-analyses were performed using Cochrane Review Manager software [663] for each intervention category where data were available, when at least two studies reported data in a consistent format and a pooled analysis was deemed clinically appropriate (e.g., for studies where the intervention and the clinical population were similar). For pre-post studies, meta-analysis was performed using the generic inverse variation effect estimation method [667].

Clinical and methodological heterogeneity were assessed by evaluating the study design, participant characteristics and intervention type. Statistical heterogeneity was quantified using the I-squared ( $I^2$ ) statistic, which quantifies the percentage of variability across all studies. An  $I^2$  statistic >60% and Chi-squared test  $p$  value < 0.10 defined significant heterogeneity [668]. If there was only one study or data pooling was not appropriate (i.e., in the presence of significant heterogeneity), a narrative summary of the key findings was provided.

The certainty of the body of evidence for both the primary and secondary outcomes were assessed using the Grading of Recommendations, Assessment, Development and Evaluation (GRADE) approach and judged as high, moderate, low, or very low. The reason(s) for downgrading the certainty estimates are reported in the 'Summary of findings' (Table 5).

## 6.3. Results

### 6.3.1. Characteristics of included studies

The electronic database searches yielded 7250 citations (Fig. 1). After removing duplicates ( $n = 1357$ ), title and abstract screening was performed on 5893 citations. Of these, 75 citations underwent full-text screening, and 25 studies met the pre-specified eligibility criteria and were included. A list of studies excluded at the full-text review stage and the primary reason for exclusion are provided in Supplement 1.

All 25 studies [295,335–339,503,504,613,659,669–683] were full-text articles published between 1951 and 2021; their key characteristics are summarised in Table 6. The studies were conducted in six countries: UK ( $n = 3$ ) [503,669,670], Turkey ( $n = 3$ ) [613,673,681], USA ( $n = 2$ ) [659,675], United Arab Emirates ( $n = 1$ ) [339], Brazil ( $n = 1$ ) [504], and Iran ( $n = 1$ ) [337]. Fourteen studies did not report their study location [295,335,336,338,671,672,674,676–680,682,683]. The study designs were pre-post intervention ( $n = 14$ ) [335–339,503,669,670,672,676–678,681,683], cross-sectional ( $n = 8$ ) [295,613,659,671,673,674,679,680], non-randomized interventional ( $n = 1$ ) [675], and retrospective ( $n = 1$ ) [504] or prospective ( $n = 1$ ) [682] cohort.

The types of exposures evaluated were religious fasting ( $n = 14$ ) [335–339,672,673,676–679,681–683], bariatric surgery ( $n = 4$ ) [503,504,669,670], short-term fasting (12-h,  $n = 1$ ) [680], riboflavin depletion diet ( $n = 1$ ) [675], anorexia nervosa ( $n = 4$ ) [295,659,671,674] and celiac disease ( $n = 1$ ) [613].

In total, 1181 participants were enrolled across the 25 studies with individual study sample sizes ranging from 14 to 134 participants. Twenty-three studies [295,336–339,504,613,659,669–678,680–683] reported sex distribution of the recruited or study completed participants; female ( $n = 533$ ), male ( $n = 437$ ). The unit of analysis was a single eye in seven studies [336–338,676,679,681,683], both eyes in seven studies [504,613,672,673,677,678,682], per participant in two studies [671,674], and unclear in nine studies [295,335,339,503,659,669,670,675,680].

### 6.3.2. Risk of bias assessment

Supplement 1 provides detail and justification for the risk of bias assessments. The 14 pre-post intervention studies were judged to have poor ( $n = 13$ ) [335–339,503,670,672,676–678,681,683] or fair ( $n = 1$ ) [669] quality due to studies not reporting study eligibility criteria, sample size calculations and/or information related to masking of the outcome assessors. The eight cross-sectional studies [295,613,659,671,

**Table 5**

Summary of findings, including Grading of Recommendations, Assessment, Development and Evaluation (GRADE) assessments for the certainty of the body of evidence, for religious fasting, bariatric surgery, and anorexia nervosa.

Intervention/exposure vs comparator	Outcome measure	No. of participants (no. of studies)	Certainty of the evidence (GRADE)	Estimated (CI) with intervention/exposure
Pre versus post Ramadan fasting	Dry eye symptom score, measured using a questionnaire or rating scale	79 (2)	⊕⊕⊕⊕ <sup>a</sup> Very low	Study #1 [336] reported significantly higher symptom scores with Ramadan fasting compared to non-fasting: 5.60 units higher (1.84 lower to 9.36 higher). Study #2 [339] reported no significant difference in symptom scores measured with Ramadan fasting compared to non-fasting: MD: 4.50 units lower (13.07 lower to 4.07 higher). Both studies [336,339] measured dry eye symptoms using the OSDI questionnaire.
	Tear film break up time (s), measured using non-invasive or sodium fluorescein method	205 (4)	⊕⊕⊕⊕ <sup>b</sup> Very low	Study #1 [339] reported significantly lower tear break up time with Ramadan fasting compared to non-fasting: MD: -1.7 s lower (2.93 lower to 0.47 higher). Study #2 [337] reported no significant difference between Ramadan fasting versus non-fasting: MD: 1.46 higher (0.34 lower to 3.26 higher). Study #3 [336] reported no significant difference between Ramadan fasting versus non-fasting: MD: 0.80 lower (1.66 lower to 0.06 higher). Study #4 [338] reported no significant difference between morning versus evening of Ramadan fasting: MD: 3.55 s higher (1.64 lower to 8.74 higher). Three studies [336,338,339] used a sodium fluorescein method and one study [33] used a non-invasive method.
	Tear volume/flow (mm/5 min), measured using the Schirmer score	142 (4)	⊕⊕⊕⊕ <sup>c</sup> Very low	Study #1 [336] reported significantly lower Schirmer score with Ramadan fasting compared to non-fasting: MD: 4.20 mm/5 min lower (6.43 lower to 1.97 higher). Study #2 [676] reported no significant difference between Ramadan fasting versus non-fasting: MD: 0.26 mm/5 min lower (2.16 lower to 1.64 higher). Study #3 [339] reported no significant difference between Ramadan fasting versus non-fasting: MD: 0.90 mm/5 min lower (2.88 lower to 1.08 higher). Study #4 [338] reported no significant difference between morning versus evening of Ramadan fasting: MD: 0.20 mm/5 min lower (3.34 lower to 2.94 higher). Measurement techniques involved - two studies with anesthesia [338,339], one study without anesthesia [336], and another study using both with/without anesthesia [676].
	Corneal staining score, measured using a grading scale	50 (1)	⊕⊕⊕⊕ <sup>d</sup> Very low	One study [339] reported no significant difference between Ramadan fasting versus non-fasting: MD: 0.00 units (0.39 lower to 0.39 higher). This study used Oxford grading scale to quantify corneal staining.
	Tear osmolarity (mOsmol/L)	29 (1)	⊕⊕⊕⊕ <sup>e</sup> Very low	One study [336] found a significantly higher tear osmolarity during Ramadan fasting compared to a non-fasting period: 7.70 mOsm/L higher (1.58 lower to 13.82 higher). In this study tear osmolarity was measured using the OcuSense TearLab system.
Pre-operative versus post-bariatric surgery	Dry eye symptom score, measured using a questionnaire or rating scale	57 (1)	⊕⊕⊕⊕ <sup>f</sup> Very low	One study [504] found no significant difference between measures in a pre-operative group, and in another group who were at least 12-months post bariatric surgery: MD: 8.30 units higher (4.79 lower to 21.39 higher). This study measured dry eye symptoms using the OSDI questionnaire.
	Tear film break up time (s), measured using sodium fluorescein method	57 (1)	⊕⊕⊕⊕ <sup>f</sup> Very low	One study [504] found no significant difference between pre-operative versus greater than 12-months post-surgery groups: MD: 0.20 s lower (2.88 lower to 2.48 higher).
	Tear volume/flow (mm/5 min), measured using the Schirmer score	57 (1)	⊕⊕⊕⊕ <sup>f</sup> Very low	One study [504] found no significant difference between pre-operative versus greater than 12-months post-surgery groups: MD: 2.40 mm/5 min (4.41 lower to 9.21 higher). This study measured Schirmer score without anesthesia.
Anorexia nervosa versus healthy controls	Tear volume/flow (mm/5 min), measured using the Schirmer score	14 (1)	⊕⊕⊕⊕ <sup>g</sup> Very low	One study [659] found a significantly lower score in the anorexia nervosa group compared to controls: MD: 11.10 mm/5 min lower (16.76 lower to 5.44 higher). This study measured Schirmer score with anesthesia.

**Abbreviations:** CI, confidence interval; MD, mean difference; mm, millimeter; min, minutes; OSDI, ocular surface disease index. \*Only outcome measures evaluated by at least one study are listed.

- <sup>a</sup> Downgraded two levels due to risk of bias as all four studies were judged to be of poor quality (refer supplement I for details) [336,339].
- <sup>b</sup> Downgraded three levels due to risk of bias as all four studies were judged to be of poor quality (refer supplement I for details) [336–339,676].
- <sup>c</sup> Downgraded three levels due to risk of bias as all four studies were judged to be of poor quality (refer supplement I for details) [336,338,339,676].
- <sup>d</sup> Downgraded three levels due to imprecision, as outcome data derived from one study [339] with a small sample size.
- <sup>e</sup> Downgraded three levels due to imprecision, as outcome data derived from one study [336] with a small sample size.
- <sup>f</sup> Downgraded three levels due to imprecision, as outcome data derived from one study [504] with a small sample size.
- <sup>g</sup> Downgraded three levels due to imprecision, as outcome data derived from Ref. [659] with a small sample size.

673,674,679,680] were judged to have poor quality due to not defining the study population clearly, absence of reporting sample size calculations and/or insufficient information about whether outcome assessors were masked. The two cohort studies [504,682] were judged to have unsatisfactory quality due to absence of any information related to the derivation of the study cohort, ascertainment of the exposure, and adjustment for confounders. The non-randomized experimental study [675] was judged to have a serious risk of bias because of confounding and potential biases in the selection of the reported results.

### 6.3.3. Effects of interventions

**6.3.3.1. Religious fasting.** Fourteen studies investigated religious fasting using pre-post [335–339,672,676–678,681,683], cross-sectional [673,679], or cohort study designs [682]. All studies assessed Ramadan fasting, which involves abstaining from food, water and smoking from dawn to sunset for a period of 29 or 30 days [336,683]. Absence of liquid intake during the daytime has been found to cause changes to body fluid and hemodynamics [338]. As a result of this dehydration, it has been hypothesized to alter tear film dynamics and provoke ocular symptoms [336]. The control group for the cross-sectional and cohort studies comprised non-fasting individuals. Combined, these studies included 725 participants; sample sizes ranged from 15 to 134 participants [335–339,672,676–678,681,683]. Of the 14 included studies, nine [335,672,673,677–679,681–683] did not measure any of the expected primary or secondary outcomes.

**6.3.3.1.1. Primary outcome.** Two studies measured dry eye symptom scores using the OSDI questionnaire (Fig. 2) [336,339]. Pooling data from these pre-post studies was not deemed appropriate due to high statistical heterogeneity ( $I^2 = 78\%$ ,  $p = 0.03$ ), in the presence of divergent study effects and differences in sex distribution of the included participants. The studies differed in their design, with one study [339] collecting data from one week prior to the beginning of Ramadan fasting and then in the third or fourth week of fasting between 12 and 5pm. The other study design involved collecting data two weeks prior to the beginning of Ramadan fasting and then in the first week of fasting, with all measurements captured between 4 and 5PM [336]. One study [339] reported no significant difference in dryness symptoms between Ramadan fasting and the non-fasting period (Fig. 2), whereas another study [336] reported lower symptom scores during non-fasting compared to Ramadan fasting (29 participants; mean difference mean difference: 5.60 units; CI: 1.84 to 9.36;  $p = 0.004$ ). The GRADE certainty of evidence for this outcome was judged as very low (Table 5).

**6.3.3.1.2. Secondary outcomes.** Four studies evaluated tear breakup time (Fig. 3) using fluorescein [336,338,339] and non-invasive (no fluorescein) [337] methods. Pooling data from these four studies [336–339] was deemed inappropriate due to high inter-study heterogeneity ( $I^2 = 72\%$ ,  $p = 0.01$ ). This could be a result of differences in sex distribution across the included studies or variation in outcome measurement techniques (fluorescein versus non-invasive). There were also variations in follow-up periods during Ramadan fasting between the studies; first week of Ramadan [336], third or fourth week of Ramadan [339] and last week of Ramadan [337]. Further, one study [338] collected data over the course of the day, at the beginning (8am and 8:30am) and end of Ramadan fasting (4:30pm and 5pm).

One study [339] reported lower fluorescein tear breakup times after 3–4 weeks of Ramadan fasting compared to non-fasting (40 participants; mean difference:  $-1.70$  units; CI:  $-2.93$  to  $-0.47$ ;  $p = 0.007$ ). No significant difference in fluorescein tear breakup time after one week of Ramadan fasting compared to non-fasting was reported in another study (Fig. 3) [336]. Another study [337] reported no difference in non-invasive tear breakup time during last week of Ramadan fasting compared to non-fasting (Fig. 3). Further, one study [338] reported no difference in tear breakup time measured at the beginning (8:00am - 8:30am) and end of Ramadan fasting (4:30pm - 5:00pm) over the course of a day (Fig. 3).

Four studies evaluated Schirmer test scores (Fig. 4) [336,338,339,676], measured with anesthesia [338,339], without anesthesia [336], or using both techniques [676]. Pooling data from these four studies [336,338,339,676] was not deemed appropriate due to high inter-study heterogeneity ( $I^2 = 64\%$ ;  $p = 0.04$ ). This could be due to differences in sex distribution across the included studies, differences in outcome measurement techniques (with or without anesthesia) and variation in follow-up timepoint reported during Ramadan fasting measures across the included studies. One study [336] reported lower Schirmer test scores measured without anesthesia after one week of Ramadan fasting compared to non-fasting (29 participants; mean difference:  $-4.20$ ; CI:  $-6.43$  to  $-1.97$ ;  $p = 0.0002$ ). No difference in Schirmer test measured both with/without anesthesia during Ramadan fasting compared to non-fasting was reported in another study, but it was unclear at what timepoint the follow-up occurred [676] (Fig. 4). Another study [339] reported no difference in Schirmer test measured using anaesthesia after 3–4 weeks of Ramadan fasting compared to non-fasting (Fig. 4). Likewise, one study [338] reported no significant difference for Schirmer test measured with anesthesia at the beginning and end of fasting (Fig. 4).

Based on data from one study [336], tear osmolarity was higher during Ramadan fasting compared to a non-fasting period (29 participants; mean difference: 7.70 mOsm/L; CI: 1.58 to 13.82;  $p = 0.01$ ). A separate study [339] reported no difference (40 participants; mean difference: 0.00 units; CI:  $-0.39$  to 0.39;  $p = 1.00$ ) in corneal staining scores, measured using the Oxford scale, between Ramadan fasting and non-fasting periods.

The GRADE certainty of the evidence for each of these outcomes (tear breakup time, Schirmer test, tear osmolarity, and corneal staining score) was judged as very low (Table 5).

#### 1. Bariatric surgery

Four studies investigated bariatric surgery using pre-post [503,669,670] or retrospective cohort study designs [504]. Together they enrolled 161 participants; individual sample sizes ranged from 20 to 89 participants [503,504]. The pre-post intervention studies evaluated the outcome measures at baseline and 12-months after bariatric surgery. The retrospective cohort study compared pre-operative with post-bariatric surgery groups consisting of between 1 and 12 months post-surgery, and greater than 12 months. Of the four included studies, three [503,669,670] did not measure any of the primary or secondary outcomes. Primary outcome

One study [504] provided very low certainty evidence (Table 5) for no significant difference in OSDI scores between pre-operative group, and in another group who were at least 12 months post-bariatric surgery (57 participants; mean difference: 8.30 units; CI:  $-4.79$  to 21.39;  $p = 0.21$ ). Secondary outcomes

There was no difference in fluorescein tear breakup time in one study measured in separate groups pre-operatively and greater than 12-months post bariatric surgery (57 participants; mean difference:  $-0.20$  units; CI:  $-2.88$  to 2.48;  $p = 0.88$ ) [504]. This study also reported no difference in Schirmer test scores measured without anaesthesia (57 participants; mean difference: 2.40 mm/5 min; CI:  $-4.41$  to 9.21;  $p = 0.49$ ) between the study groups. The certainty of the evidence for both outcomes was judged as very low (Table 5).

#### 2. Anorexia nervosa

Four studies evaluated participants with anorexia nervosa compared to healthy controls using a cross-sectional design [295,659,671,674]. Combined, these studies included 152 participants; sample sizes ranged from 14 to 76 participants. Only one [3] of the four studies reported data on Schirmer test scores. None of the studies reported data on the primary or other secondary outcomes.

One study [659] provided very low certainty evidence (Table 5) for lower Schirmer test scores measured with anesthesia in an anorexia nervosa group compared to healthy controls (14 participants; mean difference:  $-11.10$  mm/5 min; CI:  $-16.76$  to  $-5.44$ ;  $p < 0.001$ ).

#### 3. Short-term (12-h) fasting



One study [680] investigated the effect of a 12-h fasting period compared to a non-fasting group using a cross-sectional design. In total, 33 participants were evaluated but the study did not measure any of the primary or secondary outcomes.

4. Celiac disease

Participants with Celiac disease were compared to healthy controls using a cross-sectional study design [613]. This study included 71 participants, but did not measure any of the pre-specified primary or secondary outcomes.

5. Riboflavin depletion diet

An investigation of the effect of a riboflavin depletion diet compared to a normal unrestricted diet in 39 participants using a non-randomized controlled trial design again did not measure any of the pre-specified primary or secondary outcomes [22].

6.4. Discussion

This is the first systematic review to investigate the effects of intentional food restriction on ocular surface health. Of the 25 included studies, most investigated Ramadan fasting (56%), followed by bariatric surgery (16%), anorexia nervosa (16%), or other interventions/conditions (12%), which included 12-h fasting, celiac disease and riboflavin depletion diet. Based on risk of bias assessments, none of the studies were judged to be of high quality (i.e., at minimal risk of bias). All studies were assessed to be of fair, poor or unsatisfactory quality or have serious risk of bias, as determined by the appropriate risk of bias tool for the study design. Common reasons for downgrading the quality assessments were lack of masking of the investigator/outcome assessor(s) and failure to report the sample size calculations. The GRADE certainty of the evidence for the pre-specified primary and secondary outcomes, across all interventions, was judged as very low.

This review did not identify any relevant studies that used a

randomized controlled trial design; most studies were of a pre-post intervention design (56%). The National Health and Medical Research Council of Australia evidence hierarchy proposed that studies with pre-post designs contribute a relatively low level of empirical evidence for intervention questions (Level IV) [684]; this acknowledges the inherent limitations and risk of bias in these designs, which include lack of randomisation, potential for regression to the mean and poor internal validity. These limitations should be considered when interpreting the individual study results in this review. To build upon the current evidence base, future studies should consider the benefits of randomized controlled trial designs, where possible, in minimising risks of bias, to enable greater certainty to be achieved in understanding the effect of intentional food restriction on ocular surface parameters. However, it is acknowledged that it is generally unethical to delay or randomize religious fasting, dieting or weight loss surgery; so the current evidence may continue to be the best available to inform decision-making.

In this review, no studies were found to mask both participants and outcome assessors. This finding is not surprising given the clear challenges associated with masking participants (in particular) for interventions that include religious fasting, dietary restriction and surgery. There is also the possibility that treatment effects or adverse events associated with particular surgeries or diets might (inadvertently) unmask outcome assessors. For interventions where participants and/or outcome assessors are unable to be masked, attempts should be made to minimize other sources of bias. For example, this might include measures to ensure uniformity in the delivery of intervention(s), equivalent follow-up period between the study groups and the selection of objective outcome measures, where possible, to reduce the potential influence of participant or outcome assessor input that might induce measurement bias [685].

Of the 25 included studies, none reported adverse event data. This limits the investigation of the safety of intentional food restrictions on

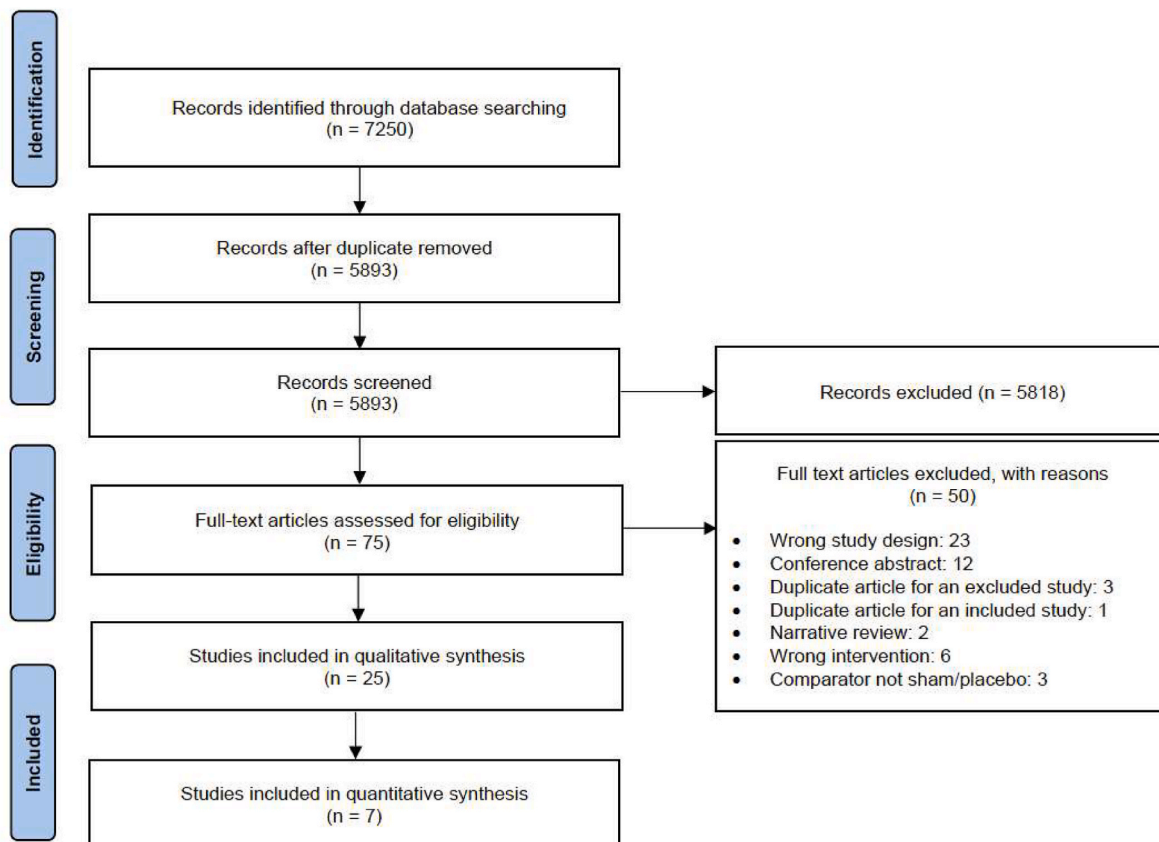


Fig. 1. Flow diagram of studies included in the systematic review in Section 6.

**Table 6**  
Key characteristics of the included studies.

Study	Intervention/ condition	Study design	Research question type	Study location	Total sample size (No. of female)	Participant age (years)		Ocular surface outcomes measured	Overall study quality based on RoB judgements <sup>a</sup>
						Intervention/ condition Mean (SD)	Comparator Mean (SD)		
Armstrong et al. (2019) [339]	Religious fasting - Ramadan	Pre-post	Intervention	UAE	50 (27)	32 [R: 23 to 45]		1) OSDI score 2) Schirmer score - with anesthesia 3) Fluorescein TBUT 4) Corneal staining score 5) InflammDry	(1) Poor
Baser et al. (2016) [672]		Pre-post	Intervention	NR	15 (0)	34.13 (7.74)		1) CCT	(2) Poor
Beyoglu et al. (2020) [673]		Cross-sectional	Etiology	Turkey	100 (47)	34.96 (16.01)	36.06 (14.28)	1) Corneal endothelial cell density 2) CCT	(3) Poor
Kayikcioglu et al. (1998) [338]		Pre-post	Intervention	NR	32 (0)	22.3 (2.9)		1) Schirmer score – with anesthesia 2) Fluorescein TBUT	(4) Poor
Kerimoglu et al. (2010) [676]		Pre-post	Intervention	NR	31 (12)	31.7 (5.3)		1) Schirmer score – both with/ without anesthesia 2) CCT	(5) Poor
Koktekir et al. (2014) [336]		Pre-post	Intervention	NR	29 (0)	27.8 (5.9)		1) OSDI score 2) Schirmer score – without anesthesia 3) Fluorescein TBUT 4) Corneal and conjunctival staining 5) Tear osmolarity	(6) Poor
Nilforushan et al. (2020) [677]		Pre-post	Intervention	NR	27 (17)	40.07 (9.29)		1) CCT	(7) Poor
Nowroozzadeh et al. (2012) [678]		Pre-post	Intervention	NR	22 (10)	60.55 (12.20)		1) Keratometry 2) Corneal astigmatism 3) Corneal radii of curvature	(8) Poor
Oltulu et al. (2016) [679]		Cross-sectional	Etiology	NR	134 (NR)	31.4 (9.3)	30.2 (10.7)	1) Corneal hysteresis 2) Corneal resistance factor	(9) Poor
Sarici et al. (2016) [681]		Pre-post	Intervention	Turkey	29 (NR)	38.07 (10.18)		1) CCT 2) Corneal astigmatism 3) Corneal volume 3) Corneal hysteresis 4) Corneal resistance factor	(10) Poor
Sariri et al. (2010) [335]		Pre-post	Intervention	NR	60 (25)	R: 23 to 27		1) Ocular tear protein levels	(11) Poor
Sedaghat et al. (2017) [337]		Pre-post	Intervention	Iran	94 (40)	35.12 (9.07)		1) CCT 2) NIKBUT	(12) Poor
Selver et al. (2017) [682]		Prospective cohort	Etiology	NR	61 (35)	43.35 (13.20)	43.17 (12.90)	1) CCT	(13) Unsatisfactory
Uysal et al. (2018) [683]		Pre-post	Intervention	NR	41 (0)	32.7 (5.1)		1) CCT 2) Corneal hysteresis 3) Corneal resistance factor 4) Corneal volume	(14) Poor
Rocha et al. (2002) [680]	12-h fasting	Cross-sectional	Etiology	NR	33 (16)	R: 23 to 51		1) Insulin levels in tears	(15) Poor
Adam et al. (2021) [669]	Bariatric surgery	Pre-post	Intervention	UK	26 (16)	52 (10)		1) Corneal nerve fiber density	(16) Fair

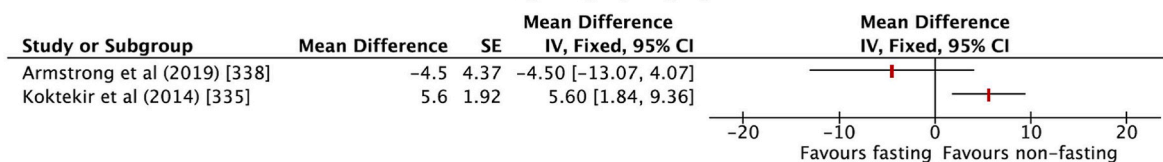
(continued on next page)

Table 6 (continued)

Study	Intervention/condition	Study design	Research question type	Study location	Total sample size (No. of female)	Participant age (years)		Ocular surface outcomes measured	Overall study quality based on RoB judgements <sup>^</sup>
						Intervention/condition Mean (SD)	Comparator Mean (SD)		
Azmi et al. (2021) [670]		Pre-post	Intervention	UK	26 (17)	46.23 (8.6)		2) Corneal branch density 3) Corneal fiber length 1) Corneal nerve fibre density 2) Corneal branch density 3) Corneal fiber length	(17) Poor
Iqbal et al. (2021) [503]		Pre-post	Intervention	UK	20 (NR)	48.8 (8.3)		1) Corneal nerve fibre density 2) Corneal branch density 3) Corneal fiber length 4) Keratocyte density	(18) Poor
Marques et al. (2017) [504]		Retrospective cohort	Etiology	Brazil	89 (81)	46.5 (7.3)	41.3 (9.3)	1) OSDI score 2) Schirmer score - without anesthesia 3) Fluorescein TBUT 4) Rose Bengal staining score 5) Tear ferning test 6) Conjunctival impression cytology	(19) Unsatisfactory
Abraham et al. (1980) [295]	Anorexia nervosa	Cross-sectional	Etiology	NR	26 (26)	22 [R: 15 to 22]	R: 18 to 22	1) Anterior segment evaluation using slit lamp biomicroscopy	(20) Poor
Barbato et al. (2006) [671]		Cross-sectional	Etiology	NR	36 (36)	20.1 (4.3)	20.3 (1.3)	1) Blink rate	(21) Poor
Frank et al. (2020) [674]		Cross-sectional	Etiology	NR	76 (76)	22.61 (7.27)	23.27 (5.35)	1) Blink rate	(22) Poor
Gilbert et al. (1990) [659]		Cross-sectional	Etiology	USA	14 (14)	22 [NR]	24.6 [NR]	1) Anterior segment evaluation using slit lamp biomicroscopy 2) Schirmer score - with anesthesia 3) Conjunctival impression cytology	(23) Poor
Donmez Gun et al. (2021) [613]	Celiac disease	Cross-sectional	Etiology	Turkey	71 (51)	39.56 (7.39)	36.34 (7.62)	1) CCT 2) Corneal endothelial cell density	(24) Poor
Hills et al. (1951) [675]	Riboflavin depletion	Non-RCT	Intervention	USA	39 (0)	R: 18 to 48		1) Anterior segment evaluation using slit lamp bio microscopy 2) Schirmer score – technique not reported 3) Corneal sensitivity	(25) Serious concerns

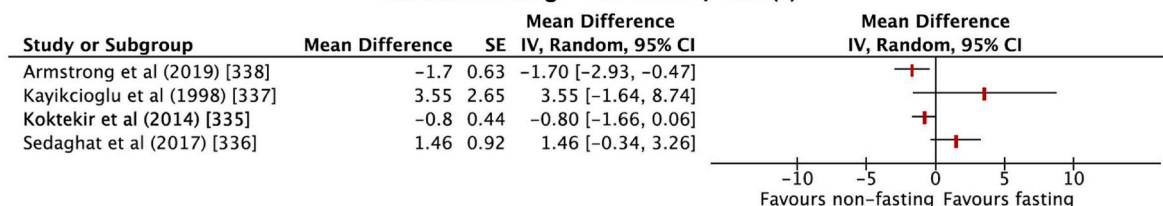
Abbreviations: CCT, central corneal thickness; NR, not reported; NIKBUT, non-invasive Keratograph breakup time; OSDI, Ocular Surface Disease Index, R, range; RCT, randomized controlled trial; RoB, risk of bias; SD, standard deviation; TBUT, tear breakup time; UAE, United Arab Emirates. <sup>^</sup>Assessments were performed using the relevant risk of bias tools, which were: ROBINS-I tool for non-RCT [9], Newcastle Ottawa scale for cohort and case-control studies [10], NIH tool for both cross-sectional, and pre-post studies with no control group [11].

**Ramadan fasting - Dry eye symptom score**



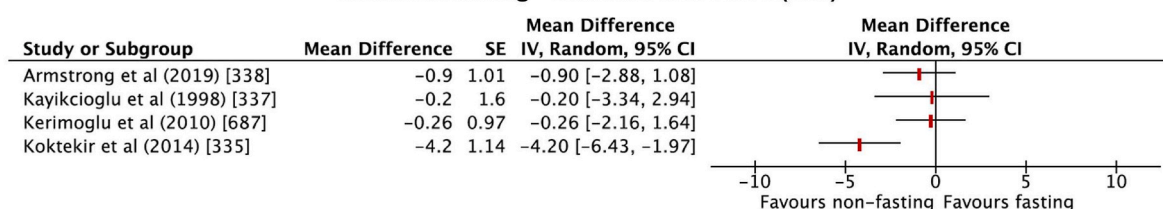
**Fig. 2.** Forest plot of comparison: Ramadan fasting vs. control (non-fasting). Outcome: Dry eye symptoms measured using the OSDI questionnaire. For Koktekir et al. [336] it is unclear if there were any losses to follow-up; an assumption was made that all participants that were initially recruited (n = 29) completed the study. Higher scores indicate more severe symptoms.

**Ramadan fasting - Tear break up time (s)**



**Fig. 3.** Forest plot of comparison: Ramadan fasting vs. control (non-fasting). Outcome: Tear breakup time, measured in seconds. For Koktekir et al. [336], Kayikcioglu et al. [338], and Sedaghat et al. [337] it was unclear if there were any losses to follow-up; an assumption was made that all participants that were initially recruited completed the study. Higher scores indicate greater tear film stability.

**Ramadan fasting - Schirmer test score (mm)**



**Fig. 4.** Forest plot of comparison: Ramadan fasting vs. control (non-fasting). Outcome: Tear volume/flow measured using the Schirmer score (mm/5 min). For Koktekir et al. [336], Kayikcioglu et al. [338], and Kerimoglu et al. [676] it was unclear if there were any losses to follow-up; an assumption was made that all participants that were initially recruited completed the study. Higher scores indicate greater tear production.

the ocular surface, or the opportunity to conduct risk-benefit analysis. Hence, future studies should comprehensively assess and report adverse events to enable a more complete understanding of the safety profile of intentional food restriction in relation to the ocular surface.

**7. Conclusions and new frontiers**

Nutrition is a modifiable factor that can influence general health and well-being. This report explored the various aspects of nutrition and the evidence relating to its impact on the health of the ocular surface. An overarching issue identified is the relative paucity of high-quality evidence in explaining the role of nutrition in ocular surface health and disease. A summary of the evidence found is highlighted in Table 7 and Fig. 5.

With regard to macronutrients, evidence that omega-3 deficiency results in ocular surface sequelae is provided in accumulating (though sometimes conflicting) evidence, particularly with regard to dry eye disease. Direct evidence, however, is lacking for the role of oils such as olive oil, primrose oil, palm oil, soybean oil and hydrogenated vegetable oils. Sugars and artificial sweeteners, while being shown to be involved in metabolic syndrome and glucose intolerance, have not yet been studied with regard to the ocular surface. Similarly, although gluten-free diets have been adopted in those with celiac disease, and ocular surface inflammation can develop in these individuals, eliminating gluten from the diet has not been studied with respect to its potential to modulate ocular surface inflammation.

In regard to micronutrients, the major vitamins identified to play a role in ocular surface health are vitamins A, B<sub>12</sub>, C and D. Particularly, deficiencies have been associated with ocular surface disease.

Dietary supplements were explored. Based on the current evidence, caffeine use does not appear to be a risk factor for dry eye disease and may have beneficial effects on tear production and symptoms, but further research is needed to verify these findings. Studies on collagen, oral honey and seeds, and their effect on the ocular surface are limited, while studies on various herbs and spices tend to indicate improved dry eye parameters but lack high-quality evidence. Minerals in dry eye have been explored only in conjunction with vitamins, anti-oxidants and/or omega-3-fatty acids, and so their sole effect on the ocular surface needs to be examined. Two separate meta-analyses of studies examining selenium intake in individuals with Graves’ ophthalmopathy concluded that the evidence does not yet support a role for selenium supplementation in standard care of auto-immune thyroiditis, with a possible exception for persons with a known selenium deficiency.

Omega-3 and omega-6 polyunsaturated fatty acids are the most extensively studied dietary supplements in ocular surface disease, with numerous randomized controlled trials and systematic reviews and meta-analyses, mostly in patients with dry eye disease or MGD. Given the current evidence of efficacy and their relatively favorable safety profile, omega-3 fatty acids may be a relevant treatment option for patients with dry eye disease and MGD, acknowledging that their exact role in treatment remains incompletely understood. A recommendation for future studies is that baseline measurements of omega-3 status are



**Table 7**

The current evidence relating to nutrition and ocular surface health. (+): the item has been associated with a positive effect on ocular surface health; (–) the item has been associated with a negative effect on ocular surface health; (±): The item has been associated with both positive and negative effects on ocular surface health.

Topic area	Conclusive <sup>a</sup>	Probable <sup>b</sup>	Inconclusive <sup>c</sup>
Key elements of nutrition linked to ocular surface disease	Vitamin A deficiency (–) Vitamin C deficiency (–)	Vitamin B <sub>12</sub> deficiency (–) Vitamin D deficiency (–) Omega-6:3 imbalance (omega-6 (–), omega-3 (+))	Sugars and artificial sweeteners (–) Gluten (–) Hydration (+) Selenium (+) Lactoferrin (+)
Excipients, additives and non-nutritional components linked to ocular surface disease		Mercury (–)	Bisphenol A (–) Phthalates (–) Alcohol (–)
Dietary supplements studied relative to their ability to improve the status of ocular health	Omega-3 (+) Vitamin A (+)	Curcumin (+) Vitamin B <sub>12</sub> (+) Probiotics and prebiotics (+)	Caffeine (+) Collagen (+) Chinese Herbs (+) Honey (+) Selenium (+) Seeds (+)
Eating disorders, food intolerance, allergy, and different diets linked to ocular surface disease	Food allergy (–)	Anorexia nervosa (–) Mediterranean diet (+) Bariatric surgery (–)	Bulimia nervosa (–) Food intolerance (–) Western diet (–) African diet (+) Asian diet (+) Food restriction diets (±)
Gut microbiome aspects linked to ocular surface disease		Gut dysbiosis (–)	
Nutrition-related systemic disease linked to ocular surface disease	Obesity (–) Pre-diabetes and type 2 diabetes (–) Gastrointestinal disease (–)	Dyslipidemia (–) Hypertension (±) Metabolic syndrome (–) Cardiovascular disease (–) Chronic kidney disease (–)	Cancer (–)

<sup>a</sup> Consistent evidence implies the existence of at least one adequately powered and otherwise well-conducted study published in a peer-reviewed journal, along with the existence of a plausible biological rationale and corroborating basic research or clinical data.

<sup>b</sup> Suggestive evidence implies the existence of either inconclusive information from peer-reviewed publications or inconclusive or limited information to support the association, but either not published or published somewhere other than in a peer-reviewed journal.

<sup>c</sup> Inconclusive evidence implies either directly conflicting information in peer-reviewed publications, or inconclusive information but with some basis for a biological rationale.

reported using surveys of food-intake as a surrogate measure of blood levels of omega-3. Future studies should also determine if, and possibly which, dry eye patient subgroup(s) (subtype and/or severity of dry eye, or those who are omega-3 deficient) may benefit most from supplementation, whether a certain form or composition of omega-3 is preferable, what dosage and duration is best to recommend, and what dietary ratio of omega-3 to -6 is optimal in dry eye disease management. Appropriate sample size calculation, prospective trial registration, provision of details regarding the polyunsaturated fatty acids intervention including form and best practice for inclusion criteria for dry eye are key recommendations for these studies.

Hydration is essential for the optimal function of the human body including physical and cognitive performance. However, to date there have been few studies that assessed the role of hydration status or water intake on ocular surface health. Future longitudinal studies should investigate whether increasing water intake is beneficial in patients with dry eye disease.

An area of increasing interest is that of the role of excipients, additives and non-nutritional components on health. Further studies on the role of the many endocrine-disrupting chemicals on ocular surface disease are clearly needed, as well as the possible effects of food additives and non-nutritional chemicals, such as nanoparticles, emulsifiers and flavor enhancers, including glutaminase and monosodium glutamate, with most studies to-date being directed at their impact on systemic health and the gut microbiome. Mercury, most commonly consumed in mercury-contaminated seafood, has been linked to greater ocular surface discomfort, as has alcohol.

There is a paucity of data on the effect of different diets, with the effect of a high-fat diet, reflective of the Western diet, being largely explored in animal models rather than in human studies. The Mediterranean diet is the most studied, with interventional studies providing conflicting data with regard to the impact on dry eye parameters.

Further research is needed to explore the impact of various diets and nutrients on the ocular surface including a better understanding of absorption on the surface. Changing diet through acculturation might offer more understanding of the impact(s) of different diets on ocular surface disease.

The Subcommittee undertook a systematic review and meta-analysis to evaluate the effects of intentional food restriction on the ocular surface, concluding that there was a lack of high-quality evidence assessing this question to date. Mixed results were reported in individual studies in relation to the effects of religious fasting and bariatric surgery on traditional measures of ocular surface health (for example, dry eye symptoms, tear breakup time and Schirmer test score). Whether intentional food restriction affects the health of the surface of the eye therefore remains unclear.

Investigations into the gut microbiome and the ocular surface have been limited in size and sporadic, and much can be learned from additional research in this area. There is little evidence currently to state definitively that modulation of the gut microbiome can have beneficial effects on the ocular surface. Many metabolic and gastrointestinal disorders have been associated with an increased risk of ocular surface disease. Although the exact pathophysiological pathways leading to comorbid ocular surface diseases are often unknown for these disorders, the disorders may lead to deficiencies of micro- and macronutrients that are important in maintaining ocular surface health. With respect to cancer, most potential impacts on the ocular surface are likely to be overshadowed by the side-effects of chemotherapy.

The role of epigenetics in ocular surface disease is not well explored, although emerging evidence suggests that epigenetic modification may play a role in ocular surface diseases such as pterygium and keratitis.

In general, better-quality evidence is required in most of the areas covered in this report, including studies with adequate power. Future studies on dietary supplements should report on factors such as dosage

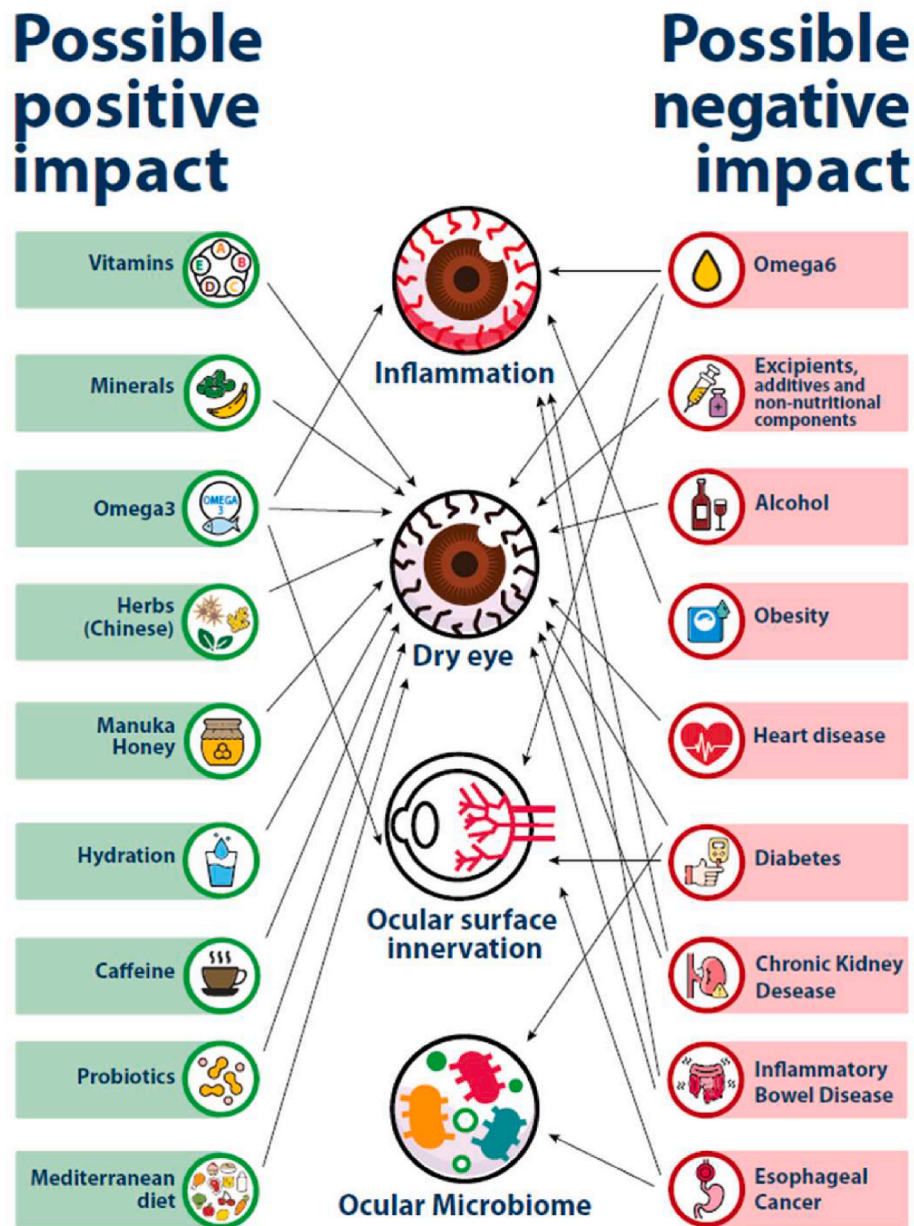


Fig. 5. Impact of nutrition on the ocular surface. Summary of the possible positive and negative impacts on the ocular surface.

and compare to a control group as well as to baseline measures. Moreover, future studies should also consider the broader dietary intake of study participants and any changes that occur over the course of the study and any adverse events that arise during the study. Future studies will also aid in our understanding of the role of biomarkers that can detect nutritional deficiencies and hence enable prevention of nutrition-related ocular surface disease.

Good nutrition is clearly pivotal for good health. There is significant evidence that good nutrition also impacts the ocular surface. Our journey to understanding the role of nutrition in every aspect of ocular surface health is still in its relative infancy, although progress is being made in many areas. Eyecare professionals are advised to consider the evidence prior to providing nutritional recommendations to patients with regard to their ocular surface health. Similarly, the clinician would be advised to consider a patient’s food habits in general, especially in patients with severe dry eye disease, and to consider co-management with dietitians.

**Declaration of competing interest**

- Maria Markoulli: Alcon (F), CooperVision (F).
- Sumaya Ahmad: None.
- Jayashree Arcot: None.
- Reiko Arita: (P), Alcon (F), Novartis (F), Senju Pharmaceutical (F), Santen (F), Rohto Pharmaceutical (F), Johnson & Johnson (F), Lumenis (F), Inami (F), Topcon (C).
- Jose M Benitez-del-Castillo: Alcon (C), Allergan (C), Angelini (C), Brill Farma (C), Esteve (F), GSK (C), Horus (C), Lumenis (F), Novartis (C), Santen (F), Thea (F).
- Barbara Caffery: Azura (F), Santen (C), VTI (F), Dompe (C).
- Laura Downie: Alcon Laboratories (F), Azura Ophthalmics (F), CooperVision (F), Kedalion Therapeutics (F), Medmont International (F), Novartis (F), Seqirus (F).
- Katie Edwards: None.
- Judith Flanagan: None.
- Marc Labetoulle: Alcon (F), Allergan (F), Baush & Lomb (F), DMG

(F), Dompe (F), GSK (F), Horus (F), MSD (F), Novartis (F), PHE (F), Quantel (F), Santen (F), Shire (F), Sifi (F), Topivert (F), Théa (F).

Stuti Misra: None.

Malgorzata Mrugacz: None.

John Sheppard: None.

Sumeer Singh: None.

Jelle Vehof: Alcon (C), Tramedico (C), Santen (C), Théa Pharma (C), Horus Pharma (C).

Piera Versura: None.

Mark Willcox: Alcon (F), Allergan (F), CooperVision (F), Johnson and Johnson Vision (F), Ophtecs (C, F).

Jillian Ziemanski: None.

James Wolffsohn: AOS (C), Aston Vision Sciences (S), Bausch & Lomb (C), Alcon (C,F), Allergan (F), CooperVision (C,F), CSIDryEye (C), Eyoto (S), Johnson & Johnson Vision (F), Rayner (F), M2C Pharmaceuticals (C,F), Medmont (C), Novartis (C,F), NuVision (C,F), Santen (C), Scope Ophthalmics (C,F), Théa (C,F), Topcon (F), The Eye Doctor (F), Wolffsohn Research Limited (S).

## Acknowledgments

The TFOS Lifestyle Workshop was conducted under the leadership of Jennifer P Craig, PhD FCOptom (Chair), Monica Alves, MD PhD (Vice Chair) and David A Sullivan PhD (Organizer). The participants are grateful to Amy Gallant Sullivan (TFOS Executive Director, France) for raising the funds that made this initiative possible. The TFOS Lifestyle Workshop was supported by unrestricted donations from Alcon, Allergan an AbbVie Company, Bausch + Lomb, Bruder Healthcare, CooperVision, CSL Seqirus, Dompé, ESW-Vision, ESSIRI Labs, Eye Drop Shop, I-MED Pharma, KALA Pharmaceuticals, Laboratoires Théa, Santen, Novartis, Shenyang Sinqi Pharmaceutical, Sun Pharmaceutical Industries, Tarsus Pharmaceuticals, Trukera Medical and URSAPHARM.

## Appendix A. Supplementary data

Supplementary data to this article can be found online at <https://doi.org/10.1016/j.jtos.2023.04.003>.

## References

- Gakidou E, Afshin A, Abajobir AA, Abate KH, Abbafati C, Abbas KM, et al. Global, regional, and national comparative risk assessment of 84 behavioural, environmental and occupational, and metabolic risks or clusters of risks, 1990–2016: a systematic analysis for the Global Burden of Disease Study 2016. *Lancet* 2017;390:1345–422.
- Lawn J, Kerber K. The partnership for maternal, newborn and child health. Opportunities for africa's newborns: practical data, policy and programmatic support for newborn care in Africa geneva. PMNCH; 2006.
- World Health Organization. Nutrition. Fact sheet. Geneva.: World Health Organization; 2020.
- García-Montero C, Fraile-Martínez O, Gómez-Lahoz AM, Pekarek L, Castellanos AJ, Noguerales-Fraguas F, et al. Nutritional components in western diet versus mediterranean diet at the gut microbiota-immune system interplay. Implications for health and disease. *Nutrients* 2021;13:699.
- Whitney E, Rolfes S, Crowe T, Cameron-Smith D, Walsh A. Understanding nutrition: Australia and New Zealand edition. NSW, Australia: Cengage Learning Australia Pty Limited; 2014. p. 122–58.
- Cho YW, Yoo WS, Kim SJ, Chung IY, Seo SW, Yoo JM. Efficacy of systemic vitamin C supplementation in reducing corneal opacity resulting from infectious keratitis. *Medicine (Baltim)* 2014;93:e125.
- Sahile Z, Yilma D, Tezera R, Bezu T, Haileselassie W, Seifu B, et al. Prevalence of vitamin A deficiency among preschool children in Ethiopia: a systematic review and meta-analysis. *BioMed Res Int* 2020;2020:8032894.
- The Dry Eye Assessment and Management Study Research Group, Asbell PA, Maguire MG, Pistilli M, Ying GS, Szczotka-Flynn LB, et al. n-3 fatty acid supplementation for the treatment of dry eye disease. *N Engl J Med* 2018;378:1681–90.
- Downie LE, Ng SM, Lindsley KB, Akpek EK. Omega-3 and omega-6 polyunsaturated fatty acids for dry eye disease. *Cochrane Database Syst Rev* 2019;12:CD011016.
- Downie LE, Britten-Jones AC, Hogg RE, Jalbert I, Li T, Lingham G, et al. Advancing the evaluation and synthesis of research evidence for the TFOS lifestyle workshop: report of the evidence quality subcommittee. *Ocul Surf* 2023. In press.
- NIAID-Sponsored Expert Panel, Boyce JA, Assa'ad A, Burks AW, Jones SM, Sampson HA, et al. Guidelines for the diagnosis and management of food allergy in the United States: report of the NIAID-sponsored expert panel. *J Allergy Clin Immunol* 2010;126:S1–58.
- University of Hawaii at Manoa Food Science and Human Nutrition Program. Human nutrition. 2020.
- Gordon M. In: Human nutrition: food and nutrient structure. 11 ed. Elsevier; 2005.
- Hodge W, Barnes D, Schachter HM, Pan Y, Lowcock EC, Zhang L, et al. Effects of omega-3 fatty acids on eye health. *Evid Rep Technol Assess* 2005;1–6.
- Chi SC, Tuan HI, Kang YN. Effects of polyunsaturated fatty acids on nonspecific typical dry eye disease: a systematic review and meta-analysis of randomized clinical trials. *Nutrients* 2019;11.
- Giannaccare G, Pellegrini M, Sebastiani S, Bernabei F, Roda M, Taroni L, et al. Efficacy of omega-3 fatty acid supplementation for treatment of dry eye disease: a meta-analysis of randomized clinical trials. *Cornea* 2019;38:565–73.
- Zhu W, Wu Y, Li G, Wang J, Li X. Efficacy of polyunsaturated fatty acids for dry eye syndrome: a meta-analysis of randomized controlled trials. *Nutr Rev* 2014;72:662–71.
- Liu A, Ji J. Omega-3 essential fatty acids therapy for dry eye syndrome: a meta-analysis of randomized controlled studies. *Med Sci Mon Int Med J Exp Clin Res* 2014;20:1583–9.
- Best KP, Gold M, Kennedy D, Martin J, Makrides M. Omega-3 long-chain PUFA intake during pregnancy and allergic disease outcomes in the offspring: a systematic review and meta-analysis of observational studies and randomized controlled trials. *Am J Clin Nutr* 2016;103:128–43.
- Britten-Jones AC, Craig JP, Downie LE. Omega-3 polyunsaturated fatty acids and corneal nerve health: current evidence and future directions. *Ocul Surf* 2023;27:1–12.
- Tako E. Dietary Trace Minerals. *Nutrients*. 2019;11.
- Institute of Medicine. Dietary reference intakes. Washington, DC: The National Academic Press; 2006.
- Sherwin JC, Kokavec J, Thornton SN. Hydration, fluid regulation and the eye: in health and disease. *Clin Exp Ophthalmol* 2015;43:749–64.
- Chen X, Zhang Z, Yang H, Qiu P, Wang H, Wang F, et al. Consumption of ultra-processed foods and health outcomes: a systematic review of epidemiological studies. *Nutr J* 2020;19:86.
- McClements DJ, Xiao H. Excipient foods: designing food matrices that improve the oral bioavailability of pharmaceuticals and nutraceuticals. *Food Funct* 2014;5:1320–33.
- Wakayama T, Ito Y, Sakai K, Miyake M, Shibata E, Ohno H, et al. Comprehensive review of 2-ethyl-1-hexanol as an indoor air pollutant. *J Occup Health* 2019;61:19–35.
- Yang L, Zhang Y, Wang F, Luo Z, Guo S, Strahle U. Toxicity of mercury: molecular evidence. *Chemosphere* 2020;245:125586.
- Jacobs DR, Tapsell LC. Food synergy: the key to a healthy diet. *Proc Nutr Soc* 2013;72:200–6.
- Ferraris C, Elli M, Tagliabue A. Gut microbiota for health: how can diet maintain a healthy gut microbiota? *Nutrients* 2020;12:3596.
- Downie LE, Keller PR. Nutrition and age-related macular degeneration: research evidence in practice. *Optom Vis Sci* 2014;91:821–31.
- Jacobs Jr DR, Gross MD, Tapsell LC. Food synergy: an operational concept for understanding nutrition. *Am J Clin Nutr* 2009;89:1543S–8S.
- Siddiqui RA, Moghadasian MH. Nutraceuticals and nutrition supplements: challenges and opportunities. *Nutrients* 2020;12:1593.
- Fardet A, Rock E. Toward a new philosophy of preventive nutrition: from a reductionist to a holistic paradigm to improve nutritional recommendations. *Adv Nutr* 2014;5:430–46.
- NIH State-of-the-Science Panel. National institutes of health state-of-the-science conference statement: multivitamin/mineral supplements and Chronic disease prevention. *Ann Intern Med* 2006;145:364–71.
- Thomas B, Gostin LO. Tackling the global NCD crisis: innovations in law and governance. *J Law Med Ethics* 2013;41:16–27.
- San-Cristobal R, Navas-Carretero S, Martinez-Gonzalez MA, Ordovas JM, Martinez JA. Contribution of macronutrients to obesity: implications for precision nutrition. *Nat Rev Endocrinol* 2020;16:305–20.
- Blüher M. Obesity: global epidemiology and pathogenesis. *Nat Rev Endocrinol* 2019;15:288–98.
- Liu X, Yao Z. Chronic over-nutrition and dysregulation of GSK3 in diseases. *Nutr Metab* 2016;13:49.
- Gonzalez-Muniesa P, Garcia-Gerique L, Quintero P, Arriaza S, Lopez-Pascual A, Martinez JA. Effects of hyperoxia on oxygen-related inflammation with a focus on obesity. *Oxid Med Cell Longev* 2015;2015:8957827.
- Bach Knudsen KE, Laerke HN, Hedemann MS, Nielsen TS, Ingerslev AK, Gundelund Nielsen DS, et al. Impact of diet-modulated butyrate production on intestinal barrier function and inflammation. *Nutrients* 2018;10:1499.
- Madeo F, Carmona-Gutierrez D, Hofer SJ, Kroemer G. Caloric restriction mimetics against age-associated disease: targets, mechanisms, and therapeutic potential. *Cell Metabol* 2019;29:592–610.
- Kokten T, Hansmann F, Ndiaye NC, Heba AC, Quilliot D, Dreumont N, et al. Calorie restriction as a new treatment of inflammatory diseases. *Adv Nutr* 2021;12:1558–70.
- Hever J, Cronise RJ. Plant-based nutrition for healthcare professionals: implementing diet as a primary modality in the prevention and treatment of chronic disease. *J Geriatr Cardiol* 2017;14:355–68.



- [44] Department of Health. Dietary reference values for food energy and nutrients for the United Kingdom. Report of the panel on dietary reference values of the committee on medical aspects of food policy. London: Her Majesty's Stationery Office; 1991.
- [45] Authority EFS. Dietary reference values for nutrients: summary report. 2017.
- [46] Institute of Medicine. Dietary reference intakes for thiamin, riboflavin, niacin, vitamin B6, folate, vitamin B12, pantothenic acid, biotin, and choline. Washington, DC: National Academy Press; 1998.
- [47] Institute of Medicine. Dietary reference intakes for vitamin C, vitamin E, selenium, and carotenoids. Washington, DC: National Academy Press; 2000.
- [48] Institute of Medicine. Dietary reference intakes for vitamin A, vitamin K, arsenic, boron, chromium, copper. In: Iodine, iron, manganese, molybdenum, nickel, silicon, vanadium, and zinc. Washington, DC: National Academy Press; 2001.
- [49] Institute of Medicine. Dietary reference intakes for calcium, phosphorus, magnesium, vitamin D, and fluoride. Washington, DC: National Academy Press; 1997.
- [50] Prentice A. Sex differences in requirements for micronutrients across the lifecycle. *Proc Nutr Soc* 2021;80:356–64.
- [51] Kittler PG, Sucher KP, Nelms M. Food and culture. Cengage Learning; 2016.
- [52] Kim MJ, Lee SJ, Ahn YH, Bowen P, Lee H. Dietary acculturation and diet quality of hypertensive Korean Americans. *J Adv Nurs* 2007;58:436–45.
- [53] Ritenbaugh C, Szathmary EJE, Goodby CS, Feldman C. Dietary acculturation among the dogrib Indians of the Canadian northwest territories. *Ecol Food Nutr* 1996;35:81–94.
- [54] Shannon C. Acculturation: aboriginal and torres strait islander nutrition. *Asia Pac J Clin Nutr* 2002;11(Suppl 3):S576–8.
- [55] Tupai-Firestone R, Cheng S, Kaholokula J, Borman B, Ellison-Loschmann L. Investigating differences in dietary patterns among a small cross-sectional study of young and old Pacific peoples in NZ using exploratory factor analysis: a feasibility study. *BMJ Open* 2019;9:e023126.
- [56] Soto SH, Arredondo EM, Marcus B, Shakya HB, Roesch S, Ayala GX. Effects of Latino children on their mothers' dietary intake and dietary behaviors: the role of children's acculturation and the mother-child acculturation gap. *Soc Sci Med* 2017;191:125–33.
- [57] Perez-Escamilla R. Acculturation, nutrition, and health disparities in Latinos. *Am J Clin Nutr* 2011;93: 1163S-7S.
- [58] Akresh IR. Dietary assimilation and immigrant health. Bonn, Germany: Third IZA Annual Migration Meeting, IZA Institute for the Study of Labor; 2006. May Eastern Sociological Society Annual Meeting, Boston MA, February: Citeseer.
- [59] Allen L, Williams J, Townsend N, Mikkelsen B, Roberts N, Foster C, et al. Socioeconomic status and non-communicable disease behavioural risk factors in low-income and lower-middle-income countries: a systematic review. *Lancet Global Health* 2017;5:e277–89.
- [60] Arthur Schatzkin M. Dietary diversity in the US population, NHANES II, 1976–1980. *J Am Diet Assoc* 1991;91:1526–31.
- [61] Raffensperger S, Kuczmarowski MF, Hotchkiss L, Cotugna N, Evans MK, Zonderman AB. Effect of race and predictors of socioeconomic status on diet quality in the HANDLS Study sample. *J Natl Med Assoc* 2010;102:923–30.
- [62] Kant AK, Graubard BI. Secular trends in the association of socio-economic position with self-reported dietary attributes and biomarkers in the US population: national Health and Nutrition Examination Survey (NHANES) 1971–1975 to NHANES 1999–2002. *Publ Health Nutr* 2007;10:158–67.
- [63] Mertens E, Kuijsten A, Dofkova M, Mistura L, D'Addezio L, Turrini A, et al. Geographic and socioeconomic diversity of food and nutrient intakes: a comparison of four European countries. *Eur J Nutr* 2019;58:1475–93.
- [64] Janssen HG, Davies IG, Richardson LD, Stevenson L. Determinants of takeaway and fast food consumption: a narrative review. *Nutr Res Rev* 2018;31:16–34.
- [65] Shi Z, Lien N, Kumar BN, Holmboe-Ottesen G. Socio-demographic differences in food habits and preferences of school adolescents in Jiangsu Province, China. *Eur J Clin Nutr* 2005;59:1439–48.
- [66] Martinez-Gonzalez MA, Martin-Calvo N. Mediterranean diet and life expectancy: beyond olive oil, fruits, and vegetables. *Curr Opin Clin Nutr Metab Care* 2016;19: 401–7.
- [67] Mariamenatu AH, Abdu EM. Overconsumption of omega-6 polyunsaturated fatty acids (PUFAs) versus deficiency of omega-3 PUFAs in modern-day diets: the disturbing factor for their "balanced antagonistic metabolic functions" in the human body. *J Lipids* 2021;2021:8848161.
- [68] Dartt DA, Hodges RR, Serhan CN. Immunoresolvent resolvin D1 maintains the health of the ocular surface. *Adv Exp Med Biol* 2019;1161:13–25.
- [69] Erdinest N, Ovadia H, Kormas R, Solomon A. Anti-inflammatory effects of resolvin-D1 on human corneal epithelial cells: in vitro study. *J Inflamm* 2014;11: 6.
- [70] Li N, He J, Schwartz CE, Gjørstrup P, Bazan HE. Resolvin E1 improves tear production and decreases inflammation in a dry eye mouse model. *J Ocul Pharmacol Therapeut* 2010;26:431–9.
- [71] Serhan CN. Novel lipid mediators and resolution mechanisms in acute inflammation: to resolve or not? *Am J Pathol* 2010;177:1576–91.
- [72] Pellegrini M, Senni C, Bernabei F, Cicero AFG, Vagge A, Maestri A, et al. The role of nutrition and nutritional supplements in ocular surface diseases. *Nutrients* 2020;12:952.
- [73] Britten-Jones AC, Craig JP, Anderson AJ, Downie LE. Association between systemic omega-3 polyunsaturated fatty acid levels, and corneal nerve structure and function. *Eye* 2022. <https://doi.org/10.1038/s41433-022-02259-0>. Online ahead of print.
- [74] Miljanovic B, Trivedi KA, Dana MR, Gilbard JP, Buring JE, Schaumberg DA. Relation between dietary n-3 and n-6 fatty acids and clinically diagnosed dry eye syndrome in women. *Am J Clin Nutr* 2005;82:887–93.
- [75] Jones L, Downie LE, Korb D, Benitez-Del-Castillo JM, Dana R, Deng SX, et al. TFOS DEWS II management and therapy report. *Ocul Surf* 2017;15:575–628.
- [76] Bhargava R, Kumar P. Oral omega-3 fatty acid treatment for dry eye in contact lens wearers. *Cornea* 2015;34:413–20.
- [77] Deinema LA, Vingrys AJ, Wong CY, Jackson DC, Chinnery HR, Downie LE. A randomized, double-masked, placebo-controlled clinical trial of two forms of omega-3 supplements for treating dry eye disease. *Ophthalmology* 2017;124: 43–52.
- [78] Hussain M, Shtein RM, Pistilli M, Maguire MG, Oydanchik M, Asbell PA, et al. The Dry Eye Assessment and Management (DREAM) extension study - a randomized clinical trial of withdrawal of supplementation with omega-3 fatty acid in patients with dry eye disease. *Ocul Surf* 2020;18:47–55.
- [79] Assessment DE, Group MSR. n-3 Fatty acid supplementation for the treatment of dry eye disease. *N Engl J Med* 2018;378:1681–90.
- [80] Bhargava R, Kumar P, Phogat H, Kaur A, Kumar M. Oral omega-3 fatty acids treatment in computer vision syndrome related dry eye. *Contact Lens Anterior Eye* 2015;38:206–10.
- [81] Chinnery HR, Naranjo Golborne C, Downie LE. Omega-3 supplementation is neuroprotective to corneal nerves in dry eye disease: a pilot study. *Ophthalmic Physiol Opt* 2017;37:473–81.
- [82] Guo X, Tresserra-Rimbau A, Estruch R, Martinez-Gonzalez MA, Medina-Remon A, Castaner O, et al. Effects of polyphenol, measured by a biomarker of total polyphenols in urine, on cardiovascular risk factors after a long-term follow-up in the PREDIMED study. *Oxid Med Cell Longev* 2016;2016:2572606.
- [83] Jalbert I. Diet, nutraceuticals and the tear film. *Exp Eye Res* 2013;117:138–46.
- [84] Willett WC, Koplan JP, Nugent R, Dusenbury C, Puska P, Gaziano TA. Prevention of chronic disease by means of diet and lifestyle changes. In: Disease control priorities in developing countries. second ed. 2006.
- [85] Mozaffarian D, Pischon T, Hankinson SE, Rifai N, Joshipura K, Willett WC, et al. Dietary intake of trans fatty acids and systemic inflammation in women. *Am J Clin Nutr* 2004;79:606–12.
- [86] Hu FB, van Dam RM, Liu S. Diet and risk of Type II diabetes: the role of types of fat and carbohydrate. *Diabetologia* 2001;44:805–17.
- [87] Neacsu N, Madar A. Artificial sweeteners versus natural sweeteners, vol. 7. Bulletin of the Transilvania University of Brasov Economic Sciences Series V; 2014. p. 59.
- [88] Bray GA, Nielsen SJ, Popkin BM. Consumption of high-fructose corn syrup in beverages may play a role in the epidemic of obesity. *Am J Clin Nutr* 2004;79: 537–43.
- [89] Gardner C, Wylie-Rosett J, Gidding SS, Steffen LM, Johnson RK, Reader D, et al. Nonnutritive sweeteners: current use and health perspectives: a scientific statement from the American Heart Association and the American Diabetes Association. *Circulation* 2012;126:509–19.
- [90] Chi L, Bian X, Gao B, Tu P, Lai Y, Ru H, et al. Effects of the artificial sweetener neotame on the gut microbiome and fecal metabolites in mice. *Molecules* 2018; 23:367.
- [91] Tavakoli A, Flanagan JL. Dry eye disease: an (in)convenient truth. *Clin Exp Optom* 2022;105:222–9.
- [92] Henriques HKF, Fonseca LM, de Andrade KS, Shivappa N, Hebert JR, Ferreira AVM, et al. Gluten-free diet reduces diet quality and increases inflammatory potential in non-celiac healthy women. *J Am Coll Nutr* 2021;1–9.
- [93] Garcia-Mazcorro JF, Noratto G, Remes-Troche JM. The effect of gluten-free diet on health and the gut microbiota cannot be extrapolated from one population to others. *Nutrients* 2018;10:1421.
- [94] Uzel MM, Citirik M, Kekilli M, Cicek P. Local ocular surface parameters in patients with systemic celiac disease. *Eye* 2017;31:1093–8.
- [95] UNICEF. The state of the world's children 2019: children, food and nutrition. <http://data.unicef.org/resources/state-of-the-worlds-children-2019/2019>.
- [96] Fogagnolo P, De Cilla S, Alkabes M, Sabella P, Rossetti L. A review of topical and systemic vitamin supplementation in ocular surface diseases. *Nutrients* 2021;13.
- [97] Marriott BP, Birt DF, Stalling VA, Yates AA. Present knowledge in nutrition: basic nutrition and metabolism. Academic Press; 2020.
- [98] Ashkar S, Mesentsev A, Zhang WX, Mastuygin V, Dunn MW, Laniado-Schwartzman M. Retinoic acid induces corneal epithelial CYP4B1 gene expression and stimulates the synthesis of inflammatory 12-hydroxyeicosanoids. *J Ocul Pharmacol Therapeut* 2004;20:65–74.
- [99] Tei M, Spurr-Michaud SJ, Tisdale AS, Gipson IK. Vitamin A deficiency alters the expression of mucin genes by the rat ocular surface epithelium. *Invest Ophthalmol Vis Sci* 2000;41:82–8.
- [100] Ubels JL, Wertz JT, Ingersoll KE, Jackson 2nd RS, Aupperlee MD. Down-regulation of androgen receptor expression and inhibition of lacrimal gland cell proliferation by retinoic acid. *Exp Eye Res* 2002;75:561–71.
- [101] Toshino A, Shiraishi A, Zhang W, Suzuki A, Kodama T, Ohashi Y. Expression of keratinocyte transglutaminase in cornea of vitamin A-deficient rats. *Curr Eye Res* 2005;30:731–9.
- [102] Gomez JAP. TFOS Lifestyle: Impact of elective medications and procedures on the ocular surface. *Ocul Surf* 2023. In press.
- [103] Knop E, Knop N, Millar T, Obata H, Sullivan DA. The international workshop on meibomian gland dysfunction: report of the subcommittee on anatomy, physiology, and pathophysiology of the meibomian gland. *Invest Ophthalmol Vis Sci* 2011;52:1938–78.



- [104] Fiore P, De Marco R, Sacco O, Priolo E. Nightblindness, xerophthalmia, and severe loss of visual acuity due to unnecessary dietary restriction. *Nutrition* 2004; 20:477.
- [105] Martini S, Rizzello A, Corsini I, Romanin B, Fiorentino M, Grandi S, et al. Vitamin A deficiency due to selective eating as a cause of blindness in a high-income setting. *Pediatrics* 2018;141:S439–44.
- [106] Sommer A. Xerophthalmia and vitamin A status. *Prog Retin Eye Res* 1998;17: 9–31.
- [107] Wittmann JR, Tseng SC, Sommer A. Detection of early xerophthalmia by impression cytology. *Arch Ophthalmol* 1986;104:237–9.
- [108] Giannaccare G, Lucisano A, Pellegrini M, Scordia V. Sterile corneal perforation occurring several years after biliopancreatic diversion. *Obes Surg* 2020;30: 2847–50.
- [109] Reynolds E. Vitamin B12, folic acid, and the nervous system. *Lancet Neurol* 2006; 5:949–60.
- [110] Shipton MJ, Thachil J. Vitamin B12 deficiency - a 21st century perspective. *Clin Med* 2015;15:145–50.
- [111] Vehof J, Snieder H, Jansonius N, Hammond CJ. Prevalence and risk factors of dry eye in 79,866 participants of the population-based Lifelines cohort study in The Netherlands. *Ocul Surf* 2021;19:83–93.
- [112] Li Y, Schellhorn HE. New developments and novel therapeutic perspectives for vitamin C. *J Nutr* 2007;137:2171–84.
- [113] Iqbal K, Khan A, Khattak M. Biological significance of ascorbic acid (vitamin C) in human health-a review. *Pakistan J Nutr* 2004;3:5–13.
- [114] Carr AC, Frei B. Toward a new recommended dietary allowance for vitamin C based on antioxidant and health effects in humans. *Am J Clin Nutr* 1999;69: 1086–107.
- [115] Paterson CA, O'Rourke MC. Vitamin C levels in human tears. *Arch Ophthalmol* 1987;105:376–7.
- [116] Saika S, Uenoyama K, Hiroi K, Tanioka H, Takase K, Hikita M. Ascorbic acid phosphate ester and wound healing in rabbit corneal alkali burns: epithelial basement membrane and stroma. *Graefes Arch Clin Exp Ophthalmol* 1993;231: 221–7.
- [117] Kamen DL, Tangpricha V. Vitamin D and molecular actions on the immune system: modulation of innate and autoimmunity. *J Mol Med (Berl)* 2010;88: 441–50.
- [118] Sethu S, Shetty R, Deshpande K, Pahuja N, Chinnappaiah N, Agarwal A, et al. Correlation between tear fluid and serum vitamin D levels. *Eye Vis (Lond)*. 2016; 3:22.
- [119] Yin Z, Pinteau V, Lin Y, Hammock BD, Watsky MA. Vitamin D enhances corneal epithelial barrier function. *Invest Ophthalmol Vis Sci* 2011;52:7359–64.
- [120] Yoon SY, Bae SH, Shin YJ, Park SG, Hwang SH, Hyon JY, et al. Low serum 25-hydroxyvitamin D levels are associated with dry eye syndrome. *PLoS One* 2016; 11:e0147847.
- [121] Diki S, Akatli AN, Yildirim T. Conjunctival impression cytology and tear-film changes in cases with vitamin D deficiency. *Int Ophthalmol* 2020;40:1687–94.
- [122] Huang JY, Yeh PT, Hou YC. A randomized, double-blind, placebo-controlled study of oral antioxidant supplement therapy in patients with dry eye syndrome. *Clin Ophthalmol* 2016;10:813–20.
- [123] Jin KW, Ro JW, Shin YJ, Hyon JY, Wee WR, Park SG. Correlation of vitamin D levels with tear film stability and secretion in patients with dry eye syndrome. *Acta Ophthalmol* 2017;95:e230–5.
- [124] Kuo CY, Huang YC, Lin KJ, Tsai TY. Vitamin D deficiency is associated with severity of dry eye symptoms and primary Sjogren's syndrome: a systematic review and meta-analysis. *J Nutr Sci Vitaminol* 2020;66:386–8.
- [125] Liu J, Dong Y, Wang Y. Vitamin D deficiency is associated with dry eye syndrome: a systematic review and meta-analysis. *Acta Ophthalmol* 2020;98:749–54.
- [126] Askari G, Rafie N, Miraghajani M, Heidari Z, Arab A. Association between vitamin D and dry eye disease: a systematic review and meta-analysis of observational studies. *Contact Lens Anterior Eye* 2020;43:418–25.
- [127] Labunskyy VM, Hatfield DL, Gladyshev VN. Selenoproteins: molecular pathways and physiological roles. *Physiol Rev* 2014;94:739–77.
- [128] Higuchi A, Takahashi K, Hirashima M, Kawakita T, Tsubota K. Selenoprotein P controls oxidative stress in cornea. *PLoS One* 2010;5:e9911.
- [129] Sonobe H, Ogawa Y, Yamada K, Shimizu E, Uchino Y, Kamoi M, et al. A novel and innovative paper-based analytical device for assessing tear lactoferrin of dry eye patients. *Ocul Surf* 2019;17:160–6.
- [130] Bamdad S, Owji N, Bolkheir A. Association between advanced keratoconus and serum levels of zinc, calcium, magnesium, iron, copper, and selenium. *Cornea* 2018;37:1306–10.
- [131] Jequier E, Constant F. Water as an essential nutrient: the physiological basis of hydration. *Eur J Clin Nutr* 2010;64:115–23.
- [132] Murray B. Hydration and physical performance. *J Am Coll Nutr* 2007;26: 542S–8S.
- [133] Masento NA, Golightly M, Field DT, Butler LT, van Reekum CM. Effects of hydration status on cognitive performance and mood. *Br J Nutr* 2014;111: 1841–52.
- [134] Palma L, Marques LT, Bujan J, Rodrigues LM. Dietary water affects human skin hydration and biomechanics. *Clin Cosmet Invest Dermatol* 2015;8:413–21.
- [135] Popkin BM, D'Anici KE, Rosenberg IH. Water, hydration, and health. *Nutr Rev* 2010;68:439–58.
- [136] Fortes MB, Diment BC, Di Felice U, Gunn AE, Kendall JL, Esmaelpour M, et al. Tear fluid osmolality as a potential marker of hydration status. *Med Sci Sports Exerc* 2011;43:1590–7.
- [137] Walsh NP, Fortes MB, Raymond-Barker P, Bishop C, Owen J, Tye E, et al. Is whole-body hydration an important consideration in dry eye? *Invest Ophthalmol Vis Sci* 2012;53:6622–7.
- [138] Osei KA, Oveneri-Ogbomo G, Kyei S, Ntodie M. The effect of caffeine on tear secretion. *Optom Vis Sci* 2014;91:171–7.
- [139] Nguyen L, Magno MS, Utheim TP, Jansonius NM, Hammond CJ, Vehof J. The relationship between habitual water intake and dry eye disease. *Acta Ophthalmol* 2023;101:65–73.
- [140] Yeo S, Tong L. Coping with dry eyes: a qualitative approach. *BMC Ophthalmol* 2018;18:8.
- [141] Alves M. TFOS Lifestyle: Impact of environmental challenges on the ocular surface. *Ocul Surf* 2023. In press.
- [142] Gore AC. Endocrine-disrupting chemicals. *JAMA Intern Med* 2016;176:1705–6.
- [143] Yilmaz B, Terekci H, Sandal S, Kelestimur F. Endocrine disrupting chemicals: exposure, effects on human health, mechanism of action, models for testing and strategies for prevention. *Rev Endocr Metab Disord* 2020;21:127–47.
- [144] Sullivan DA, Rocha EM, Aragona P, Clayton JA, Ding J, Golebiowski B, et al. TFOS DEWS II sex, gender, and hormones report. *Ocul Surf* 2017;15:284–333.
- [145] Bank MS. The mercury science-policy interface: history, evolution and progress of the Minamata Convention. *Sci Total Environ* 2020;722:137832.
- [146] Mousavi SE, Delgado-Saborit JM, Adivi A, Pauwels S, Godderis L. Air pollution and endocrine disruptors induce human microbiome imbalances: a systematic review of recent evidence and possible biological mechanisms. *Sci Total Environ* 2022;816:151654.
- [147] Stanaway IB, Wallace JC, Shojai A, Griffith WC, Hong S, Wilder CS, et al. Human oral buccal microbiomes are associated with farmworker status and azinphos-methyl agricultural pesticide exposure. *Appl Environ Microbiol* 2017;83.
- [148] Alonso-Magdalena P, Ropero AB, Soriano S, Garcia-Arevalo M, Ripoll C, Fuentes E, et al. Bisphenol-A acts as a potent estrogen via non-classical estrogen triggered pathways. *Mol Cell Endocrinol* 2012;355:201–7.
- [149] Wang J, She C, Li Z, Tang N, Xu L, Liu Z, et al. In vitro impact of bisphenol A on maturation and function of monocyte-derived dendritic cells in patients with primary Sjogren's syndrome. *Immunopharmacol Immunotoxicol* 2020;42:28–36.
- [150] Pontelli RCN, Rocha BA, Garcia DM, Pereira LA, Souza MCO, Barbosa Jr F, et al. Endocrine disrupting chemicals associated with dry eye syndrome. *Ocul Surf* 2020;18:487–93.
- [151] Sullivan DA. TFOS Lifestyle: Impact of cosmetics on the ocular surface. *Ocul Surf* 2023. In press.
- [152] Canadas P, Lantigua Y, Enriquez-de-Salamanca A, Fernandez I, Pastor-Idoate S, Sobas EM, et al. Ocular surface pathology in patients suffering from mercury intoxication. *Diagnostics* 2021;11.
- [153] Chung SH, Myong JP. Are higher blood mercury levels associated with dry eye symptoms in adult Koreans? A population-based cross-sectional study. *BMJ Open* 2016;6:e010985.
- [154] Jung SJ, Lee SH. Association between three heavy metals and dry eye disease in Korean adults: results of the Korean national health and nutrition examination survey. *Kor J Ophthalmol* 2019;33:26–35.
- [155] Han K, Ju MJ, Kim DH, Choi YH. Environmental exposures to lead, cadmium, and mercury and pterygium in Korean adults. *Environ Sci Pollut Res Int* 2022;29: 55058–68.
- [156] Kim JH, Kim JH, Nam WH, Yi K, Choi DG, Hyon JY, et al. Oral alcohol administration disturbs tear film and ocular surface. *Ophthalmology* 2012;119: 965–71.
- [157] Simsek C, Kojima T, Dogru M, Tanaka M, Takano Y, Wakamatsu T, et al. The early effects of alcohol consumption on functional visual acuity, tear functions, and the ocular surface. *Eye Contact Lens* 2021;47:20–6.
- [158] You YS, Qu NB, Yu XN. Alcohol consumption and dry eye syndrome: a Meta-analysis. *Int J Ophthalmol* 2016;9:1487–92.
- [159] Magno MS, Daniel T, Morthen MK, Snieder H, Jansonius N, Utheim TP, et al. The relationship between alcohol consumption and dry eye. *Ocul Surf* 2021;21:87–95.
- [160] Gonzalez-Quintela A, Vidal C, Gude F. Alcohol, IgE and allergy. *Addiction Biol* 2004;9:195–204.
- [161] Pasko P, Rodacki T, Domagala-Rodacka R, Palimonka K, Marcinkowska M, Owczarek D. Second generation H1 - antihistamines interaction with food and alcohol-A systematic review. *Biomed Pharmacother* 2017;93:27–39.
- [162] Galor A. TFOS Lifestyle: Impact of lifestyle challenges on the ocular surface. *Ocul Surf* 2023. In press.
- [163] Chakraborty SP. Patho-physiological and toxicological aspects of monosodium glutamate. *Toxicol Mech Methods* 2019;29:389–96.
- [164] Baranowska-Wojcik E, Szwajgier D, Oleszczuk P, Winiarska-Mieczan A. Effects of titanium dioxide nanoparticles exposure on human health-a review. *Biol Trace Elem Res* 2020;193:118–29.
- [165] Cox S, Sandall A, Smith L, Rossi M, Whelan K. Food additive emulsifiers: a review of their role in foods, legislation and classifications, presence in food supply, dietary exposure, and safety assessment. *Nutr Rev* 2021;79:726–41.
- [166] Arita R, Yanagi Y, Honda N, Maeda S, Maeda K, Kuchiba A, et al. Caffeine increases tear volume depending on polymorphisms within the adenosine A2a receptor gene and cytochrome P450 1A2. *Ophthalmology* 2012;119:972–8.
- [167] Magno MS, Utheim TP, Morthen MK, Snieder H, Jansonius NM, Hammond CJ, et al. The relationship between caffeine intake and dry eye disease. *Cornea* 2023; 42:186–93.
- [168] Jeong KJ, Choi JG, Park EJ, Kim HE, Yoo SM, Park SG. Relationship between dry eye syndrome and frequency of coffee consumption in Korean adults: Korea national health and nutrition examination survey V, 2010-2012. *Korean J Fam Med* 2018;39:290–4.

- [169] Wang MTM, Muntz A, Mamidi B, Wolffsohn JS, Craig JP. Modifiable lifestyle risk factors for dry eye disease. *Contact Lens Anterior Eye* 2021;44:101409.
- [170] Alshamrani AA, Almousa AS, Almulhim AA, Alafaleq AA, Alosaimi MB, Alqahatani AM, et al. Prevalence and risk factors of dry eye symptoms in a Saudi arabian population. *Middle East Afr J Ophthalmol* 2017;24:67–73.
- [171] Chia EM, Mitchell P, Rochtchina E, Lee AJ, Maroun R, Wang JJ. Prevalence and associations of dry eye syndrome in an older population: the Blue Mountains Eye Study. *Clin Exp Ophthalmol* 2003;31:229–32.
- [172] Inomata T, Nakamura M, Iwagami M, Shiang T, Yoshimura Y, Fujimoto K, et al. Risk factors for severe dry eye disease: crowdsourced research using DryEyeRhythm. *Ophthalmology* 2019;126:766–8.
- [173] Moss SE, Klein R, Klein BE. Incidence of dry eye in an older population. *Arch Ophthalmol* 2004;122:369–73.
- [174] Moss SE, Klein R, Klein BE. Long-term incidence of dry eye in an older population. *Optom Vis Sci* 2008;85:668–74.
- [175] Moss SE, Klein R, Klein BE. Prevalence of and risk factors for dry eye syndrome. *Arch Ophthalmol* 2000;118:1264–8.
- [176] Jimenez R, Molina R, Redondo B, Vera J. Effects of caffeine intake on the biomechanical properties of the cornea: a placebo-controlled, double-blind, crossover pilot study in low caffeine consumers. *Graefes Arch Clin Exp Ophthalmol* 2020;258:2449–58.
- [177] Barati M, Jabbari M, Navekar R, Farahmand F, Zeinalian R, Salehi-Sahlabadi A, et al. Collagen supplementation for skin health: a mechanistic systematic review. *J Cosmet Dermatol* 2020;19:2820–9.
- [178] Choi FD, Sung CT, Juhasz ML, Mesinkovsk NA. Oral collagen supplementation: a systematic review of dermatological applications. *J Drugs Dermatol JDD* 2019;18:9–16.
- [179] de Miranda RB, Weimer P, Rossi RC. Effects of hydrolyzed collagen supplementation on skin aging: a systematic review and meta-analysis. *Int J Dermatol* 2021;60:1449–61.
- [180] Garcia-Coronado JM, Martinez-Olvera L, Elizondo-Omana RE, Acosta-Olivo CA, Vilchez-Cavazos F, Simental-Mendia LE, et al. Effect of collagen supplementation on osteoarthritis symptoms: a meta-analysis of randomized placebo-controlled trials. *Int Orthop* 2019;43:531–8.
- [181] Khatri M, Naughton RJ, Clifford T, Harper LD, Corr L. The effects of collagen peptide supplementation on body composition, collagen synthesis, and recovery from joint injury and exercise: a systematic review. *Amino Acids* 2021;53:1493–506.
- [182] Bennion M, Scheule B. *Introductory foods*. Pearson; 2010.
- [183] Liu X, Gao C, Liu X, Gao T. Efficacy and safety of tripterygium glycosides for Graves ophthalmopathy: a systematic review and meta-analysis. *Medicine (Baltim)* 2019;98:e18242.
- [184] Li H, Zheng P, Min J, Zhang Y, Wang W, Zhang J, et al. A prospective randomized controlled clinical trial of Pingmu Decoction combined with acupuncture in the treatment of non-active thyroid-related ophthalmopathy. *Medicine (Baltim)* 2020;99:e23734.
- [185] Chang YH, Lin HJ, Li WC. Clinical evaluation of the traditional Chinese prescription Chi-Ju-Di-Huang-Wan for dry eye. *Phytother Res* 2005;19:349–54.
- [186] Wu SQ, Dai Q, Xu JL, Sheng WY, Xu QB, Zhong LY. Combined effect of traditional Chinese and Western medicine on inflammatory factors in patients with diabetes-induced xerophthalmia. *Genet Mol Res* 2016;15.
- [187] Nagaki Y, Hayasaka S, Hayasaka Y, Kadoi C, Sekiya N, Terasawa K, et al. Effects of goshajinkigan on corneal sensitivity, superficial punctate keratopathy and tear secretion in patients with insulin-dependent diabetes mellitus. *Am J Chin Med* 2003;31:103–9.
- [188] Ahmed S, Sulaiman SA, Baig AA, Ibrahim M, Liaqat S, Fatima S, et al. Honey as a potential natural antioxidant medicine: an insight into its molecular mechanisms of action. *Oxid Med Cell Longev* 2018;2018:8367846.
- [189] Albiets JM, Schmid KL. Randomised controlled trial of topical antibacterial Manuka (*Leptospermum* species) honey for evaporative dry eye due to meibomian gland dysfunction. *Clin Exp Optom* 2017;100:603–15.
- [190] Craig JP, Cruzat A, Cheung IMY, Watters GA, Wang MTM. Randomized masked trial of the clinical efficacy of MGO Manuka Honey microemulsion eye cream for the treatment of blepharitis. *Ocul Surf* 2020;18:170–7.
- [191] Craig JP, Wang MTM, Ganesalingam K, Rupenthal ID, Swift S, Loh CS, et al. Randomised masked trial of the clinical safety and tolerability of MGO Manuka Honey eye cream for the management of blepharitis. *BMJ Open Ophthalmol* 2017;1:e000066.
- [192] Li AL, Li SL, Kam KW, Young AL. Randomised assessor-masked trial evaluating topical manuka honey (Optimel) in treatment of meibomian gland dysfunction. *Br J Ophthalmol* 2022;106:777–80.
- [193] Malhotra R, Ziahosseini K, Poitelea C, Litwin A, Sagili S. Effect of manuka honey on eyelid wound healing: a randomized controlled trial. *Ophthalmic Plast Reconstr Surg* 2017;33:268–72.
- [194] Salehi A, Jabbarzare S, Neurmohamadi M, Kheiri S, Rafieian-Kopaei M. A double blind clinical trial on the efficacy of honey drop in vernal keratoconjunctivitis. *Evid Based Complement Alternat Med* 2014;2014:287540.
- [195] Tan J, Jia T, Liao R, Stapleton F. Effect of a formulated eye drop with *Leptospermum* spp honey on tear film properties. *Br J Ophthalmol* 2020;104:1373–7.
- [196] Wong D, Albiets JM, Tran H, Du Toit C, Li AH, Yun T, et al. Treatment of contact lens related dry eye with antibacterial honey. *Contact Lens Anterior Eye* 2017;40:389–93.
- [197] Nejabat M, Soltanzadeh K, Yasemi M, Daneshamouz S, Akbarizadeh AR, Heydari M. Efficacy of honey-based ophthalmic formulation in patients with corneal ulcer: a randomized clinical trial. *Curr Drug Discov Technol* 2021;18:457–62.
- [198] Inoue S, Kawashima M, Hisamura R, Imada T, Izuta Y, Nakamura S, et al. Clinical evaluation of a royal jelly supplementation for the restoration of dry eye: a prospective randomized double blind placebo controlled study and an experimental mouse model. *PLoS One* 2017;12:e0169069.
- [199] Rajan TV, Tennen H, Lindquist RL, Cohen L, Clive J. Effect of ingestion of honey on symptoms of rhinoconjunctivitis. *Ann Allergy Asthma Immunol* 2002;88:198–203.
- [200] Saarinen K, Jantunen J, Haahtela T. Birch pollen honey for birch pollen allergy—a randomized controlled pilot study. *Int Arch Allergy Immunol* 2011;155:160–6.
- [201] Kawashima M, Nakamura S, Izuta Y, Inoue S, Tsubota K. Dietary supplementation with a combination of lactoferrin, fish oil, and *Enterococcus faecium* WB2000 for treating dry eye: a rat model and human clinical study. *Ocul Surf* 2016;14:255–63.
- [202] Brignole-Baudouin F, Baudouin C, Aragona P, Rolando M, Labetoulle M, Pisella PJ, et al. A multicentre, double-masked, randomized, controlled trial assessing the effect of oral supplementation of omega-3 and omega-6 fatty acids on a conjunctival inflammatory marker in dry eye patients. *Acta Ophthalmol* 2011;89:e591–7.
- [203] Blades KJ, Patel S, Aidoo KE. Oral antioxidant therapy for marginal dry eye. *Eur J Clin Nutr* 2001;55:589–97.
- [204] Drouault-Holowacz S, Bieuvelet S, Burckel A, Rigal D, Dubray C, Lichon JL, et al. Antioxidants intake and dry eye syndrome: a crossover, placebo-controlled, randomized trial. *Eur J Ophthalmol* 2009;19:337–42.
- [205] Dogru M, Matsumoto Y, Yamamoto Y, Goto E, Saiki M, Shimazaki J, et al. Lactoferrin in Sjogren's syndrome. *Ophthalmology* 2007;114:2366–7.
- [206] Higuichi A, Inoue H, Kaneko Y, Oonishi E, Tsubota K. Selenium-binding lactoferrin is taken into corneal epithelial cells by a receptor and prevents corneal damage in dry eye model animals. *Sci Rep* 2016;6:36903.
- [207] Cao J, Su Y, Chen Z, Ma C, Xiong W. The risk factors for Graves' ophthalmopathy. *Graefes Arch Clin Exp Ophthalmol* 2022;260:1043–54.
- [208] Winther KH, Bonnema SJ, Hegedus L. Is selenium supplementation in autoimmune thyroid diseases justified? *Curr Opin Endocrinol Diabetes Obes* 2017;24:348–55.
- [209] Yu MG, Faltado A, Acampado LR. Efficacy of selenium supplementation on autoantibody titers in Graves' ophthalmopathy. *Philippine J Intern Med* 2017;55:1.
- [210] Winther KH, Papini E, Attanasio R, Negro R, Hegedus LA. European thyroid association survey on the use of selenium supplementation in hashimoto's thyroiditis. *Eur Thyroid J* 2018;9:99–105. 2020.
- [211] Park J, Yoo YS, Shin E, Han G, Shin K, Lim DH, et al. Effects of the re-esterified triglyceride (rTG) form of omega-3 supplements on dry eye following cataract surgery. *Br J Ophthalmol* 2021;105:1504–9.
- [212] Jo YJ, Lee JS. Effects of dietary high dose DHA omega-3 supplement in dry eye with meibomian gland dysfunction. *Int J Ophthalmol* 2021;14:1700–6.
- [213] Macsai MS. The role of omega-3 dietary supplementation in blepharitis and meibomian gland dysfunction (an AOS thesis). *Trans Am Ophthalmol Soc* 2008;106:336–56.
- [214] Bhargava R, Kumar P, Kumar M, Mehra N, Mishra A. A randomized controlled trial of omega-3 fatty acids in dry eye syndrome. *Int J Ophthalmol* 2013;6:811–6.
- [215] Bhargava R, Kumar P, Arora Y. Short-term omega 3 fatty acids treatment for dry eye in young and middle-aged visual display terminal users. *Eye Contact Lens* 2016;42:231–6.
- [216] Bhargava R, Chandra M, Bansal U, Singh D, Ranjan S, Sharma S. A randomized controlled trial of omega 3 fatty acids in rosacea patients with dry eye symptoms. *Curr Eye Res* 2016;41:1274–80.
- [217] Malhotra C, Singh S, Chakma P, Jain AK. Effect of oral omega-3 Fatty Acid supplementation on contrast sensitivity in patients with moderate meibomian gland dysfunction: a prospective placebo-controlled study. *Cornea* 2015;34:637–43.
- [218] Kawakita T, Kawabata F, Tsuji T, Kawashima M, Shimamura S, Tsubota K. Effects of dietary supplementation with fish oil on dry eye syndrome subjects: randomized controlled trial. *Biomed Res* 2013;34:215–20.
- [219] Kangari H, Eftekhari MH, Sardari S, Hashemi H, Salamzadeh J, Ghassemi-Broumand M, et al. Short-term consumption of oral omega-3 and dry eye syndrome. *Ophthalmology* 2013;120:2191–6.
- [220] Epitropoulos AT, Donnenfeld ED, Shah ZA, Holland EJ, Gross M, Faulkner WJ, et al. Effect of oral Re-esterified omega-3 nutritional supplementation on dry eyes. *Cornea* 2016;35:1185–91.
- [221] Larmo PS, Jarvinen RL, Setälä NL, Yang B, Viitanen MH, Engblom JR, et al. Oral sea buckthorn oil attenuates tear film osmolarity and symptoms in individuals with dry eye. *J Nutr* 2010;140:1462–8.
- [222] Sheppard Jr JD, Singh R, McClellan AJ, Weikert MP, Scoper SV, Joly TJ, et al. Long-term supplementation with n-6 and n-3 PUFAs improves moderate-to-severe keratoconjunctivitis sicca: a randomized double-blind clinical trial. *Cornea* 2013;32:1297–304.
- [223] Ng A, Woods J, Jahn T, Jones LW, Sullivan Ritter J. Effect of a novel omega-3 and omega-6 fatty acid supplement on dry eye disease: a 3-month randomized controlled trial. *Optom Vis Sci* 2022;99:67–75.
- [224] Aragona P, Bucolo C, Spinella R, Giuffrida S, Ferreri G. Systemic omega-6 essential fatty acid treatment and pge1 tear content in Sjogren's syndrome patients. *Invest Ophthalmol Vis Sci* 2005;46:4474–9.
- [225] Barabino S, Rolando M, Camicione P, Ravera G, Zanardi S, Giuffrida S, et al. Systemic linoleic and gamma-linolenic acid therapy in dry eye syndrome with an inflammatory component. *Cornea* 2003;22:97–101.

- [226] Manthorpe R, Hagen Petersen S, Ju Prause. Primary Sjogren's syndrome treated with Efamol/Efavit. A double-blind cross-over investigation. *Rheumatol Int* 1984; 4:165–7.
- [227] Oxholm P, Manthorpe R, Ju Prause, Horrobin D. Patients with primary Sjogren's syndrome treated for two months with evening primrose oil. *Scand J Rheumatol* 1986;15:103–8.
- [228] Theander E, Horrobin DF, Jacobsson LT, Manthorpe R. Gammalinolenic acid treatment of fatigue associated with primary Sjogren's syndrome. *Scand J Rheumatol* 2002;31:72–9.
- [229] Kokke KH, Morris JA, Lawrenson JG. Oral omega-6 essential fatty acid treatment in contact lens associated dry eye. *Contact Lens Anterior Eye* 2008;31:141–6. ; quiz 70.
- [230] Oydanich M, Maguire MG, Pistilli M, Hamrah P, Greiner JV, Lin MC, et al. Effects of omega-3 supplementation on exploratory outcomes in the dry eye assessment and management study. *Ophthalmology* 2020;127:136–8.
- [231] Roy NS, Yu Y, Ying GS, Maguire MG, Asbell PA, Group DS. Effect of omega-3 on HLA-DR expression by conjunctival cells and tear cytokine concentrations in the dry eye assessment and management study. *Eye Contact Lens* 2022;48:384–90.
- [232] Elhamaky TR. Efficacy of omega-3 fatty acids and punctal plugs in the prevention of isotretinoin-associated ocular surface disease. *Eur J Ophthalmol* 2021;31: 2339–45.
- [233] Christen WG, Cook NR, Manson JE, Buring JE, Lee IM, Bubes V, et al. Efficacy of marine omega-3 fatty acid supplementation vs placebo in reducing incidence of dry eye disease in healthy us adults: a randomized clinical trial. *JAMA Ophthalmol* 2022;140:707–14.
- [234] James MJ, Gibson RA, Cleland LG. Dietary polyunsaturated fatty acids and inflammatory mediator production. *Am J Clin Nutr* 2000;71: 343S–8S.
- [235] Bistrian BR. n-3 fatty acid supplementation and dry eye disease. *N Engl J Med* 2018;379:690–1.
- [236] Gorzynik-Debicka M, Przychodzen P, Cappello F, Kuban-Jankowska A, Marino Gammazza A, Knap N, et al. Potential health benefits of olive oil and plant polyphenols. *Int J Mol Sci* 2018;19.
- [237] Britten-Jones AC, Kamel JT, Roberts LJ, Braat S, Craig JP, MacIsaac RJ, et al. Investigating the neuroprotective effect of oral omega-3 fatty acid supplementation in type 1 diabetes (nPROOF1): a randomized placebo-controlled trial. *Diabetes* 2021;70:1794–806.
- [238] Zhang AC, De Silva MEH, MacIsaac RJ, Roberts L, Kamel J, Craig JP, et al. Omega-3 polyunsaturated fatty acid oral supplements for improving peripheral nerve health: a systematic review and meta-analysis. *Nutr Rev* 2020;78:323–41.
- [239] Hirakata T, Lee HC, Ohba M, Saeiki K, Okuno T, Murakami A, et al. Dietary omega-3 fatty acids alter the lipid mediator profile and alleviate allergic conjunctivitis without modulating Th2 immune responses. *Faseb J* 2019;33: 3392–403.
- [240] Hirakata T, Yokomizo T, Matsuda A. The roles of omega-3 fatty acids and resolvins in allergic conjunctivitis. *Curr Opin Allergy Clin Immunol* 2019;19: 517–25.
- [241] Bays HE. Safety considerations with omega-3 fatty acid therapy. *Am J Cardiol* 2007;99:35C–43C.
- [242] Krupa K, Fritz K, Parmar M. Omega-3 fatty acids. *StatPearls*. Treasure Island (FL); 2022.
- [243] Watson PD, Joy PS, Nkonde C, Hessen SE, Karalis DG. Comparison of bleeding complications with omega-3 fatty acids + aspirin + clopidogrel-versus-aspirin + clopidogrel in patients with cardiovascular disease. *Am J Cardiol* 2009;104: 1052–4.
- [244] Akintoye E, Sethi P, Harris WS, Thompson PA, Marchioli R, Tavazzi L, et al. Fish oil and perioperative bleeding. *Circ Cardiovasc Qual Outcomes* 2018;11:e004584.
- [245] Begtrup KM, Krag AE, Hvas AM. No impact of fish oil supplements on bleeding risk: a systematic review. *Dan Med J* 2017;64:A5366.
- [246] Brasky TM, Darke AK, Song X, Tangen CM, Goodman PJ, Thompson IM, et al. Plasma phospholipid fatty acids and prostate cancer risk in the SELECT trial. *J Natl Cancer Inst* 2013;105:1132–41.
- [247] European Food Safety Authority. Scientific Opinion on the Tolerable Upper Intake Level of eicosapentaenoic acid (EPA), docosahexaenoic acid (DHA) and docosapentaenoic acid (DPA). *EFSA J* 2012;10(7):2815.
- [248] Zhang AC, Singh S, Craig JP, Downie LE. Omega-3 fatty acids and eye health: opinions and self-reported practice behaviors of optometrists in Australia and New Zealand. *Nutrients* 2020;12.
- [249] Zhang AC, Downie LE. Preliminary validation of a food frequency questionnaire to assess long-chain omega-3 fatty acid intake in eye care practice. *Nutrients* 2019;11.
- [250] Saunders AV, Davis BC, Garg ML. Omega-3 polyunsaturated fatty acids and vegetarian diets. *Med J Aust* 2013;199:S22–6.
- [251] McMonnies CW. Can dietary approaches to the treatment of dry eye disease be improved? *Ocul Surf* 2019;17:370–1.
- [252] Jiang TA. Health benefits of culinary herbs and spices. *J AOAC Int* 2019;102: 395–411.
- [253] Pescosolido N, Giannotti R, Plateroti AM, Pascarella A, Nebbioso M. Curcumin: therapeutic potential in ophthalmology. *Planta Med* 2014;80:249–54.
- [254] Liu XF, Hao JL, Xie T, Mukhtar NJ, Zhang W, Malik TH, et al. Curcumin, A potential therapeutic candidate for anterior segment eye diseases: a review. *Front Pharmacol* 2017;8:66.
- [255] Radomska-Lesniewska DM, Osiecka-Iwan A, Hyc A, Gozdz A, Dabrowska AM, Skopinski P. Therapeutic potential of curcumin in eye diseases. *Cent Eur J Immunol* 2019;44:181–9.
- [256] Bian F, Zhang MC, Zhu Y. Inhibitory effect of curcumin on corneal neovascularization in vitro and in vivo. *Ophthalmologica* 2008;222:178–86.
- [257] Pradhan N, Guha R, Chowdhury S, Nandi S, Konar A, Hazra S. Curcumin nanoparticles inhibit corneal neovascularization. *J Mol Med (Berl)* 2015;93: 1095–106.
- [258] Zhang YK, Li JM, Qin L. Suppression of corneal neovascularization by curcumin via inhibition of Wnt/beta-catenin pathway activation. *Int J Ophthalmol* 2017;10: 1791–7.
- [259] Guo C, Li M, Qi X, Lin G, Cui F, Li F, et al. Intranasal delivery of nanomicelle curcumin promotes corneal epithelial wound healing in streptozotocin-induced diabetic mice. *Sci Rep* 2016;6:29753.
- [260] Chung SH, Choi SH, Choi JA, Chuck RS, Joo CK. Curcumin suppresses ovalbumin-induced allergic conjunctivitis. *Mol Vis* 2012;18:1966–72.
- [261] Chao SC, Hu DN, Roberts J, Shen X, Lee CY, Nien CW, et al. Inhibition effect of curcumin on UVB-induced secretion of pro-inflammatory cytokines from corneal limbus epithelial cells. *Int J Ophthalmol* 2017;10:827–33.
- [262] Zhang M, Bian F, Wen C, Hao N. Inhibitory effect of curcumin on proliferation of human pterygium fibroblasts. *J Huazhong Univ Sci Technol Med Sci* 2007;27: 339–42.
- [263] Guo SP, Chang HC, Lu LS, Liu DZ, Wang TJ. Activation of kelch-like ECH-associated protein 1/nuclear factor erythroid 2-related factor 2/antioxidant response element pathway by curcumin enhances the anti-oxidative capacity of corneal endothelial cells. *Biomed Pharmacother* 2021;141:111834.
- [264] Sagiroglu T, Kanter M, Yagci MA, Sezer A, Erboğa M. Protective effect of curcumin on cyclosporin A-induced endothelial dysfunction, antioxidant capacity, and oxidative damage. *Toxicol Ind Health* 2014;30:316–27.
- [265] Radkar P, Lakshmanan PS, Mary JJ, Chaudhary S, Durairaj SK. A novel multi-ingredient supplement reduces inflammation of the eye and improves production and quality of tears in humans. *Ophthalmol Ther* 2021;10:581–99.
- [266] Muz OE, Orhan C, Erten F, Tuzcu M, Ozeran IH, Singh P, et al. A novel integrated active herbal formulation ameliorates dry eye syndrome by inhibiting inflammation and oxidative stress and enhancing glycosylated phosphoproteins in rats. *Pharmaceuticals* 2020;13.
- [267] Kurien BT, Harris VM, Quadri SM, Coutinho-de Souza P, Cavett J, Moyer A, et al. Significantly reduced lymphadenopathy, salivary gland infiltrates and proteinuria in MRL-*lpr/lpr* mice treated with ultrasoluble curcumin/turmeric: increased survival with curcumin treatment. *Lupus Sci Med* 2015;2:e000114.
- [268] Kabeerdoss J, Sandhya P, Kurien BT, Scofield RH, Danda D. In vitro effects of curcumin on proinflammatory cytokines and expression of their genes in minor salivary gland tissue of patients with Sjogren's syndrome. *Rheumatol Int* 2022;42: 545–51.
- [269] Rolando M, Valente C. Establishing the tolerability and performance of tamarind seed polysaccharide (TSP) in treating dry eye syndrome: results of a clinical study. *BMC Ophthalmol* 2007;7:5.
- [270] Barabino S, Rolando M, Nardi M, Bonini S, Aragona P, Traverso CE. The effect of an artificial tear combining hyaluronic acid and tamarind seeds polysaccharide in patients with moderate dry eye syndrome: a new treatment for dry eye. *Eur J Ophthalmol* 2014;24:173–8.
- [271] Babamohamadi H, Nobahar M, Razi J, Ghorbani R. Comparing vitamin A and moist chamber in preventing ocular surface disorders. *Clin Nurs Res* 2018;27: 714–29.
- [272] Gilbard JP, Huang AJ, Belldegrun R, Lee JS, Rossi SR, Gray KL. Open-label crossover study of vitamin A ointment as a treatment for keratoconjunctivitis sicca. *Ophthalmology* 1989;96:244–6.
- [273] Katz J, West Jr KP, Khatry SK, Thapa MD, LeClerq SC, Pradhan EK, et al. Impact of vitamin A supplementation on prevalence and incidence of xerophthalmia in Nepal. *Invest Ophthalmol Vis Sci* 1995;36:2577–83.
- [274] Mariath JG, Lima MC, Santos LM. Vitamin A activity of buriti (*Mauritia vinifera* Mart) and its effectiveness in the treatment and prevention of xerophthalmia. *Am J Clin Nutr* 1989;49:849–53.
- [275] Pirie A, Anbunathan P. Early serum changes in severely malnourished children with corneal xerophthalmia after injection of water-miscible vitamin A. *Am J Clin Nutr* 1981;34:34–40.
- [276] Sommer A, Muhilal, Tarwotjo I, Djunaedi E, Glover J. Oral versus intramuscular vitamin A in the treatment of xerophthalmia. *Lancet* 1980;1:557–9.
- [277] Kim EC, Choi JS, Joo CK. A comparison of vitamin a and cyclosporine a 0.05% eye drops for treatment of dry eye syndrome. *Am J Ophthalmol* 2009;147:206–13. e3.
- [278] Djunaedi E, Sommer A, Pandji A, Kusdiono, Taylor HR. Impact of vitamin A supplementation on xerophthalmia. A randomized controlled community trial. *Arch Ophthalmol* 1988;106:218–22.
- [279] Alanazi SA, El-Hiti GA, Al-Baloud AA, Alfahran MI, Al-Shahrani A, Albakri AA, et al. Effects of short-term oral vitamin A supplementation on the ocular tear film in patients with dry eye. *Clin Ophthalmol* 2019;13:599–604.
- [280] Sommer A, Emran N, Tamba T. Vitamin A-responsive punctate keratopathy in xerophthalmia. *Am J Ophthalmol* 1979;87:330–3.
- [281] Sommer A, Green WR. Goblet cell response to vitamin A treatment for corneal xerophthalmia. *Am J Ophthalmol* 1982;94:213–5.
- [282] Yang J, Liu Y, Xu Y, Li X, Fu J, Jiang X, et al. A new approach of ocular nebulization with vitamin B12 versus oxytocin for the treatment of dry eye disease: an in vivo confocal microscopy study. *Drug Des Dev Ther* 2019;13: 2381–91.
- [283] Macri A, Scanarotti C, Bassi AM, Giuffrida S, Sangalli G, Traverso CE, et al. Evaluation of oxidative stress levels in the conjunctival epithelium of patients with or without dry eye, and dry eye patients treated with preservative-free hyaluronic acid 0.15 % and vitamin B12 eye drops. *Graefes Arch Clin Exp Ophthalmol* 2015;253:425–30.



- [284] Wolpert LE, Snieder H, Jansonius NM, Utheim TP, Hammond CJ, Vehof J. Medication use and dry eye symptoms: a large, hypothesis-free, population-based study in The Netherlands. *Ocul Surf* 2021;22:1–12.
- [285] Peponis V, Papathanasiou M, Kapranou A, Magkou C, Tyligada A, Melidonis A, et al. Protective role of oral antioxidant supplementation in ocular surface of diabetic patients. *Br J Ophthalmol* 2002;86:1369–73.
- [286] Bae SH, Shin YJ, Kim HK, Hyon JY, Wee WR, Park SG. Vitamin D supplementation for patients with dry eye syndrome refractory to conventional treatment. *Sci Rep* 2016;6:33083.
- [287] Yang CH, Albiets J, Harkin DG, Kimlin MG, Schmid KL. Impact of oral vitamin D supplementation on the ocular surface in people with dry eye and/or low serum vitamin D. *Contact Lens Anterior Eye* 2018;41:69–76.
- [288] Hwang JS, Lee YP, Shin YJ. Vitamin D enhances the efficacy of topical artificial tears in patients with dry eye disease. *Cornea* 2019;38:304–10.
- [289] McMurray DN, Rey H, Casazza LJ, Watson RR. Effect of moderate malnutrition on concentrations of immunoglobulins and enzymes in tears and saliva of young Colombian children. *Am J Clin Nutr* 1977;30:1944–8.
- [290] Sullivan D, Soo C, Allansmith M. Severe protein malnutrition: impact on tear IgA levels during development and aging. *Ocular Immunology Today Elsevier Science Publishers*; 1990. p. 325–8.
- [291] Sullivan DA, Vaerman JP, Soo C. Influence of severe protein malnutrition on rat lacrimal, salivary and gastrointestinal immune expression during development, adulthood and ageing. *Immunology* 1993;78:308–17.
- [292] Watson RR, McMurray DN, Martin P, Reyes MA. Effect of age, malnutrition and renutrition on free secretory component and IgA in secretions. *Am J Clin Nutr* 1985;42:281–8.
- [293] Setnick J. Micronutrient deficiencies and supplementation in anorexia and bulimia nervosa: a review of literature. *Nutr Clin Pract* 2010;25:137–42.
- [294] Black DW, Grant JE. DSM-5 guidebook: the essential companion to the diagnostic and statistical manual of mental disorders. 5 ed. Arlington, VA: American Psychiatric Publishing; 2014.
- [295] Abraham SF, Banks CN, Beaumont PJ. Eye signs in patients with anorexia nervosa. *Aust J Ophthalmol* 1980;8:55–7.
- [296] Gaudiani JL, Braverman JM, Mascolo M, Mehler PS. Lagophthalmos in severe anorexia nervosa: a case series. *Arch Ophthalmol* 2012;130:928–30.
- [297] Agrawal M, Yadav P, Kumari R, Chander R. Eyelid petechiae as a window to relapse in a case of purging-type anorexia nervosa. *Indian J Psychiatr* 2019;61:101–2.
- [298] Fedewa A, Rao SS. Dietary fructose intolerance, fructan intolerance and FODMAPs. *Curr Gastroenterol Rep* 2014;16:370.
- [299] Garzon DL, Kempker T, Piel P. Primary care management of food allergy and food intolerance. *Nurs Pract* 2011;36:34–40.
- [300] Asero R. Food additives intolerance: does it present as perennial rhinitis? *Curr Opin Allergy Clin Immunol* 2004;4:25–9.
- [301] Branum AM, Lukacs SL. Food allergy among children in the United States. *Pediatrics* 2009;124:1549–55.
- [302] Nowak-Wegrzyn A, Katz Y, Mehr SS, Koletzko S. Non-IgE-mediated gastrointestinal food allergy. *J Allergy Clin Immunol* 2015;135:1114–24.
- [303] Fauquert JL. Food allergy and ocular surface. *Acta Ophthalmol* 2014;92:0.
- [304] Dupuis P, Prokopich CL, Hynes A, Kim H. A contemporary look at allergic conjunctivitis. *Allergy Asthma Clin Immunol* 2020;16:5.
- [305] Small P, Kim H. Allergic rhinitis. *Allergy Asthma Clin Immunol* 2011;7(Suppl 1):S3.
- [306] Prokopich CL, Lee-Poy M, Kim H. Interprofessional management of allergic conjunctivitis. *Can J Optom* 2018;80:11–27.
- [307] Wang CS, Wang J, Zhang X, Zhang L, Zhang HP, Wang L, et al. Is the consumption of fast foods associated with asthma or other allergic diseases? *Respirology* 2018;23:901–13.
- [308] Buettner D, Skemp S. Blue zones: lessons from the world's longest lived. *Am J Lifestyle Med* 2016;10:318–21.
- [309] Halton TL, Willett WC, Liu S, Manson JE, Stampfer MJ, Hu FB. Potato and French fry consumption and risk of type 2 diabetes in women. *Am J Clin Nutr* 2006;83:284–90.
- [310] Azzam A. Is the world converging to a 'Western diet. *Publ Health Nutr* 2021;24:309–17.
- [311] Fung TT, Rimm EB, Spiegelman D, Rifai N, Tofler GH, Willett WC, et al. Association between dietary patterns and plasma biomarkers of obesity and cardiovascular disease risk. *Am J Clin Nutr* 2001;73:61–7.
- [312] Kesse E, Clavel-Chapelon F, Boutron-Ruault MC. Dietary patterns and risk of colorectal tumors: a cohort of French women of the National Education System (E3N). *Am J Epidemiol* 2006;164:1085–93.
- [313] Crawford MA. Diet and cancer and heart disease. *Nutr Health* 2013;22:67–78.
- [314] Statovci D, Aguilera M, MacSharry J, Melgar S. The impact of western diet and nutrients on the microbiota and immune response at mucosal interfaces. *Front Immunol* 2017;8:838.
- [315] Bu J, Zhang M, Wu Y, Jiang N, Guo Y, He X, et al. High-fat diet induces inflammation of meibomian gland. *Invest Ophthalmol Vis Sci* 2021;62:13.
- [316] He X, Zhao Z, Wang S, Kang J, Zhang M, Bu J, et al. High-fat diet-induced functional and pathologic changes in lacrimal gland. *Am J Pathol* 2020;190:2387–402.
- [317] Jiao H, Lim AS, Fazio Coles TE, McQuade RM, Furness JB, Chinnery HR. The effect of high-fat diet-induced metabolic disturbance on corneal neuroimmune features. *Exp Eye Res* 2020;201:108298.
- [318] Wu Y, Wu J, Bu J, Tang L, Yang Y, Ouyang W, et al. High-fat diet induces dry eye-like ocular surface damages in murine. *Ocul Surf* 2020;18:267–76.
- [319] Kang K, Zhou Q, McGinn L, Nguyen T, Luo Y, Djallilian A, et al. High fat diet induced gut dysbiosis alters corneal epithelial injury response in mice. *Ocul Surf* 2022;23:49–59.
- [320] Trichopoulos A, Martinez-Gonzalez MA, Tong TY, Forouhi NG, Khandelwal S, Prabhakaran D, et al. Definitions and potential health benefits of the Mediterranean diet: views from experts around the world. *BMC Med* 2014;12:112.
- [321] Altomare R, Cacciabauda F, Damiano G, Palumbo VD, Gioviale MC, Bellavia M, et al. The mediterranean diet: a history of health. *Iran J Public Health* 2013;42:449–57.
- [322] Arnett DK, Blumenthal RS, Albert MA, Buroker AB, Goldberger ZD, Hahn EJ, et al. ACC/AHA guideline on the primary prevention of cardiovascular disease: a report of the American college of cardiology/American heart association task force on clinical practice guidelines. *Circulation* 2019;140:e596–646. 2019.
- [323] Schwingshackl L, Hoffmann G. Adherence to Mediterranean diet and risk of cancer: a systematic review and meta-analysis of observational studies. *Int J Cancer* 2014;135:1884–97.
- [324] Buckland G, Gonzalez CA. The role of olive oil in disease prevention: a focus on the recent epidemiological evidence from cohort studies and dietary intervention trials. *Br J Nutr* 2015;113(Suppl 2):S94–101.
- [325] Estruch R, Ros E. The role of the Mediterranean diet on weight loss and obesity-related diseases. *Rev Endocr Metab Disord* 2020;21:315–27.
- [326] Casas R, Sacanella E, Estruch R. The immune protective effect of the Mediterranean diet against chronic low-grade inflammatory diseases. *Endocr, Metab Immune Disord: Drug Targets* 2014;14:245–54.
- [327] Machowicz A, Hall I, de Pablo P, Rauz S, Richards A, Higham J, et al. Mediterranean diet and risk of Sjogren's syndrome. *Clin Exp Rheumatol* 2020;38(Suppl 126):216–21.
- [328] Molina-Leyva I, Molina-Leyva A, Riquelme-Gallego B, Cano-Ibanez N, Garcia-Molina L, Bueno-Cavanillas A. Effectiveness of mediterranean diet implementation in dry eye parameters: a study of PREDIMED-PLUS trial. *Nutrients* 2020;12.
- [329] Galor A, Gardener H, Pouyeh B, Feuer W, Florez H. Effect of a Mediterranean dietary pattern and vitamin D levels on Dry Eye syndrome. *Cornea* 2014;33:437–41.
- [330] Imamura F, Micha R, Khatibzadeh S, Fahimi S, Shi P, Powles J, et al. Dietary quality among men and women in 187 countries in 1990 and 2010: a systematic assessment. *Lancet Global Health* 2015;3:e132–42.
- [331] Blum LS, Peltó GH, Peltó PJ. Coping with a nutrient deficiency: cultural models of vitamin A deficiency in northern Niger. *Med Anthropol* 2004;23:195–227.
- [332] Le Francois P, Chevassus-Agnes S, Benefice E, Dyck JL, Maire B, Parent G, et al. Vitamin A status of populations in three West African countries. *Int J Vitam Nutr Res* 1980;50:352–63.
- [333] Schemann JF, Banou AA, Guindo A, Joret V, Traore L, Malvy D. Prevalence of undernutrition and vitamin A deficiency in the Dogon Region, Mali. *J Am Coll Nutr* 2002;21:381–7.
- [334] Misra A, Khurana L, Isharwal S, Bhardwaj S. South Asian diets and insulin resistance. *Br J Nutr* 2009;101:465–73.
- [335] Sariri R, Varasteh A, Sajedi RH. Effect of Ramadan fasting on tear proteins. *Acta Med* 2010;53:147–51.
- [336] Koktekir BE, Bozkurt B, Gonul S, Gedik S, Okudan S. Effect of religious fasting on tear osmolarity and ocular surface. *Eye Contact Lens* 2014;40:239–42.
- [337] Sedaghat MR, Heravian J, Askarizadeh F, Jabbarvand M, Nematy M, Rakhshandadi T, et al. Investigation of the effects of Islamic fasting on ocular parameters. *J Curr Ophthalmol* 2017;29:287–92.
- [338] Kayikcioglu O, Erkin EF, Erakgun T. The influence of religious fasting on basal tear secretion and tear break-up time. *Int Ophthalmol* 1998;22:67–9.
- [339] Armstrong BK, Coc IR, Agarwal P, Smith S, Navon S. Association of Ramadan daytime fasting with ocular surface inflammation and dry eye. *Int Ophthalmol* 2019;39:2857–63.
- [340] Jurkunas UV, Jakobiec FA, Shin J, Zakka FR, Michaud N, Jethva R. Reversible corneal epitheliopathy caused by vitamin B12 and folate deficiency in a vegan with a genetic mutation: a new disease. *Eye* 2011;25:1512–4.
- [341] Hsu HY, Tsai IL, Kuo LL, Tsai CY, Liou SW, Woung LC. Herpetic keratouveitis mixed with bilateral Pseudomonas corneal ulcers in vitamin A deficiency. *J Formos Med Assoc* 2015;114:184–7.
- [342] Colev M, Engel H, Mayers M, Markowitz M, Cahill L. Vegan diet and vitamin A deficiency. *Clin Pediatr* 2004;43:107–9.
- [343] Singh M, Sugathan PS, Bhujwala RA. Human colostrum for prophylaxis against sticky eyes and conjunctivitis in the newborn. *J Trop Pediatr* 1982;28:35–7.
- [344] Verd S. Switch from antibiotic eye drops to instillation of mother's milk drops as a treatment of infant epiphora. *J Trop Pediatr* 2007;53:68–9.
- [345] Baynham JT, Moorman MA, Donnellan C, Cevallos V, Keenan JD. Antibacterial effect of human milk for common causes of paediatric conjunctivitis. *Br J Ophthalmol* 2013;97:377–9.
- [346] Ghaemi S, Navaei P, Rahimirad S, Behjati M, Kelishadi R. Evaluation of preventive effects of colostrum against neonatal conjunctivitis: a randomized clinical trial. *J Educ Health Promot* 2014;3:63.
- [347] Karcz K, Walkowiak M, Makuch J, Olejnik I, Krolak-Olejnik B. Non-nutritional use of human milk Part 1: a survey of the use of breast milk as a therapy for mucosal infections of various types in Poland. *Int J Environ Res Publ Health* 2019;16.
- [348] Ramsey KH, Poulsen CE, Motiu PP. The in vitro antimicrobial capacity of human colostrum against Chlamydia trachomatis. *J Reprod Immunol* 1998;38:155–67.
- [349] Chaumeil C, Liotet S, Kogbe O. Treatment of severe eye dryness and problematic eye lesions with enriched bovine colostrum lactoserum. *Adv Exp Med Biol* 1994;350:595–9.



- [350] Sugimura T, Seo T, Terasaki N, Ozaki Y, Rikitake N, Okabe R, et al. Efficacy and safety of breast milk eye drops in infants with eye discharge. *Acta Paediatr* 2021; 110:1322–9.
- [351] Penco A, Barbi E. We are not ready to use breast milk eye drops for infants with eye discharges. *Acta Paediatr* 2021;110:2472.
- [352] Saravanan C, Cao Z, Kumar J, Qiu J, Plaut AG, Newburg DS, et al. Milk components inhibit Acanthamoeba-induced cytopathic effect. *Invest Ophthalmol Vis Sci* 2008;49:1010–5.
- [353] Bucolo C, Musumeci M, Salomone S, Romano GL, Leggio GM, Gagliano C, et al. Effects of topical fucosyl-lactose, a milk oligosaccharide, on dry eye model: an example of nutraceutical candidate. *Front Pharmacol* 2015;6:280.
- [354] Diego JL, Bidikov L, Pedler MG, Kennedy JB, Quiroz-Mercado H, Gregory DG, et al. Effect of human milk as a treatment for dry eye syndrome in a mouse model. *Mol Vis* 2016;22:1095–102.
- [355] Asena L, Suveren EH, Karabay G, Dursun Altinors D. Human breast milk drops promote corneal epithelial wound healing. *Curr Eye Res* 2017;42:506–12.
- [356] Ukponmwan C, Okolo O, Kayoma D, Ese-Onakewhor J. Complications of breast milk application to the infected eye. *Niger J Ophthalmol* 2009;17.
- [357] Nocerino R, Bedogni G, Carucci L, Cosenza L, Cozzolino T, Paparo L, et al. The impact of formula choice for the management of pediatric cow's milk allergy on the occurrence of other allergic manifestations: the atopic march cohort study. *J Pediatr* 2021;232:183–91. e3.
- [358] Lindeberg S. Paleolithic diets as a model for prevention and treatment of Western disease. *Am J Hum Biol* 2012;24:110–5.
- [359] Garcia-Montero C, Fraile-Martínez O, Gómez-Lahoz AM, Pekarek L, Castellanos AJ, Noguerales-Fraguas F, et al. Nutritional components in western diet versus mediterranean diet at the gut microbiota-immune system interplay. Implications for health and disease. *Nutrients* 2021;13:699.
- [360] Montalto M, D'onofrio F, Gallo A, Cazzato A, Gasbarrini G. Intestinal microbiota and its functions. *Digestive and Liver Disease Supplements* 2009;3:30–4.
- [361] Chen G, Chen ZM, Fan XY, Jin YL, Li X, Wu SR, et al. Gut-brain-skin Axis in psoriasis: a review. *Dermatol Ther* 2021;11:25–38.
- [362] Napolitano P, Filippelli M, Davinelli S, Bartolino S, dell'Omo R, Costagliola C. Influence of gut microbiota on eye diseases: an overview. *Ann Med* 2021;53:750–61.
- [363] Rinninella E, Raoul P, Cintoni M, Franceschi F, Miggiaro GAD, Gasbarrini A, et al. What is the healthy gut microbiota composition? A changing ecosystem across age, environment, diet, and diseases. *Microorganisms* 2019;7.
- [364] Moon J, Choi SH, Yoon CH, Kim MK. Gut dysbiosis is prevailing in Sjogren's syndrome and is related to dry eye severity. *PLoS One* 2020;15:e0229029.
- [365] Iebba V, Totino V, Gagliardi A, Santangelo F, Cacciotti F, Trancassini M, et al. Eubiosis and dysbiosis: the two sides of the microbiota. *New Microbiol* 2016;39:1–12.
- [366] Bajinka O, Tan Y, Abdelhalim KA, Ozdemir G, Qiu X. Extrinsic factors influencing gut microbes, the immediate consequences and restoring eubiosis. *Amb Express* 2020;10:130.
- [367] Kumar PS. Microbial dysbiosis: the root cause of periodontal disease. *J Periodontol* 2021;92:1079–87.
- [368] Lees CW. Environmental stimuli and gut inflammation via dysbiosis in mouse and man. *Nat Rev Gastroenterol Hepatol* 2020;17:715–6.
- [369] Trujillo-Vargas CM, Schaefer L, Alam J, Pflugfelder SC, Britton RA, de Paiva CS. The gut-eye-lacrimal gland-microbiome axis in Sjogren Syndrome. *Ocul Surf* 2020;18:335–44.
- [370] Cavuoto KM, Banerjee S, Galor A. Relationship between the microbiome and ocular health. *Ocul Surf* 2019;17:384–92.
- [371] Liu J, Wu M, He J, Xiao C, Xue Y, Fu T, et al. Antibiotic-induced dysbiosis of gut microbiota impairs corneal nerve regeneration by affecting CCR2-negative macrophage distribution. *Am J Pathol* 2018;188:2786–99.
- [372] Wu HJ, Ivanov II, Darce J, Hattori K, Shima T, Umesaki Y, et al. Gut-residing segmented filamentous bacteria drive autoimmune arthritis via T helper 17 cells. *Immunity* 2010;32:815–27.
- [373] Baim AD, Movahedan A, Farooq AV, Skondra D. The microbiome and ophthalmic disease. *Exp Biol Med* 2019;244:419–29.
- [374] Asquith M, Elewaut D, Lin P, Rosenbaum JT. The role of the gut and microbes in the pathogenesis of spondyloarthritis. *Best Pract Res Clin Rheumatol* 2014;28:687–702.
- [375] Belkaid Y, Hand TW. Role of the microbiota in immunity and inflammation. *Cell* 2014;157:121–41.
- [376] Durack J, Lynch SV. The gut microbiome: relationships with disease and opportunities for therapy. *J Exp Med* 2019;216:20–40.
- [377] Brenchley JM, Douek DC. Microbial translocation across the GI tract. *Annu Rev Immunol* 2012;30:149–73.
- [378] Cione E, Fazio A, Curcio R, Tucci P, Lauria G, Cappello ARR, et al. Resistant starches and non-communicable disease: a focus on mediterranean diet. *Foods* 2021;10:2062.
- [379] Dominguez LJ, Di Bella G, Veronese N, Barbagallo M. Impact of mediterranean diet on chronic non-communicable diseases and longevity. *Nutrients* 2021;13:2028.
- [380] De Filippo C, Cavalieri D, Di Paola M, Ramazzotti M, Poullet JB, Massart S, et al. Impact of diet in shaping gut microbiota revealed by a comparative study in children from Europe and rural Africa. *Proc Natl Acad Sci U S A* 2010;107:14691–6.
- [381] Redondo-Useros N, Nova E, Gonzalez-Zancada N, Diaz LE, Gomez-Martinez S, Marcos A. Microbiota and lifestyle: a special focus on diet. *Nutrients* 2020;12:1776.
- [382] Barr T, Helms C, Grant K, Messaoudi I. Opposing effects of alcohol on the immune system. *Prog Neuro-Psychopharmacol Biol Psychiatry* 2016;65:242–51.
- [383] Mutlu EA, Gillevet PM, Rangwala H, Sikaroodi M, Naqvi A, Engen PA, et al. Colonic microbiome is altered in alcoholism. *Am J Physiol Gastrointest Liver Physiol* 2012;302:G966–78.
- [384] Ames NJ, Barb JJ, Schuebel K, Mudra S, Meeks BK, Tuason RTS, et al. Longitudinal gut microbiome changes in alcohol use disorder are influenced by abstinence and drinking quantity. *Gut Microb* 2020;11:1608–31.
- [385] Rodríguez-Delgado M-A, González-Hernández G, Conde-González J-Ea, Pérez-Trujillo J-P. Principal component analysis of the polyphenol content in young red wines. *Food Chem* 2002;78:523–32.
- [386] Barroso E, Munoz-Gonzalez I, Jimenez E, Bartolome B, Moreno-Arribas MV, Pelaez C, et al. Phylogenetic profile of gut microbiota in healthy adults after moderate intake of red wine. *Mol Nutr Food Res* 2017;61:1600620.
- [387] Cuervo A, Reyes-Gavilan CG, Ruas-Madiedo P, Lopez P, Suarez A, Gueimonde M, et al. Red wine consumption is associated with fecal microbiota and malondialdehyde in a human population. *J Am Coll Nutr* 2015;34:135–41.
- [388] Berendsen RL, Pieterse CM, Bakker PA. The rhizosphere microbiome and plant health. *Trends Plant Sci* 2012;17:478–86.
- [389] Zhu B, Wang X, Li L. Human gut microbiome: the second genome of human body. *Protein Cell* 2010;1:718–25.
- [390] Hirt H. Healthy soils for healthy plants for healthy humans: how beneficial microbes in the soil, food and gut are interconnected and how agriculture can contribute to human health. *EMBO Rep* 2020;21:e51069.
- [391] Zhou M, Zhao J. A review on the health effects of pesticides based on host gut microbiome and metabolomics. *Front Mol Biosci* 2021;8:632955.
- [392] Lerner A, Matthias T. Changes in intestinal tight junction permeability associated with industrial food additives explain the rising incidence of autoimmune disease. *Autoimmun Rev* 2015;14:479–89.
- [393] Zhu Y, Bol J, Rinzema A, Tramper J. Microbial transglutaminase - a review of its production and application in food processing. *Appl Microbiol Biotechnol* 1995;44:277–82.
- [394] Matthias T, Jeremias P, Neidhofer S, Lerner A. The industrial food additive, microbial transglutaminase, mimics tissue transglutaminase and is immunogenic in celiac disease patients. *Autoimmun Rev* 2016;15:1111–9.
- [395] Bi Y, Marcus AK, Robert H, Krajalnik-Brown R, Rittmann BE, Westerhoff P, et al. The complex puzzle of dietary silver nanoparticles, mucus and microbiota in the gut. *J Toxicol Environ Health B Crit Rev* 2020;23:69–89.
- [396] Forbes A, Kalantzis T. Crohn's disease: the cold chain hypothesis. *Int J Colorectal Dis* 2006;21:399–401.
- [397] Hugot JP, Alberti C, Berrebi D, Bingen E, Cezaud JP. Crohn's disease: the cold chain hypothesis. *Lancet* 2003;362:2012–5.
- [398] Yazdanbakhsh M, Kreamer PG, van Ree R. Allergy, parasites, and the hygiene hypothesis. *Science* 2002;296:490–4.
- [399] Hesselmar B, Hicke-Roberts A, Wennergren G. Allergy in children in hand versus machine dishwashing. *Pediatrics* 2015;135:e590–7.
- [400] Fan Y, Pedersen O. Gut microbiota in human metabolic health and disease. *Nat Rev Microbiol* 2021;19:55–71.
- [401] Shivaji S. Connect between gut microbiome and diseases of the human eye. *J Biosci* 2019;44:110.
- [402] Bu Y, Chan YK, Wong HL, Poon SH, Lo AC, Shih KC, et al. A review of the impact of alterations in gut microbiome on the immunopathogenesis of ocular diseases. *J Clin Med* 2021;10.
- [403] Khanna RC. Ocular surface disorders. *Community Eye Health* 2017;30:S1–2.
- [404] Aragona P, Baudouin C, Benitez Del Castillo JM, Messmer E, Barabino S, Merayo-Lloves J, et al. The ocular microbiome and microbiota and their effects on ocular surface pathophysiology and disorders. *Surv Ophthalmol* 2021;66:907–25.
- [405] Bron AJ, de Paiva CS, Chauhan SK, Bonini S, Gabison EE, Jain S, et al. TFOS DEWS II pathophysiology report. *Ocul Surf* 2017;15:438–510.
- [406] Sacca SC, Pascotto A, Venturino GM, Prigione G, Mastromarino A, Baldi F, et al. Prevalence and treatment of *Helicobacter pylori* in patients with blepharitis. *Invest Ophthalmol Vis Sci* 2006;47:501–8.
- [407] Petrillo F, Pignataro D, Lavano MA, Santella B, Folliero V, Zannella C, et al. Current evidence on the ocular surface microbiota and related diseases. *Microorganisms* 2020;8.
- [408] Kalyana Chakravarthy S, Jayasudha R, Ranjith K, Dutta A, Pinna NK, Mande SS, et al. Alterations in the gut bacterial microbiome in fungal Keratitis patients. *PLoS One* 2018;13:e0199640.
- [409] Kugadas A, Christiansen SH, Sankaranarayanan S, Surana NK, Gauguet S, Kunz R, et al. Impact of microbiota on resistance to ocular *Pseudomonas aeruginosa*-induced keratitis. *PLoS Pathog* 2016;12:e1005855.
- [410] Wang Y, Chen H, Xia T, Huang Y. Characterization of fungal microbiota on normal ocular surface of humans. *Clin Microbiol Infect* 2020;26. 123 e9- e13.
- [411] Moon J, Yoon CH, Choi SH, Kim MK. Can gut microbiota affect dry eye syndrome? *Int J Mol Sci* 2020;21.
- [412] van der Meulen TA, Harmsen HJM, Vila AV, Kurilshikov A, Liefers SC, Zherakov A, et al. Shared gut, but distinct oral microbiota composition in primary Sjogren's syndrome and systemic lupus erythematosus. *J Autoimmun* 2019;97:77–87.
- [413] de Paiva CS, Jones DB, Stern ME, Bian F, Moore QL, Corbiere S, et al. Altered mucosal microbiome diversity and disease severity in sjogren syndrome. *Sci Rep* 2016;6:23561.
- [414] Wang C, Zaheer M, Bian F, Quach D, Swennes AG, Britton RA, et al. Sjogren-like lacrimal keratoconjunctivitis in germ-free mice. *Int J Mol Sci* 2018;19.
- [415] Zaheer M, Wang C, Bian F, Yu Z, Hernandez H, de Souza RG, et al. Protective role of commensal bacteria in Sjogren Syndrome. *J Autoimmun* 2018;93:45–56.

- [416] Yanagisawa N, Ueshiba H, Abe Y, Kato H, Higuchi T, Yagi J. Outer membrane protein of gut commensal microorganism induces autoantibody production and extra-intestinal gland inflammation in mice. *Int J Mol Sci* 2018;19.
- [417] Daniel H, Gholami AM, Berry D, Desmarchelier C, Hahne H, Loh G, et al. High-fat diet alters gut microbiota physiology in mice. *ISME J* 2014;8:295–308.
- [418] Osae EA, Steven P, Redfern R, Hanlon S, Smith CW, Rumbaut RE, et al. Dyslipidemia and meibomian gland dysfunction: utility of lipidomics and experimental prospects with a diet-induced obesity mouse model. *Int J Mol Sci* 2019;20.
- [419] Yoon CH, Ryu JS, Moon J, Kim MK. Association between aging-dependent gut microbiome dysbiosis and dry eye severity in C57BL/6 male mouse model: a pilot study. *BMC Microbiol* 2021;21:106.
- [420] Mendez R, Watane A, Farhangi M, Cavuoto KM, Leith T, Budree S, et al. Gut microbial dysbiosis in individuals with Sjogren's syndrome. *Microb Cell Factories* 2020;19:90.
- [421] Mandl T, Marsal J, Olsson P, Ohlsson B, Andreasson K. Severe intestinal dysbiosis is prevalent in primary Sjogren's syndrome and is associated with systemic disease activity. *Arthritis Res Ther* 2017;19:237.
- [422] Belmonte C, Nichols JJ, Cox SM, Brock JA, Begley CG, Bereiter DA, et al. TFOS DEWS II pain and sensation report. *Ocul Surf* 2017;15:404–37.
- [423] Craig JP, Nichols KK, Akpek EK, Caffery B, Dua HS, Joo CK, et al. TFOS DEWS II definition and classification report. *Ocul Surf* 2017;15:276–83.
- [424] Labetoulle M, Baudouin C, Calonge M, Merayo-Llodes J, Boboridis KG, Akova YA, et al. Role of corneal nerves in ocular surface homeostasis and disease. *Acta Ophthalmol* 2019;97:137–45.
- [425] Dua HS, Said DG, Messmer EM, Rolando M, Benitez-Del-Castillo JM, Hossain PN, et al. Neurotrophic keratopathy. *Prog Retin Eye Res* 2018;66:107–31.
- [426] Bourcier T, Acosta MC, Borderie V, Borrás F, Gallar J, Bury T, et al. Decreased corneal sensitivity in patients with dry eye. *Invest Ophthalmol Vis Sci* 2005;46:2341–5.
- [427] Stepp MA, Pal-Ghosh S, Tadvalkar G, Williams A, Pflugfelder SC, de Paiva CS. Reduced intraepithelial corneal nerve density and sensitivity accompany desiccating stress and aging in C57BL/6 mice. *Exp Eye Res* 2018;169:91–8.
- [428] Jayasudha R, Chakravathy SK, Prashanthi GS, Sharma S, Garg P, Murthy SI, et al. Alterations in gut bacterial and fungal microbiomes are associated with bacterial Keratitis, an inflammatory disease of the human eye. *J Biosci* 2018;43:835–56.
- [429] Shivaji S. A systematic review of gut microbiome and ocular inflammatory diseases: are they associated? *Indian J Ophthalmol* 2021;69:535–42.
- [430] Lin P. The role of the intestinal microbiome in ocular inflammatory disease. *Curr Opin Ophthalmol* 2018;29:261–6.
- [431] Schaefer L, Hernandez H, Coats RA, Yu Z, Pflugfelder SC, Britton RA, et al. Author Correction: gut-derived butyrate suppresses ocular surface inflammation. *Sci Rep* 2022;12:6581.
- [432] Watane A, Cavuoto KM, Rojas M, Dermer H, Day JO, Banerjee S, et al. Fecal microbial transplant in individuals with immune-mediated dry eye. *Am J Ophthalmol* 2022;233:90–100.
- [433] Kawashima M, Tsuno S, Matsumoto M, Tsubota K. Hydrogen-producing milk to prevent reduction in tear stability in persons using visual display terminals. *Ocul Surf* 2019;17:714–21.
- [434] Guvenc IA, Muluk NB, Mutlu FS, Eski E, Altintoprak N, Oktemer T, et al. Do probiotics have a role in the treatment of allergic rhinitis? A comprehensive systematic review and meta-analysis. *Am J Rhinol Allergy* 2016;30:157–75.
- [435] Hara Y, Shiraiishi A, Sakane Y, Takezawa Y, Kamao T, Ohashi Y, et al. Effect of Mandarin orange yogurt on allergic conjunctivitis induced by conjunctival allergen challenge. *Invest Ophthalmol Vis Sci* 2017;58:2922–9.
- [436] Dennis-Wall JC, Culpepper T, Nieves Jr C, Rowe CC, Burns AM, Rusch CT, et al. Probiotics (*Lactobacillus gasserii* KS-13, *Bifidobacterium bifidum* G9-1, and *Bifidobacterium longum* MM-2) improve rhinoconjunctivitis-specific quality of life in individuals with seasonal allergies: a double-blind, placebo-controlled, randomized trial. *Am J Clin Nutr* 2017;105:758–67.
- [437] Berni Canani R, Di Costanzo M, Bedogni G, Amoroso A, Cosenza L, Di Scala C, et al. Extensively hydrolyzed casein formula containing *Lactobacillus rhamnosus* GG reduces the occurrence of other allergic manifestations in children with cow's milk allergy: 3-year randomized controlled trial. *J Allergy Clin Immunol* 2017;139:1906–19013. e4.
- [438] Pastor-Villaescusa B, Hurtado JA, Gil-Campos M, Uberos J, Maldonado-Lobon JA, Diaz-Ropero MP, et al. Effects of *Lactobacillus fermentum* CECT5716 Lc40 on infant growth and health: a randomised clinical trial in nursing women. *Benef Microbes* 2020;11:235–44.
- [439] Zuccotti G, Meneghin F, Aceti A, Barone G, Callegari ML, Di Mauro A, et al. Probiotics for prevention of atopic diseases in infants: systematic review and meta-analysis. *Allergy* 2015;70:1356–71.
- [440] Wu M, Liu J, Li F, Huang S, He J, Xue Y, et al. Antibiotic-induced dysbiosis of gut microbiota impairs corneal development in postnatal mice by affecting CCR2 negative macrophage distribution. *Mucosal Immunol* 2020;13:47–63.
- [441] Hanchi H, Mottawea W, Sebei K, Hammami R. The genus *Enterococcus*: between probiotic potential and safety concerns—an update. *Front Microbiol* 2018;9:1791.
- [442] Chisari G, Chisari EM, Francaviglia A, Chisari CG. The mixture of bifidobacterium associated with fructo-oligosaccharides reduces the damage of the ocular surface. *Clin Ter* 2017;168:e181–5.
- [443] Chisari G, Rampello L, Chisari EM, Catania VE, Greco C, Stagni E, et al. Microbiology synergism between tear substitutes and symbiotic treatment of patients with irritable bowel syndrome. *Acta Med Mediterr* 2016;32:865–70.
- [444] Kim J, Choi SH, Kim YJ, Jeong HJ, Ryu JS, Lee HJ, et al. Clinical effect of IRT-5 probiotics on immune modulation of autoimmunity or alloimmunity in the eye. *Nutrients* 2017;9.
- [445] Choi SH, Oh JW, Ryu JS, Kim HM, Im SH, Kim KP, et al. IRT5 probiotics changes immune modulatory protein expression in the extraorbital lacrimal glands of an autoimmune dry eye mouse model. *Invest Ophthalmol Vis Sci* 2020;61:42.
- [446] Moon J, Ryu JS, Kim JY, Im SH, Kim MK. Effect of IRT5 probiotics on dry eye in the experimental dry eye mouse model. *PLoS One* 2020;15:e0243176.
- [447] Tavakoli A, Markoulli M, Papas E, Flanagan J. The impact of probiotics and prebiotics on dry eye disease signs and symptoms. *J Clin Med* 2022;11.
- [448] Moshkelgosh S, Verhasselt HL, Masetti G, Covelli D, Biscarini F, Horstmann M, et al. Modulating gut microbiota in a mouse model of Graves' orbitopathy and its impact on induced disease. *Microbiome* 2021;9:45.
- [449] Tavakoli A, Flanagan JL. The case for a more holistic approach to dry eye disease: is it time to move beyond antibiotics? *Antibiotics*, vol. 8. Basel; 2019.
- [450] Singh P, Rawat A, Alwakeel M, Sharif E, Al Khodor S. The potential role of vitamin D supplementation as a gut microbiota modifier in healthy individuals. *Sci Rep* 2020;10:21641.
- [451] Otten AT, Bourgonje AR, Peters V, Alizadeh BZ, Dijkstra G, Harmsen HJM. Vitamin C supplementation in healthy individuals leads to shifts of bacterial populations in the gut-A pilot study. *Antioxidants* 2021;10.
- [452] Ferreira RLU, Sena-Evangelista KCM, de Azevedo EP, Pinheiro FI, Cobucci RN, Pedrosa LFC. Selenium in human health and gut microflora: bioavailability of selenocompounds and relationship with diseases. *Front Nutr* 2021;8:685317.
- [453] Vega-Bautista A, de la Garza M, Carrero JC, Campos-Rodriguez R, Godinez-Victoria M, Drago-Serrano ME. The impact of lactoferrin on the growth of intestinal inhabitant bacteria. *Int J Mol Sci* 2019;20.
- [454] Scazzocchio B, Minghetti L, D'Archivio M. Interaction between gut microbiota and curcumin: a new key of understanding for the health effects of curcumin. *Nutrients* 2020;12.
- [455] Pei R, Liu X, Bolling B. Flavonoids and gut health. *Curr Opin Biotechnol* 2020;61:153–9.
- [456] Davinelli S, Ali S, Scapagnini G, Costagliola C. Effects of flavonoid supplementation on common eye disorders: a systematic review and meta-analysis of clinical trials. *Front Nutr* 2021;8:651441.
- [457] Corsello A, Pugliese D, Gasbarrini A, Armuzzi A. Diet and nutrients in gastrointestinal chronic diseases. *Nutrients* 2020;12.
- [458] Moszak M, Szulinska M, Bogdanski P. You are what you eat—the relationship between diet, microbiota, and metabolic disorders-A review. *Nutrients* 2020;12.
- [459] Raimundo M, Lopes JA. Metabolic syndrome, chronic kidney disease, and cardiovascular disease: a dynamic and life-threatening triad. *Cardiol Res Pract* 2011;2011:747861.
- [460] Stapleton F, Alves M, Bunya VY, Jalbert I, Lekhanont K, Malet F, et al. TFOS DEWS II epidemiology report. *Ocul Surf* 2017;15:334–65.
- [461] Vehof J, Kozareva D, Hysi PG, Hammond CJ. Prevalence and risk factors of dry eye disease in a British female cohort. *Br J Ophthalmol* 2014;98:1712–7.
- [462] Gomes JAP, Azar DT, Baudouin C, Efron N, Hirayama M, Horwath-Winter J, et al. TFOS DEWS II etiologic report. *Ocul Surf* 2017;15:511–38.
- [463] Fond G, Loundou A, Hamdani N, Boukouaci W, Dargel A, Oliveira J, et al. Anxiety and depression comorbidities in irritable bowel syndrome (IBS): a systematic review and meta-analysis. *Eur Arch Psychiatr Clin Neurosci* 2014;264:651–60.
- [464] Neuendorf R, Harding A, Stello N, Hanes D, Wahbeh H. Depression and anxiety in patients with Inflammatory Bowel Disease: a systematic review. *J Psychosom Res* 2016;87:70–80.
- [465] Mukherjee N, Chaturvedi SK. Depressive symptoms and disorders in type 2 diabetes mellitus. *Curr Opin Psychiatr* 2019;32:416–21.
- [466] Thompson T, Correll CU, Gallop K, Vancampfort D, Stubbs B. Is pain perception altered in people with depression? A systematic review and meta-analysis of experimental pain research. *J Pain* 2016;17:1257–72.
- [467] Klauenberg S, Maier C, Assion HJ, Hoffmann A, Krumova EK, Magerl W, et al. Depression and changed pain perception: hints for a central disinhibition mechanism. *Pain* 2008;140:332–43.
- [468] World Health Organization. World Health Organization fact sheet: obesity and overweight. 2021.
- [469] Mokdad AH, Ford ES, Bowman BA, Dietz WH, Vinicor F, Bales VS, et al. Prevalence of obesity, diabetes, and obesity-related health risk factors. *JAMA* 2001;289:76–9. 2003.
- [470] Whiting DR, Guariguata L, Weil C, Shaw J. IDF diabetes atlas: global estimates of the prevalence of diabetes for 2011 and 2030. *Diabetes Res Clin Pract* 2011;94:311–21.
- [471] Dixon JB, Zimmet P, Alberti KG, Mbanya JC, Rubino F. International Diabetes Federation Taskforce on E. Bariatric surgery for diabetes: the International Diabetes Federation takes a position. *J Diabetes* 2011;3:261–4.
- [472] Yip S, Plank LD, Murphy R. Gastric bypass and sleeve gastrectomy for type 2 diabetes: a systematic review and meta-analysis of outcomes. *Obes Surg* 2013;23:1994–2003.
- [473] Mingrone G, Panunzi S, De Gaetano A, Guidone C, Iaconelli A, Leccesi L, et al. Bariatric surgery versus conventional medical therapy for type 2 diabetes. *N Engl J Med* 2012;366:1577–85.
- [474] Lee W-J, Chong K, Chen C-Y, Chen S-C, Lee Y-C, Ser K-H, et al. Diabetes remission and insulin secretion after gastric bypass in patients with body mass index < 35 kg/m<sup>2</sup>. *Obes Surg* 2011;21:889–95.
- [475] Age-Related Eye Disease Study Research G. Risk factors associated with age-related macular degeneration. *Ophthalmology* 2000;107:2224–32.
- [476] Age-Related Eye Disease Study Research G. Risk factors associated with age-related nuclear and cortical cataract: a case-control study in the Age-Related Eye Disease Study, AREDS Report No. 5. *Ophthalmology* 2001;108:1400–8.
- [477] Gasser P, Stumpf D, Schotzau A, Ackermann-Liebrich U, Flammer J. Body mass index in glaucoma. *J Glaucoma* 1999;8:8–11.

- [478] Netland PA, Sugrue SP, Albert DM, Shore JW. Histopathologic features of the floppy eyelid syndrome. Involvement of tarsal elastin. *Ophthalmology* 1994;101:174–81.
- [479] Leibovitch I, Selva D. Floppy eyelid syndrome: clinical features and the association with obstructive sleep apnea. *Sleep Med* 2006;7:117–22.
- [480] Idowu OO, Ashraf DC, Vagefi MR, Kersten RC, Winn BJ. Floppy eyelid syndrome: ocular and systemic associations. *Curr Opin Ophthalmol* 2019;30:513–24.
- [481] Li S, Ning K, Zhou J, Guo Y, Zhang H, Zhu Y, et al. Sleep deprivation disrupts the lacrimal system and induces dry eye disease. *Exp Mol Med* 2018;50:e451.
- [482] Salinas R, Puig M, Fry CL, Johnson DA, Kheirkhah A. Floppy eyelid syndrome: a comprehensive review. *Ocul Surf* 2020;18:31–9.
- [483] Vieira MJ, Silva MJ, Lopes N, Moreira C, Carvalheira F, Sousa JP. Prospective evaluation of floppy eyelid syndrome at baseline and after CPAP therapy. *Curr Eye Res* 2021;46:31–4.
- [484] Finsterer J. Ptosis: causes, presentation, and management. *Aesthetic Plast Surg* 2003;27:193–204.
- [485] Hashemi H, Khabazkhoob M, Emamian MH, Yekta A, Jafari A, Nabovati P, et al. The prevalence of ptosis in an Iranian adult population. *J Curr Ophthalmol* 2016;28:142–5.
- [486] Jubbal KT, Kania K, Braun TL, Katowitz WR, Marx DP. Pediatric blepharoptosis. *Semin Plast Surg* 2017;31:58–64.
- [487] Kantaputra PN, Kunachaichote J, Patikulsila P. Mental retardation, obesity, mandibular prognathism with eye and skin anomalies (MOMES syndrome): a newly recognized autosomal recessive syndrome. *Am J Med Genet* 2001;103:283–8.
- [488] Moesen I, van den Bosch W, Wubbels R, Paridaens D. Is dry eye associated with acquired aponeurogenic blepharoptosis? *Orbit* 2014;33:173–7.
- [489] Yang WJ, Yang YN, Cao J, Man ZH, Yuan J, Xiao X, et al. Risk factors for dry eye syndrome: a retrospective case-control study. *Optom Vis Sci* 2015;92:e199–205.
- [490] Baser G, Yildiz N, Calan M. Evaluation of meibomian gland dysfunction in polycystic ovary syndrome and obesity. *Curr Eye Res* 2017;42:661–5.
- [491] Gloy VL, Briel M, Bhatt DL, Kashyap SR, Schauer PR, Mingrone G, et al. Bariatric surgery versus non-surgical treatment for obesity: a systematic review and meta-analysis of randomised controlled trials. *BMJ* 2013;347:f5934.
- [492] Pories WJ. Bariatric surgery: risks and rewards. *J Clin Endocrinol Metab* 2008;93:889–96.
- [493] Guerreiro RA, Ribeiro R. Ophthalmic complications of bariatric surgery. *Obes Surg* 2015;25:167–73.
- [494] Shankar P, Boylan M, Sriram K. Micronutrient deficiencies after bariatric surgery. *Nutrition* 2010;26:1031–7.
- [495] Parrish C. Severe micronutrient deficiencies in RYGB patients: rare but potentially devastating. *Practical Gastroenterol* 2011;100:13–27.
- [496] Sommer A. Xerophthalmia, keratomalacia and nutritional blindness. *Int Ophthalmol* 1990;14:195–9.
- [497] Ledoux S, Msika S, Moussa F, Larger E, Boudou P, Salomon L, et al. Comparison of nutritional consequences of conventional therapy of obesity, adjustable gastric banding, and gastric bypass. *Obes Surg* 2006;16:1041–9.
- [498] Zalesin KC, Miller WM, Franklin B, Mudugal D, Rao Buragadda A, Boura J, et al. Vitamin A deficiency after gastric bypass surgery: an underreported postoperative complication. *J Obes* 2011;2011.
- [499] Eckert MJ, Perry JT, Sohn VY, Boden J, Martin MJ, Rush RM, et al. Incidence of low vitamin A levels and ocular symptoms after Roux-en-Y gastric bypass. *Surg Obes Relat Dis* 2010;6:653–7.
- [500] Slater GH, Ren CJ, Siegel N, Williams T, Barr D, Wolfe B, et al. Serum fat-soluble vitamin deficiency and abnormal calcium metabolism after malabsorptive bariatric surgery. *J Gastrointest Surg* 2004;8:48–55. ; discussion 4-5.
- [501] Donaldson KE, Fishler J. Corneal ulceration in a LASIK patient due to vitamin A deficiency after bariatric surgery. *Cornea* 2012;31:1497–9.
- [502] Karimzad S, Bilkhu PS, Wolffsohn JS, Bellary S, Shokr H, Singhal R, et al. Impact of bariatric surgery-induced weight loss on anterior eye health in patients with obesity. *Nutrients* 2022;14.
- [503] Iqbal Z, Kalteniece A, Ferdousi M, Adam S, D'Onofrio L, Ho JH, et al. Corneal keratocyte density and corneal nerves are reduced in patients with severe obesity and improve after bariatric surgery. *Invest Ophthalmol Vis Sci* 2021;62:20.
- [504] Marques NPN, Felberg S, Barros JN, Malheiros CA. Evaluation of the ocular surface following bariatric surgery. *Arq Bras Oftalmol* 2017;80:247–51.
- [505] Brandao LP, Vilar L, Cavalcanti BM, Brandao PH, Arantes TE, Campos JM. Serum levels of vitamin A, visual function and ocular surface after bariatric surgery. *Arq Gastroenterol* 2017;54:65–9.
- [506] Kuriakose RK, Braich PS. Dyslipidemia and its association with meibomian gland dysfunction: a systematic review. *Int Ophthalmol* 2018;38:1809–16.
- [507] Schaumberg DA, Dana R, Buring JE, Sullivan DA. Prevalence of dry eye disease among US men: estimates from the Physicians' Health Studies. *Arch Ophthalmol* 2009;127:763–8.
- [508] Yu K, Bunya V, Maguire M, Asbell P, Ying GS, Dry Eye A, et al. Systemic conditions associated with severity of dry eye signs and symptoms in the dry eye assessment and management study. *Ophthalmology* 2021;128:1384–92.
- [509] Chang HC, Sung CW, Lin MH. Serum lipids and risk of atherosclerosis in xanthelasma palpebrarum: a systematic review and meta-analysis. *J Am Acad Dermatol* 2020;82:596–605.
- [510] Goncalves VSS, Andrade KRC, Carvalho KMB, Silva MT, Pereira MG, Galvao TF. Accuracy of self-reported hypertension: a systematic review and meta-analysis. *J Hypertens* 2018;36:970–8.
- [511] World Health Organization. Waist circumference and waist-hip ratio: report of a WHO expert consultation. 2011. Geneva, 8-11 December 2008.
- [512] Alberti KG, Zimmet P, Shaw J. Metabolic syndrome—a new world-wide definition. A consensus statement from the international diabetes federation. *Diabet Med* 2006;23:469–80.
- [513] Erdur SK, Aydin R, Ozsutcu M, Olmuscelik O, Eliacik M, Demirci G, et al. The relationship between metabolic syndrome, its components, and dry eye: a cross-sectional study. *Curr Eye Res* 2017;42:1115–7.
- [514] Issar T, Tummanapalli SS, Borire AA, Kwai NCG, Poynten AM, Arnold R, et al. Impact of the metabolic syndrome on peripheral nerve structure and function in type 2 diabetes. *Eur J Neurol* 2021;28:2074–82.
- [515] Davies MJ, D'Alessio DA, Fradkin J, Kernan WN, Mathieu C, Mingrone G, et al. A consensus report by the American diabetes association (ADA) and the European association for the study of diabetes (EASD). Management of Hyperglycemia in Type 2 Diabetes Diabetes Care 2018;41:2669–701. 2018.
- [516] Harris MI, Klein R, Welborn TA, Knudman MW. Onset of NIDDM occurs at least 4-7 yr before clinical diagnosis. *Diabetes Care* 1992;15:815–9.
- [517] National Diabetes Data Group. Classification and diagnosis of diabetes mellitus and other categories of glucose intolerance. *Diabetes* 1979;28:1039–57.
- [518] Diabetes Prevention Program Research Group. Reduction in the incidence of type 2 diabetes with lifestyle intervention or metformin. *N Engl J Med* 2002;346:393–403.
- [519] Heikes KE, Eddy DM, Arondekar B, Schlessinger L. Diabetes Risk Calculator: a simple tool for detecting undiagnosed diabetes and pre-diabetes. *Diabetes Care* 2008;31:1040–5.
- [520] Inoue K, Okugawa K, Amano S, Oshika T, Takamura E, Egami F, et al. Blinking and superficial punctate keratopathy in patients with diabetes mellitus. *Eye* 2005;19:418–21.
- [521] Eissa IM, Khalil NM, El-Gendy HA. A controlled study on the correlation between tear film volume and tear film stability in diabetic patients. *J Ophthalmol* 2016;2016:5465272.
- [522] Ezra DG, Beaconsfield M, Sira M, Bunce C, Wormald R, Collin R. The associations of floppy eyelid syndrome: a case control study. *Ophthalmology* 2010;117:831–8.
- [523] Nair PA, Singhal R. Xanthelasma palpebrarum - a brief review. *Clin Cosmet Invest Dermatol* 2018;11:1–5.
- [524] Bhansali A, Bhadada S, Sharma A, Suresh V, Gupta A, Singh P, et al. Presentation and outcome of rhino-orbital-cerebral mucormycosis in patients with diabetes. *Postgrad Med* 2004;80:670–4.
- [525] Kronish JW, McLeish WM. Eyelid necrosis and periorbital necrotizing fasciitis. Report of a case and review of the literature. *Ophthalmology* 1991;98:92–8.
- [526] Fan F, Li X, Li K, Jia Z. To find out the relationship between levels of glycosylated hemoglobin with meibomian gland dysfunction in patients with type 2 diabetes. *Therapeut Clin Risk Manag* 2021;17:797–807.
- [527] Shamsheer RP, Arunachalam C. A clinical study of meibomian gland dysfunction in patients with diabetes. *Middle East Afr J Ophthalmol* 2015;22:462–6.
- [528] Viso E, Rodriguez-Ares MT, Abelenda D, Oubina B, Gude F. Prevalence of asymptomatic and symptomatic meibomian gland dysfunction in the general population of Spain. *Invest Ophthalmol Vis Sci* 2012;53:2601–6.
- [529] Lin X, Xu B, Zheng Y, Coursey TG, Zhao Y, Li J, et al. Meibomian gland dysfunction in type 2 diabetic patients. *J Ophthalmol* 2017;2017:3047867.
- [530] Yu T, Han XG, Gao Y, Song AP, Dang GF. Morphological and cytological changes of meibomian glands in patients with type 2 diabetes mellitus. *Int J Ophthalmol* 2019;12:1415–9.
- [531] Yu T, Shi WY, Song AP, Gao Y, Dang GF, Ding G. Changes of meibomian glands in patients with type 2 diabetes mellitus. *Int J Ophthalmol* 2016;9:1740–4.
- [532] Yang Q, Li B, Sheng M. Meibum lipid composition in type 2 diabetics with dry eye. *Exp Eye Res* 2021;206:108522.
- [533] Clifford CW, Fulk GW. Association of diabetes, lash loss, and Staphylococcus aureus with infestation of eyelids by Demodex folliculorum (Acari: demodicidae). *J Med Entomol* 1990;27:467–70.
- [534] Yamashita LS, Cariello AJ, Geha NM, Yu MC, Hofling-Lima AL. Demodex folliculorum on the eyelash follicle of diabetic patients. *Arq Bras Oftalmol* 2011;74:422–4.
- [535] Negi A, Vernon SA. An overview of the eye in diabetes. *J R Soc Med* 2003;96:266–72.
- [536] Hashemi H, Pakzad R, Heydari S, Aghamirsalim M, Asadollahi M, Yekta A, et al. The prevalence of anterior blepharitis in an elderly population of Iran; the Tehran geriatric eye study. *Contact Lens Anterior Eye* 2021;44:101429.
- [537] Lee CY, Chen HC, Lin HW, Huang JY, Chao SC, Yeh CB, et al. Blepharitis as an early sign of metabolic syndrome: a nationwide population-based study. *Br J Ophthalmol* 2018;102:1283–7.
- [538] Zhang AC, Muntz A, Wang MTM, Craig JP, Downie LE. Ocular Demodex: a systematic review of the clinical literature. *Ophthalmic Physiol Opt* 2020;40:389–432.
- [539] Cheung AT, Ramanujam S, Greer DA, Kumagai LF, Aoki TT. Microvascular abnormalities in the bulbar conjunctiva of patients with type 2 diabetes mellitus. *Endocr Pract* 2001;7:358–63.
- [540] Owen CG, Newsom RS, Rudnicka AR, Ellis TJ, Woodward EG. Vascular response of the bulbar conjunctiva to diabetes and elevated blood pressure. *Ophthalmology* 2005;112:1801–8.
- [541] Schuerch K, Frech H, Zinkernagel M. Conjunctival microangiopathy in diabetes mellitus assessed with optical coherence tomography angiography. *Transl Vis Sci Technol* 2020;9:10.
- [542] Owen CG, Newsom RS, Rudnicka AR, Barman SA, Woodward EG, Ellis TJ. Diabetes and the tortuosity of vessels of the bulbar conjunctiva. *Ophthalmology* 2008;115:e27–32.



- [543] Hwang J, Karanam V, Wang J, Feuer WJ, Garg RK, Tamariz L, et al. Conjunctival vessels in diabetes using functional slit lamp biomicroscopy. *Cornea* 2021;40:950–7.
- [544] He F, Zhao Z, Liu Y, Lu L, Fu Y. Assessment of ocular surface damage during the course of type 2 diabetes mellitus. *J Ophthalmol* 2018;2018:1206808.
- [545] Dogru M, Katakami C, Inoue M. Tear function and ocular surface changes in noninsulin-dependent diabetes mellitus. *Ophthalmology* 2001;108:586–92.
- [546] Mimura T, Obata H, Usui T, Mori M, Yamagami S, Funatsu H, et al. Pinguecula and diabetes mellitus. *Cornea* 2012;31:264–8.
- [547] Zhu X, Wei L, Rong X, Zhang Y, Zhang Q, Wen X, et al. Conjunctival microbiota in patients with type 2 diabetes mellitus and influences of perioperative use of topical levofloxacin in ocular surgery. *Front Med* 2021;8:605639.
- [548] Bilen H, Ates O, Astam N, Uslu H, Akcay G, Baykal O. Conjunctival flora in patients with type 1 or type 2 diabetes mellitus. *Adv Ther* 2007;24:1028–35.
- [549] Ham B, Hwang HB, Jung SH, Chang S, Kang KD, Kwon MJ. Distribution and diversity of ocular microbial communities in diabetic patients compared with healthy subjects. *Curr Eye Res* 2018;43:314–24.
- [550] Ozkan J, Willcox MD. The ocular microbiome: molecular characterisation of a unique and low microbial environment. *Curr Eye Res* 2019;44:685–94.
- [551] Ansari AS, de Lusignan S, Hinton W, Munro N, McGovern A. The association between diabetes, level of glycaemic control and eye infection: cohort database study. *Prim Care Diabetes* 2017;11:421–9.
- [552] Kruse A, Thomsen RW, Hundborg HH, Knudsen LL, Sorensen HT, Schonheyder HC. Diabetes and risk of acute infectious conjunctivitis—a population-based case-control study. *Diabet Med* 2006;23:393–7.
- [553] Yoo TK, Oh E. Diabetes mellitus is associated with dry eye syndrome: a meta-analysis. *Int Ophthalmol* 2019;39:2611–20.
- [554] Lockwood A, Hope-Ross M, Chell P. Neurotrophic keratopathy and diabetes mellitus. *Eye* 2006;20:837–9.
- [555] Lv H, Li A, Zhang X, Xu M, Qiao Y, Zhang J, et al. Meta-analysis and review on the changes of tear function and corneal sensitivity in diabetic patients. *Acta Ophthalmol* 2014;92:e96–104.
- [556] Tummanapalli SS, Issar T, Kwai N, Pisarcikova J, Poynten AM, Krishnan AV, et al. A comparative study on the diagnostic utility of corneal confocal microscopy and tear neuromediator levels in diabetic peripheral neuropathy. *Curr Eye Res* 2020;45:921–30.
- [557] Cousen P, Cackett P, Bennett H, Swa K, Dhillon B. Tear production and corneal sensitivity in diabetes. *J Diabet Complicat* 2007;21:371–3.
- [558] Kaiserman I, Kaiserman N, Nakar S, Vinker S. Herpetic eye disease in diabetic patients. *Ophthalmology* 2005;112:2184–8.
- [559] Gopinathan U, Garg P, Fernandes M, Sharma S, Athmanathan S, Rao GN. The epidemiological features and laboratory results of fungal keratitis: a 10-year review at a referral eye care center in South India. *Cornea* 2002;21:555–9.
- [560] Kaji Y, Usui T, Oshika T, Matsubara M, Yamashita H, Araie M, et al. Advanced glycation end products in diabetic corneas. *Invest Ophthalmol Vis Sci* 2000;41:362–8.
- [561] Gekka M, Miyata K, Nagai Y, Nemoto S, Sameshima T, Tanabe T, et al. Corneal epithelial barrier function in diabetic patients. *Cornea* 2004;23:35–7.
- [562] Schultz RO, Peters MA, Sobocinski K, Nassif K, Schultz KJ. Diabetic corneal neuropathy. *Trans Am Ophthalmol Soc* 1983;81:107–24.
- [563] Quadrado MJ, Popper M, Morgado AM, Murta JN, Van Best JA. Diabetes and corneal cell densities in humans by *in vivo* confocal microscopy. *Cornea* 2006;25:761–8.
- [564] Jan RL, Tai MC, Ho CH, Chu CC, Wang JJ, Tseng SH, et al. Risk of recurrent corneal erosion in patients with diabetes mellitus in Taiwan: a population-based cohort study. *BMJ Open* 2020;10:e035933.
- [565] Chang YS, Tai MC, Ho CH, Chu CC, Wang JJ, Tseng SH, et al. Risk of corneal ulcer in patients with diabetes mellitus: a retrospective large-scale cohort study. *Sci Rep* 2020;10:7388.
- [566] Wang X, Xu G, Wang W, Wang J, Chen L, He M, et al. Changes in corneal biomechanics in patients with diabetes mellitus: a systematic review and meta-analysis. *Acta Diabetol* 2020;57:973–81.
- [567] Ramm L, Herber R, Spoerl E, Pillunat LE, Terai N. Measurement of corneal biomechanical properties in diabetes mellitus using the ocular response analyzer and the corvis ST. *Cornea* 2019;38:595–9.
- [568] Pérez-Rico C, Gutiérrez-Ortiz C, González-Mesa A, Zanduetta AM, Moreno-Salgueiro A, Germain F. Effect of diabetes mellitus on C orvis ST measurement process. *Acta Ophthalmol* 2015;93:e193–8.
- [569] Hager A, Wegscheider K, Wiegand W. Changes of extracellular matrix of the cornea in diabetes mellitus. *Graefes Arch Clin Exp Ophthalmol* 2009;247:1369–74.
- [570] dell’Omo R, Cifariello F, De Turris S, Romano V, Di Renzo F, Di Taranto D, et al. Confocal microscopy of corneal nerve plexus as an early marker of eye involvement in patients with type 2 diabetes. *Diabetes Res Clin Pract* 2018;142:393–400.
- [571] Qu JH, Tian L, Zhang XY, Sun XG. Early central and peripheral corneal microstructural changes in type 2 diabetes mellitus patients identified using *in vivo* confocal microscopy: a case-control study. *Medicine (Baltim)* 2017;96:e7960.
- [572] Pritchard N, Edwards K, Vagenas D, Shahidi AM, Sampson GP, Russell AW, et al. Corneal sensitivity as an ophthalmic marker of diabetic neuropathy. *Optom Vis Sci* 2010;87:1003–8.
- [573] Tavakoli M, Kallinikos PA, Efron N, Boulton AJ, Malik RA. Corneal sensitivity is reduced and relates to the severity of neuropathy in patients with diabetes. *Diabetes Care* 2007;30:1895–7.
- [574] Gad H, Petropoulos IN, Khan A, Ponirakis G, MacDonald R, Alam U, et al. Corneal confocal microscopy for the diagnosis of diabetic peripheral neuropathy: a systematic review and meta-analysis. *J Diabetes Investig* 2022;13:134–47.
- [575] Shih KC, Lam KS, Tong L. A systematic review on the impact of diabetes mellitus on the ocular surface. *Nutr Diabetes* 2017;7:e251.
- [576] Malik RA, Kallinikos P, Abbott CA, van Schie CH, Morgan P, Efron N, et al. Corneal confocal microscopy: a non-invasive surrogate of nerve fibre damage and repair in diabetic patients. *Diabetologia* 2003;46:683–8.
- [577] Shenoy R, Khandekar R, Bialasiewicz A, Al Muniri A. Corneal endothelium in patients with diabetes mellitus: a historical cohort study. *Eur J Ophthalmol* 2009;19:369–75.
- [578] Misra SL, Goh YW, Patel DV, Riley AF, McGhee CN. Corneal microstructural changes in nerve fiber, endothelial and epithelial density after cataract surgery in patients with diabetes mellitus. *Cornea* 2015;34:177–81.
- [579] McAloon CJ, Boylan LM, Hamburg T, Stallard N, Osman F, Lim PB, et al. The changing face of cardiovascular disease 2000–2012: an analysis of the world health organisation global health estimates data. *Int J Cardiol* 2016;224:256–64.
- [580] Shekelle RB, Shryock AM, Paul O, Lepper M, Stamler J, Liu S, et al. Diet, serum cholesterol, and death from coronary heart disease. The Western Electric study. *N Engl J Med* 1981;304:65–70.
- [581] Stokes KY, Granger DN. The microcirculation: a motor for the systemic inflammatory response and large vessel disease induced by hypercholesterolaemia? *J Physiol* 2005;562:647–53.
- [582] Khansari MM, Wanek J, Felder AE, Camardo N, Shahidi M. Automated assessment of hemodynamics in the conjunctival microvasculature network. *IEEE Trans Med Imag* 2016;35:605–11.
- [583] Koutsiaris AG, Tachmitzi SV, Batis N, Kotoula MG, Karabatsas CH, Tsironi E, et al. Volume flow and wall shear stress quantification in the human conjunctival capillaries and post-capillary venules *in vivo*. *Biorheology* 2007;44:375–86.
- [584] Khansari MM, Wanek J, Tan M, Joslin CE, Kresovich JK, Camardo N, et al. Assessment of conjunctival microvascular hemodynamics in stages of diabetic microvasculopathy. *Sci Rep* 2017;7:45916.
- [585] Kord Valeshabad A, Wanek J, Mukarram F, Zekha R, Testai FD, Shahidi M. Feasibility of assessment of conjunctival microvascular hemodynamics in unilateral ischemic stroke. *Microvasc Res* 2015;100:4–8.
- [586] Brennan PF, McNeil AJ, Jing M, Awuah A, Moore JS, Mailey J, et al. Assessment of the conjunctival microcirculation for patients presenting with acute myocardial infarction compared to healthy controls. *Sci Rep* 2021;11:7660.
- [587] Gibbons GH, Dzau VJ. The emerging concept of vascular remodeling. *N Engl J Med* 1994;330:1431–8.
- [588] Levin A, Stevens PE, Bilous RW, Coresh J, De Francisco AL, De Jong PE, et al. Kidney Disease: improving Global Outcomes (KDIGO) CKD Work Group. KDIGO 2012 clinical practice guideline for the evaluation and management of chronic kidney disease. *Kidney Int Suppl* 2013;3:1–150.
- [589] Levey AS, Coresh J, Balk E, Kausz AT, Levin A, Steffes MW, et al. National Kidney Foundation practice guidelines for chronic kidney disease: evaluation, classification, and stratification. *Ann Intern Med* 2003;139:137–47.
- [590] Yee J. Diabetic kidney disease: chronic kidney disease and diabetes. *Diabetes Spectr* 2008;21:8–10.
- [591] Arnold R, Issar T, Krishnan AV, Pussell BA. Neurological complications in chronic kidney disease. *JRSM Cardiovasc Dis* 2016;5:2048004016677687.
- [592] Kaminski MR, Rasovic A, McMahon LP, Lambert KA, Erbas B, Mount PF, et al. Factors associated with foot ulceration and amputation in adults on dialysis: a cross-sectional observational study. *BMC Nephrol* 2017;18:293.
- [593] Tummanapalli SS, Issar T, Yan A, Kwai N, Poynten AM, Krishnan AV, et al. Corneal nerve fiber loss in diabetes with chronic kidney disease. *Ocul Surf* 2020;18:178–85.
- [594] Zong RR, Zhu FF, Han W, Wang YX, Wang GL, Wang YZ, et al. Tear dynamics testing and quantitative proteomics analysis in patients with chronic renal failure. *J Proteomics* 2021;248:104351.
- [595] Kal O, Ulusoy MO, Kal A, Tanriaski G, Gezairlioglu S. Evaluation of dry eye using anterior segment optical coherence tomography in patients with end-stage renal disease undergoing hemodialysis. *Ther Apher Dial* 2018;22:104–8.
- [596] Aktas S, Sagdik HM, Aktas H, Gulcan E, Tetikoglu M, Cosgun S, et al. Tear function in patients with chronic renal failure undergoing hemodialysis. *Ren Fail* 2015;37:245–8.
- [597] Jung JW, Yoon MH, Lee SW, Chin HS. Effect of hemodialysis (HD) on intraocular pressure, ocular surface, and macular change in patients with chronic renal failure. Effect of hemodialysis on the ophthalmologic findings. *Graefes Arch Clin Exp Ophthalmol* 2013;251:153–62.
- [598] Taskapili M, Serefoglu Cabuk K, Aydin R, Atalay K, Kirgiz A, Sit D, et al. The effects of hemodialysis on tear osmolality. *J Ophthalmol* 2015;2015:170361.
- [599] Sati A, Jha A, Moulick PS, Shankar S, Gupta S, Khan MA, et al. Corneal endothelial alterations in chronic renal failure. *Cornea* 2016;35:1320–5.
- [600] Evans RD, Rosner M. Ocular abnormalities associated with advanced kidney disease and hemodialysis. *Semin Dial* 2005;18:252–7.
- [601] Harris LS, Cohn K, Toyofuku H, Lonergan E, Galin MA. Conjunctival and corneal calcific deposits in uremic patients. *Am J Ophthalmol* 1971;72:130–3.
- [602] Dursun D, Demirhan B, Oto S, Aydin P. Impression cytology of the conjunctival epithelium in patients with chronic renal failure. *Br J Ophthalmol* 2000;84:1225–7.
- [603] Aktas Z, Ozdek S, Asli Dinc U, Akyurek N, Atalay V, Guz G, et al. Alterations in ocular surface and corneal thickness in relation to metabolic control in patients with chronic renal failure. *Nephrology* 2007;12:380–5.
- [604] O’Keefe SJ. Nutrition and gastrointestinal disease. *Scand J Gastroenterol Suppl* 1996;220:52–9.



- [605] Malik TF, Aurelio DM. Extraintestinal manifestations of inflammatory bowel disease. StatPearls. Treasure island (FL). StatPearls Publishing LLC.; 2022. StatPearls Publishing Copyright © 2022.
- [606] Ott C, Scholmerich J. Extraintestinal manifestations and complications in IBD. *Nat Rev Gastroenterol Hepatol* 2013;10:585–95.
- [607] Martins T, Miranda Sipahi A, Dos Santos FM, Schor P, Anschutz A, Mendes LGA, et al. Eye disorders in patients with celiac disease and inflammatory bowel disease: a study using clinical data warehouse. *Eur J Ophthalmol* 2021: 11206721211012849.
- [608] Orchard TR, Chua CN, Ahmad T, Cheng H, Welsh KI, Jewell DP. Uveitis and erythema nodosum in inflammatory bowel disease: clinical features and the role of HLA genes. *Gastroenterology* 2002;123:714–8.
- [609] Czompa L, Barta Z, Ziad H, Nemeth G, Rentka A, Aszalas Z, et al. Corneal manifestations of inflammatory bowel disease. *Semin Ophthalmol* 2019;34: 543–50.
- [610] Barta Z, Czompa L, Rentka A, Zold E, Remenyik J, Biro A, et al. Evaluation of objective signs and subjective symptoms of dry eye disease in patients with inflammatory bowel disease. *BioMed Res Int* 2019;2019:8310583.
- [611] Rostom A, Murray JA, Kagnoff MF. American Gastroenterological Association (AGA) Institute technical review on the diagnosis and management of celiac disease. *Gastroenterology* 2006;131:1981–2002.
- [612] Wiersma NJ, van Bokhorst-de van der Schueren MA, Berkenpas M, Mulder CJ, van Bodegraven AA. Vitamin and mineral deficiencies are highly prevalent in newly diagnosed celiac disease patients. *Nutrients* 2013;5:3975–92.
- [613] Donmez Gun R, Kaplan AT, Zorlutuna Kaymak N, Koroglu E, Karadag E, Simsek S. The impact of celiac disease and duration of gluten free diet on anterior and posterior ocular structures: ocular imaging based study. *Photodiagnosis Photodyn Ther* 2021;34:102214.
- [614] Karatepe Hashas AS, Altunel O, Sevinc E, Duru N, Alabay B, Torun YA. The eyes of children with celiac disease. *J AAPOS* 2017;21:48–51.
- [615] Hazar L, Oyur G, Atay K. Evaluation of ocular parameters in adult patients with celiac disease. *Curr Eye Res* 2021;46:122–6.
- [616] Tuncer S, Yeniad B, Peksayar G. Regression of conjunctival tumor during dietary treatment of celiac disease. *Indian J Ophthalmol* 2010;58:433–4.
- [617] Mearin F, Lacy BE, Chang L, Chey WD, Lembo AJ, Simren M, et al. Bowel disorders. *Gastroenterology*; 2016.
- [618] Lovell RM, Ford AC. Global prevalence of and risk factors for irritable bowel syndrome: a meta-analysis. *Clin Gastroenterol Hepatol* 2012;10:712–21. e4.
- [619] Chadwick VS, Chen W, Shu D, Paulus B, Bethwaite P, Tie A, et al. Activation of the mucosal immune system in irritable bowel syndrome. *Gastroenterology* 2002; 122:1778–83.
- [620] Moayyedi P, Quigley EM, Lacy BE, Lembo AJ, Saito YA, Schiller LR, et al. The effect of dietary intervention on irritable bowel syndrome: a systematic review. *Clin Transl Gastroenterol* 2015;6:e107.
- [621] Vehof J, Sillevs Smitt-Kamminga N, Kozareva D, Nibourg SA, Hammond CJ. Clinical characteristics of dry eye patients with chronic pain syndromes. *Am J Ophthalmol* 2016;162:59–65. e2.
- [622] Vehof J, Sillevs Smitt-Kamminga N, Nibourg SA, Hammond CJ. Predictors of discordance between symptoms and signs in dry eye disease. *Ophthalmology* 2017;124:280–6.
- [623] Asproudis I, Tsoumani AT, Katsanos KH, Katsanos AH, Theopistos V, Paschidis KA, et al. Irritable bowel syndrome might be associated with dry eye disease. *Ann Gastroenterol* 2016;29:487–91.
- [624] Barton A, Pal B, Whorwell PJ, Marshall D. Increased prevalence of sicca complex and fibromyalgia in patients with irritable bowel syndrome. *Am J Gastroenterol* 1999;94:1898–901.
- [625] Ucar IC, Esen F, Turhan SA, Oguz H, Ulasoglu HC, Aykut V. Corneal neuropathic pain in irritable bowel syndrome: clinical findings and in vivo corneal confocal microscopy. *Graefes Arch Clin Exp Ophthalmol* 2021;259:3011–7.
- [626] Galor A, Covington D, Levitt AE, McManus KT, Seiden B, Felix ER, et al. Neuropathic ocular pain due to dry eye is associated with multiple comorbid chronic pain syndromes. *J Pain* 2016;17:310–8.
- [627] Vehof J, Zavos HMS, Lachance G, Hammond CJ, Williams FMK. Shared genetic factors underlie chronic pain syndromes. *Pain* 2014;155:1562–8.
- [628] Cai X, Li X, Tang M, Liang C, Xu Y, Zhang M, et al. Dietary carbohydrate intake, glycaemic index, glycaemic load and digestive system cancers: an updated dose-response meta-analysis. *Br J Nutr* 2019;121:1081–96.
- [629] Zanini S, Marzotto M, Giovanazzo F, Bassi C, Bellavite P. Effects of dietary components on cancer of the digestive system. *Crit Rev Food Sci Nutr* 2015;55: 1870–85.
- [630] Konstantinidis L, Damato B. Intraocular metastases—A review. *Asia Pac J Ophthalmol (Phila)*. 2017;6:208–14.
- [631] Esmaeli B, Cleary KL, Ho L, Safar S, Prieto VG. Leiomyosarcoma of the esophagus metastatic to the eyelid: a clinicopathologic report. *Ophthalmic Plast Reconstr Surg* 2002;18:159–61.
- [632] Paik JH, Shin HJ, Lee HS, Han HS, Ryu CG, Hwang DY. Case report of periorbital metastasis from rectal cancer. *Medicine (Baltim)* 2020;99:e18479.
- [633] Das C, Shields CL. Radiotherapy for iris metastasis from esophageal carcinoma: a series of three cases. *Oman J Ophthalmol* 2016;9:93–6.
- [634] Ozawa H, Usui Y, Takano Y, Horiuchi N, Kuribayashi T, Kurihara T, et al. Iris metastasis as the initial presentation of metastatic esophageal cancer diagnosed by fine needle aspiration biopsy: a case report. *Medicine (Baltim)* 2021;100: e26232.
- [635] Mahmodlou R, Asadi Amoli F, Abbasi A, Seyed Mokhtari SA, Pourasghary S. Case report: scleral metastasis of esophageal squamous cell carcinoma. *Ophthalmol Ther* 2018;7:185–9.
- [636] Chen SF, Yii CY, Chou JW. Colon cancer with orbital metastasis. *Clin Gastroenterol Hepatol* 2011;9:e76–7.
- [637] Fernandez Berdasco K, Fernandez Diaz L, Jimenez-Fonseca P, Calvo Blanco J, Burgueno Montanes C. Unilateral exophthalmos secondary to esophageal adenocarcinoma metastasis to the medial rectus muscle. *Arch Soc Esp Ophthalmol* 2019;94:510–3.
- [638] Luh JY, Han ES, Simmons JR, Whitehead RP. Poorly differentiated colon carcinoma with neuroendocrine features presenting with hypercalcemia and cutaneous metastases: case report and review of the literature. *Am J Clin Oncol* 2002;25:160–3.
- [639] Makino K, Tsutsumi S, Takaki Y, Nonaka S, Okura H, Ishii H. Late orbital metastasis from colon cancer complicated by multiple tumors in the breast, lung, liver, and spine. *Radiol Case Rep* 2022;17:5–12.
- [640] Pinato DJ, Krell J, Wasan H, Sharma R. Neoplastic infiltration of the sphenoid wing: a rare manifestation of metastatic colorectal cancer. *Asia Pac J Clin Oncol* 2011;7:399–400.
- [641] Nabeel M, Farooqi R, Mohebtash M, Desai R, Mansuri U, Patel S, et al. Rectal cancer in the eye: a case report of orbital metastasis. *Cureus* 2017;9:e1589.
- [642] Pearlman M, Kwong WT. A long and distant journey: a case of rectal cancer with metastasis to the orbit. *Ann Gastroenterol* 2015;28:151–2.
- [643] Pokharel S, Kabbach G, Richter SJ, Chiu L. Metastatic esophageal cancer presenting as an orbital mass. *ACG Case Rep J* 2016;3:e154.
- [644] Protopapa MN, Lagadinou M, Papagiannis T, Gogos CA, Solomou EE. Hepatocellular carcinoma: an uncommon metastasis in the orbit. *Case Rep Oncol Med* 2020;2020:7526042.
- [645] Roche SP, Kobos R. Jaundice in the adult patient. *Am Fam Physician* 2004;69: 299–304.
- [646] Schickner DC, Yarkoni A, Langer P, Frohman L, Chen X, Folberg R, et al. Panophthalmitis due to clostridium septicum. *Am J Ophthalmol* 2004;137:942–4.
- [647] Yi QY, Li WD, Chen LS, Bai ZS. Unilateral endogenous fungal endophthalmitis after esophageal cancer surgery: a case report. *BMC Infect Dis* 2018;18:671.
- [648] Ferdousi M, Azmi S, Petropoulos IN, Fadavi H, Ponirakis G, Marshall A, et al. Corneal confocal microscopy detects small fibre neuropathy in patients with upper gastrointestinal cancer and nerve regeneration in chemotherapy induced peripheral neuropathy. *PLoS One* 2015;10:e0139394.
- [649] Evans V, Voekler C, Friedlander M, Walsh B, Willcox MD. Lacryglobin in human tears, a potential marker for cancer. *Clin Exp Ophthalmol* 2001;29:161–3.
- [650] Alkozi HA, Franco R, Pintor JJ. Epigenetics in the eye: an overview of the most relevant ocular diseases. *Front Genet* 2017;8:144.
- [651] Park LK, Friso S, Choi SW. Nutritional influences on epigenetics and age-related disease. *Proc Nutr Soc* 2012;71:75–83.
- [652] Koklesova L, Mazurakova A, Samec M, Biringir K, Samuel SM, Busselberg D, et al. Homocysteine metabolism as the target for predictive medical approach, disease prevention, prognosis, and treatments tailored to the person. *EPMA J* 2021;12: 477–505.
- [653] Busanello A, Santucci D, Bonini S, Micera A. Review: environmental impact on ocular surface disorders: possible epigenetic mechanism modulation and potential biomarkers. *Ocul Surf* 2017;15:680–7.
- [654] Li W, Liu J, Galvin JA. Focus: epigenetics: epigenetics and common ophthalmic diseases. *Yale J Biol Med* 2016;89:597.
- [655] Zhang C, Hu J, Yu Y. CircRNA is a rising star in researches of ocular diseases. *Front Cell Dev Biol* 2020;8:850.
- [656] Bussan KA, Robertson DM. Contact lens wear and the diabetic corneal epithelium: a happy or disastrous marriage? *J Diabet Complicat* 2019;33:75–83.
- [657] Ren X, Chou Y, Jiang X, Hao R, Wang Y, Chen Y, et al. Effects of oral vitamin B1 and mecobalamin on dry eye disease. *J Ophthalmol* 2020;2020:9539674.
- [658] Azmi S, Alam U, Ferdousi M, Ponirakis G, Petropoulos IN, Schofield J, et al. Bariatric surgery improves neuropathic symptoms, deficits, and corneal nerve morphology in obese patients with diabetes. *Diabetes* 2017;66: A550-A.
- [659] Gilbert JM, Weiss JS, Sattler AL, Koch JM. Ocular manifestations and impression cytology of anorexia nervosa. *Ophthalmology* 1990;97:1001–7.
- [660] Nucci D, Santangelo OE, Nardi M, Provenzano S, Gianfredi V. Wikipedia, google trends and diet: assessment of temporal trends in the internet users' searches in Italy before and during COVID-19 pandemic. *Nutrients* 2021;13.
- [661] Moher D, Liberati A, Tetzlaff J, Altman DG, Group P. Preferred reporting items for systematic reviews and meta-analyses: the PRISMA statement. *PLoS Med* 2009;6: e1000097.
- [662] Covidence. Covidence systematic review software. Melbourne, Australia: Veritas health innovation; 2019.
- [663] Manager Review. Version 5.4, the Cochrane collaboration. Denmark: The Nordic Cochrane Centre Copenhagen; 2020.
- [664] Sterne JA, Hernan MA, Reeves BC, Savovic J, Berkman ND, Viswanathan M, et al. ROBINS-I: a tool for assessing risk of bias in non-randomised studies of interventions. *BMJ* 2016;355:i4919.
- [665] Wells GA, Shea B, O'Connell D, Peterson J, Welch V, Losos M, et al. The Newcastle-Ottawa Scale (NOS) for assessing the quality of nonrandomised studies in meta-analyses. 2000. Oxford.
- [666] National Heart Lung, Blood Institute. Study quality assessment tools. 2013.
- [667] Higgins JP, Li T, Deeks JJ. Choosing effect measures and computing estimates of effect. *Cochrane handbook for systematic reviews of interventions* 2019:143–76.
- [668] Deeks JJ, Higgins JP, Altman DG, Group CSM. Analysing data and undertaking meta-analyses. *Cochrane handbook for systematic reviews of interventions* 2019: 241–84.
- [669] Adam S, Azmi S, Ho JH, Liu Y, Ferdousi M, Siahmansur T, et al. Improvements in diabetic neuropathy and nephropathy after bariatric surgery: a prospective cohort study. *Obes Surg* 2021;31:554–63.

- [670] Azmi S, Ferdousi M, Liu Y, Adam S, Iqbal Z, Dhage S, et al. Bariatric surgery leads to an improvement in small nerve fibre damage in subjects with obesity. *Int J Obes* 2021;45:631–8.
- [671] Barbato G, Fichelle M, Senatore I, Casiello M, Muscettola G. Increased dopaminergic activity in restricting-type anorexia nervosa. *Psychiatr Res* 2006;142:253–5.
- [672] Baser G, Cengiz H, Uyar M, Seker Un E. Diurnal alterations of refraction, anterior segment biometrics, and intraocular pressure in long-time dehydration due to religious fasting. *Semin Ophthalmol* 2016;31:499–504.
- [673] Beyoglu A, Karakucuk Y, Comez A. Evaluation of the effect of fasting on intraocular pressure, anterior segment parameters and density of crystalline lens and cornea. *Int Ophthalmol* 2020;40:2987–94.
- [674] Frank GKW, Kalina C, DeGuzman MC, Shott ME. Eye blink and reward prediction error response in anorexia nervosa. *Int J Eat Disord* 2020;53:1544–9.
- [675] Hills OW, Liebert E, Steinberg DL, Horwitt MK. Clinical aspects of dietary depletion of riboflavin. *AMA Arch Intern Med* 1951;87:682–93.
- [676] Kerimoglu H, Ozturk B, Gunduz K, Bozkurt B, Kamis U, Okka M. Effect of altered eating habits and periods during Ramadan fasting on intraocular pressure, tear secretion, corneal and anterior chamber parameters. *Eye* 2010;24:97–100.
- [677] Nilfroushan N, Abolfathzadeh N, Banifatemi M, Miraftebi A, Sardarina M, Alemzadeh SA, et al. Effects of fasting on peripapillary capillary density, peripapillary nerve fiber layer, intraocular pressure and central corneal thickness. *Int Ophthalmol* 2020;40:1439–47.
- [678] Nowroozzadeh MH, Mirhosseini A, Meshkibaf MH, Roshannejad J. Effect of Ramadan fasting in tropical summer months on ocular refractive and biometric characteristics. *Clin Exp Optom* 2012;95:173–6.
- [679] Oltulu R, Satirtav G, Ersan I, Soylu E, Okka M, Zengin N. The effect of dehydration and fasting on corneal biomechanical properties and intraocular pressure. *Eye Contact Lens* 2016;42:392–4.
- [680] Rocha EM, Cunha DA, Carneiro EM, Boschero AC, Saad MJ, Velloso LA. Identification of insulin in the tear film and insulin receptor and IGF-1 receptor on the human ocular surface. *Invest Ophthalmol Vis Sci* 2002;43:963–7.
- [681] Sarici AM, Yuksel Elgin C, Dikkaya F. Effect of fasting on corneal biomechanical and structural parameters. *Curr Eye Res* 2016;41:908–12.
- [682] Selver OB, Palamar M, Gerceker K, Egrilmez S, Yagci A. The effects of ramadan fasting on anterior segment parameters, visual acuity and intraocular pressures of the eye. *Open Ophthalmol J* 2017;11:152–5.
- [683] Uysal BS, Duru N, Ozen U, Arikan Yorgun M, Akcay E, Caglayan M, et al. Impact of dehydration and fasting on intraocular pressure and corneal biomechanics measured by the Ocular Response Analyzer. *Int Ophthalmol* 2018;38:451–7.
- [684] Merlin T, Weston A, Tooher R. Extending an evidence hierarchy to include topics other than treatment: revising the Australian 'levels of evidence. *BMC Med Res Methodol* 2009;9:34.
- [685] Karanicolos PJ, Farrokhyar F, Bhandari M. Practical tips for surgical research: blinding: who, what, when, why, how? *Can J Surg* 2010;53:345–8.